Computed Tomography Brain Tumors

- Prepared By: Ahmed Jasem Abass MSC Medical Imaging





ANATOMY

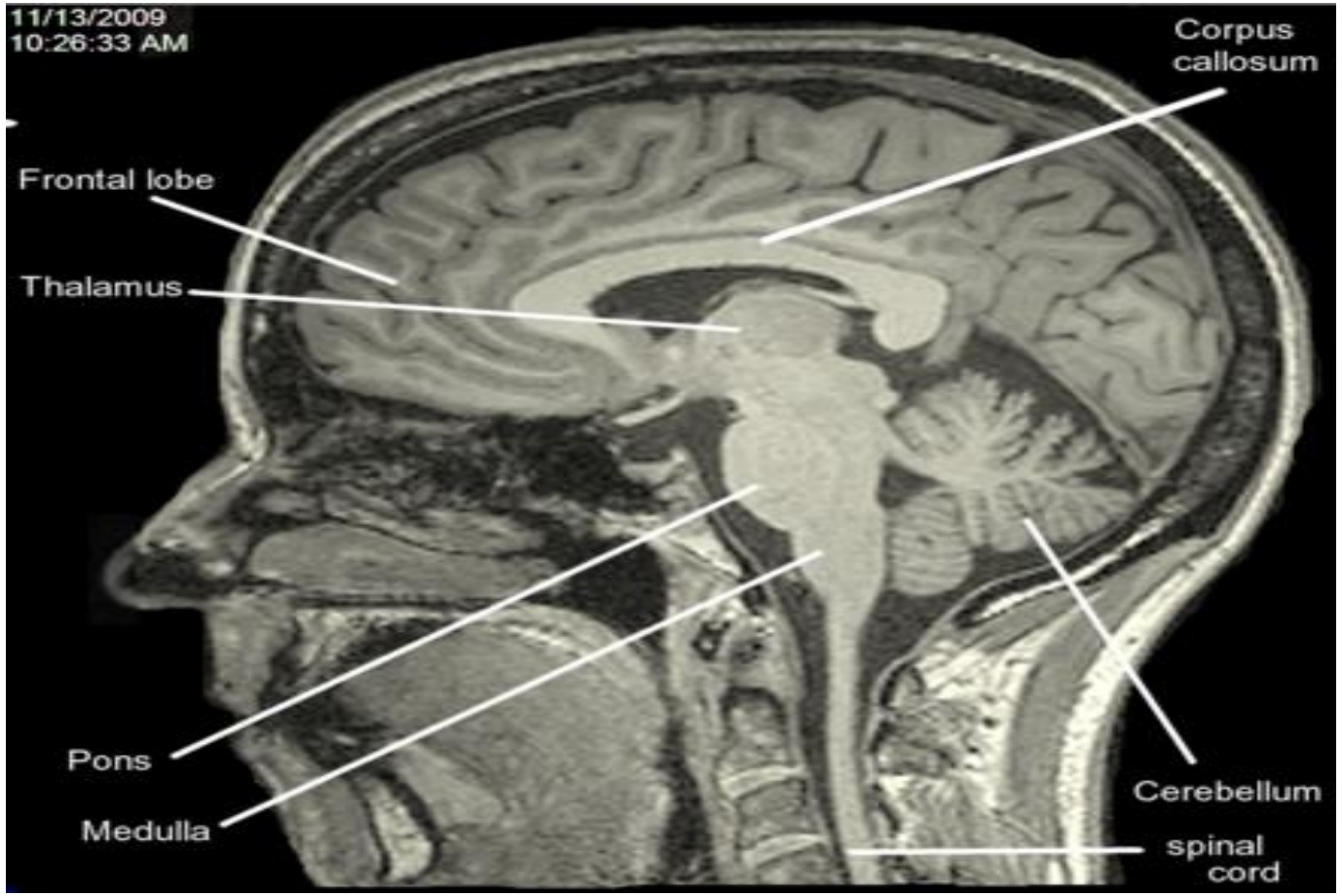
11/13/2009
10:26:33 AM
Corpus callosum
Frontal lobe
Thalamus
Pons
Medulla
Cerebellum
spinal cord

Brain Tumors

- A brain tumor is a collection of abnormal cells that grows in or around the brain. Tumors can directly destroy healthy brain cells by invading them. They can also indirectly damage healthy cells by crowding other parts of the brain and causing inflammation, brain swelling and pressure within the skull.

- Brain tumors are either malignant or benign. A malignant tumor, also called brain cancer, usually grows rapidly and often invades or crowds healthy areas of the brain. These tumors also steal the blood supply of a normal brain. Benign brain tumors do not contain cancer cells and are usually slow growing.

Brain tumor symptoms may include:

- Headaches
- Nausea
- Vomiting
- Seizures
- Behavior changes
- Memory loss
- Vision or hearing problems

Brain Tumors

- In many cases, a brain tumor diagnosis begins with a neurological examination followed by a magnetic resonance imaging (MRI) scan of the head. Because an MRI produces high-quality images of soft tissues and blood vessels, it can be useful for diagnosing a brain tumor. However, a CT scan can provide more detailed images of the bone structures near a brain tumor, such as the skull or spine. A CT scan may also be used to diagnose a brain tumor if the patient has a pacemaker and cannot have an MRI, which involves the use of powerful magnetic fields that can interfere with a pacemaker's function.

Meningioma

- is the most common primary brain tumor, accounting for more than 30% of all brain tumors. Meningiomas originate in the meninges, the outer three layers of tissue that cover and protect the brain just under the skull. Women are diagnosed with meningiomas more often than men. About 85% of meningiomas are noncancerous, slow-growing tumors. Almost all meningiomas are considered benign, but some meningiomas can be persistent and come back after treatment.

Meningioma

- Depending on where the meningiomas are located, they are classified as one of the following:

1) posterior fossa meningiomas .
2) convexity meningiomas skull .
3) base meningiomas.

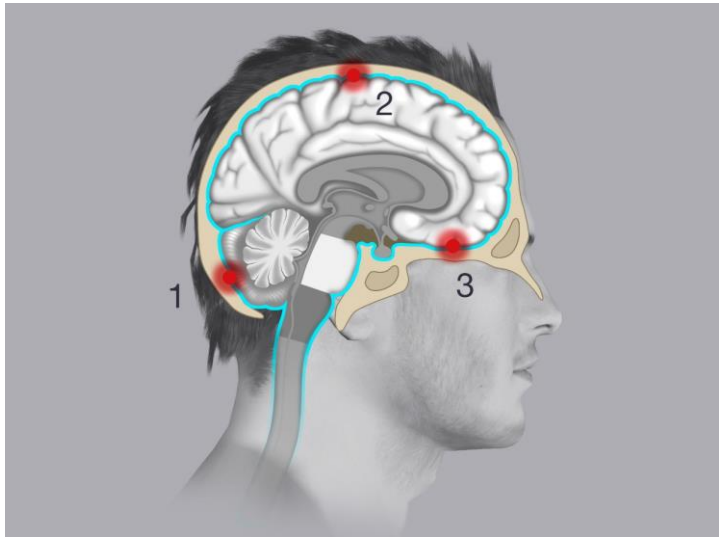

Meningioma

- The picture shows a convexity meningioma: the tumor arises from the meninges that cover the brain
- A radiological diagnosis of meningioma can be obtained by means of contrast-enhanced brain CT and MRI. These tests make it possible to identify the morphological characteristics of the lesions, which appear as rounded shapes with a regular outline.

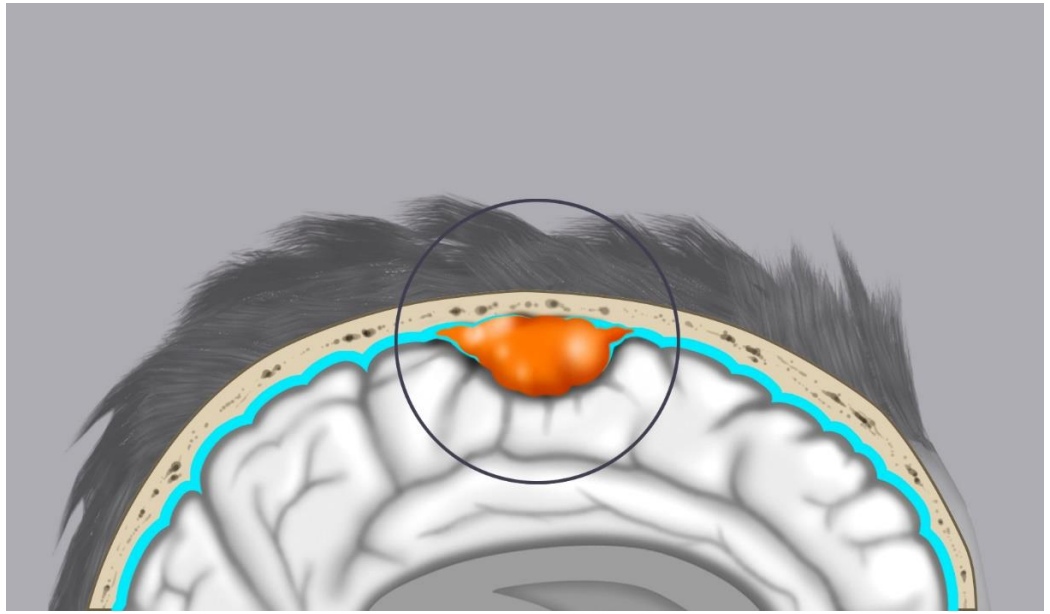

Meningioma

- CT is often the first modality employed to investigate neurological signs or symptoms, and often is the modality which detects an incidental lesion:
- non-contrast CT
- 60% slightly hyperdense to normal brain, the rest are more isodense
- 20-30% have some calcification
- >50% demonstrate variable adjacent edema
- post-contrast CT
- 72% brightly and homogeneously contrast enhance
- malignant or cystic variants demonstrate more heterogeneity/less intense enhancement

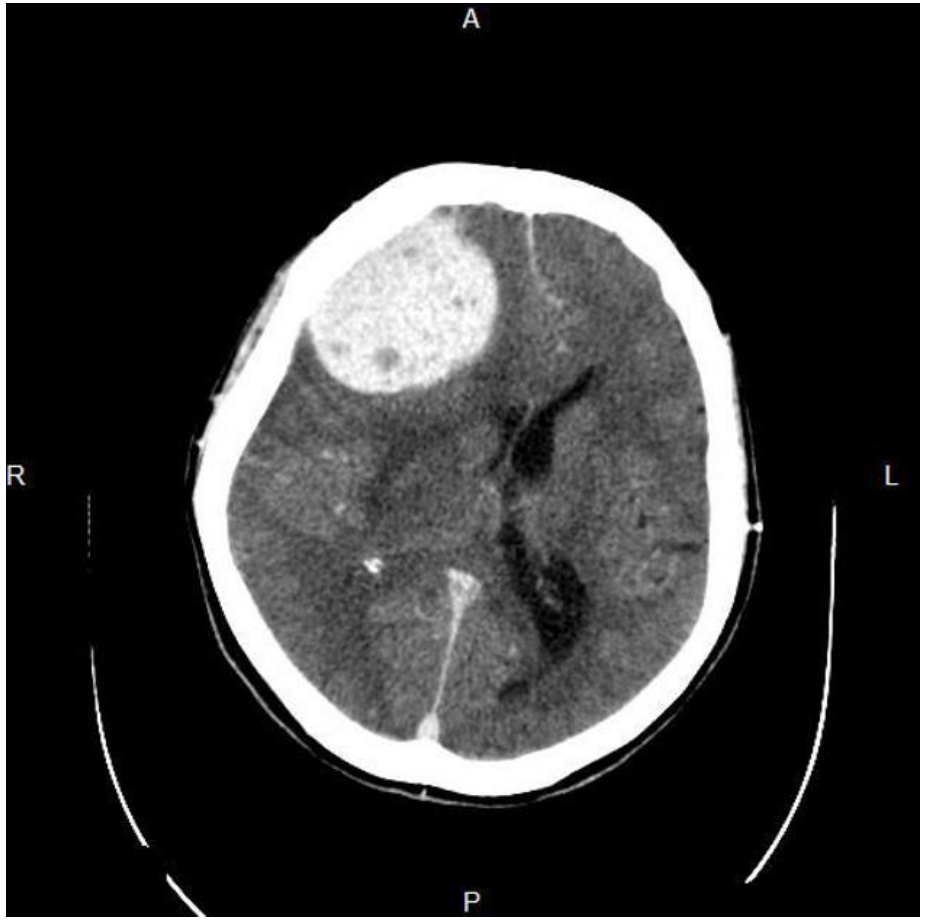

Pituitary Adenoma(Benign)

- Adenoma, a type of tumor that grows in the gland tissues, is the most common type of pituitary tumor. Pituitary adenomas develop from the pituitary gland and tend to grow at a slow rate. About 10% of primary brain tumors are diagnosed as adenomas. They can cause vision and endocrinological problems. Fortunately for patients affected by them, adenomas are benign and treatable with surgery and/or medication.

Radiographic features

- Pituitary macroadenomas are by definition >10 mm diameter masses arising from the pituitary gland, and usually extending superiorly into the suprasellar cistern where it can compress the chiasm. Bilateral indentation by the diaphragma sellae as the tumor passes superiorly can give a snowman or figure-eight configuration 10.

- Because these tumors are typically slow-growing, the pituitary fossa is almost invariably enlarged with thinned remodeled bone.
- CT
- Non-contrast attenuation can vary depending on hemorrhagic, cystic, and necrotic components. Solid adenomas without hemorrhage, typically have attenuation similar to the brain (30-40 HU) and demonstrate moderate contrast enhancement; less marked than one typically sees in meningiomas. Calcification is rare.



CT WITH CONTRAST

Schwannoma

- Acoustic neuromas (vestibular schwannomas) are benign, slow-growing tumors of the nerve that connects the ear to the brain. Less than 8% of primary brain tumors are acoustic neuromas. They usually develop in middle-aged adults, grow on the nerve sheath — the covering surrounding the nerve fibers — and often cause hearing loss. Schwannomas can also affect the trigeminal nerve. These are called trigeminal schwannomas, which are much less common than vestibular schwannomas and can cause facial pain.

Radiographic features

- General imaging features of schwannomas include:
- well-circumscribed masses which displace adjacent structures without direct invasion
- cystic and fatty degeneration is common
- the larger a schwannoma, the more likely it is to show heterogeneity because of cystic degeneration or hemorrhage
- hemorrhage occurs in 5% of cases
- calcification is rare

- CT is not as sensitive or specific for the diagnosis of schwannoma as MRI but is often the first investigation obtained. It is particularly useful in assessing bony changes adjacent to the tumor.
- Imaging features include:
- low to intermediate attenuation
- intense contrast enhancement
- small tumors typically demonstrate homogeneous enhancement
- larger tumors may show heterogeneous enhancement
- adjacent bone remodeling with smooth corticated edges

Choroid Plexus Tumor

- Choroid plexus tumors are rare tumors that are found in the choroid plexus — the part of the brain within its ventricles that produces cerebrospinal fluid. About 90% of these tumors are benign. They most frequently occur in children under the age of 2 and can cause hydrocephalus, a buildup of cerebrospinal fluid, as they grow. This can result in increased pressure on the brain and enlargement of the skull. A rare malignant type of choroid plexus tumor is the choroid plexus carcinoma.

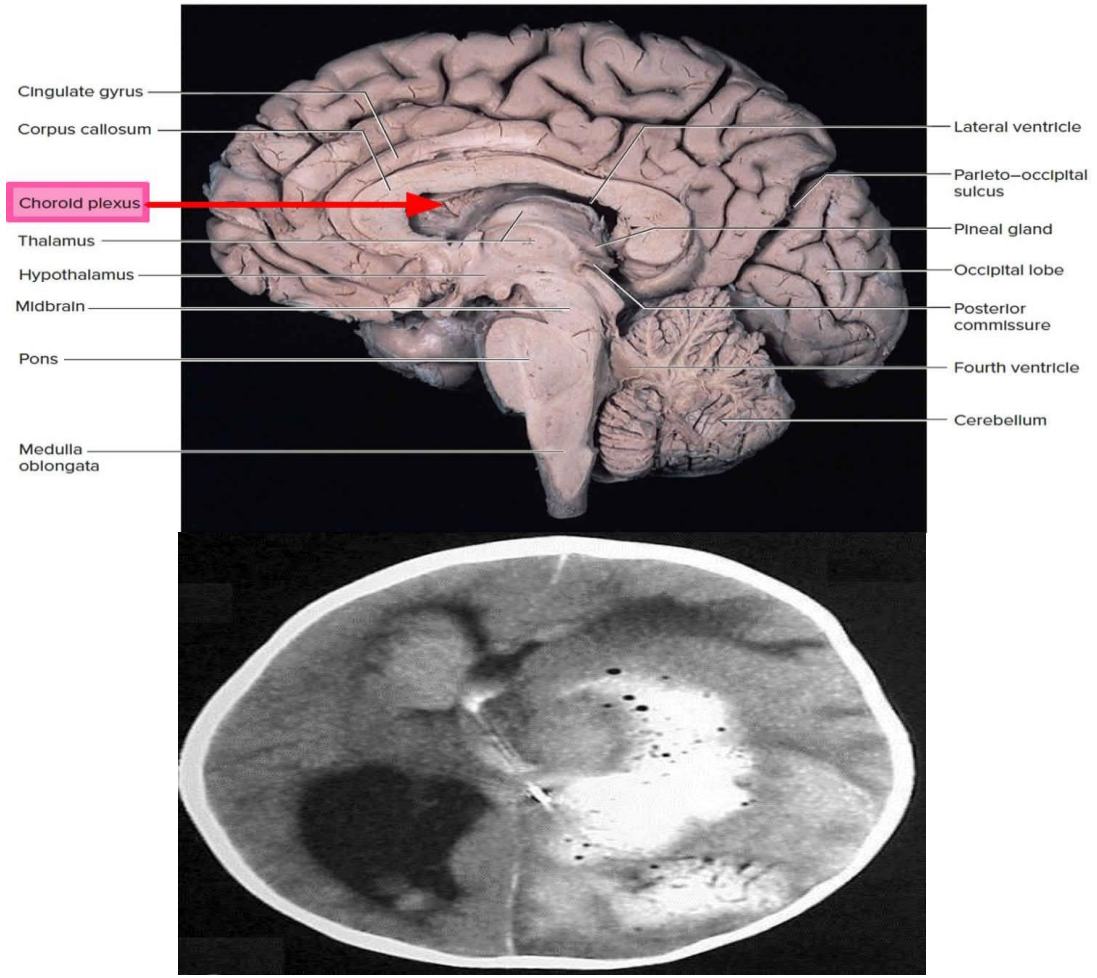

Dermoid or Epidermoid Cyst

Dermoid and epidermoid cysts are slow-growing masses that form from leftover skin tissue in embryonal development. They are treated with surgery, and follow-up procedures can be done safely if complete extirpation is not possible during the first surgery.

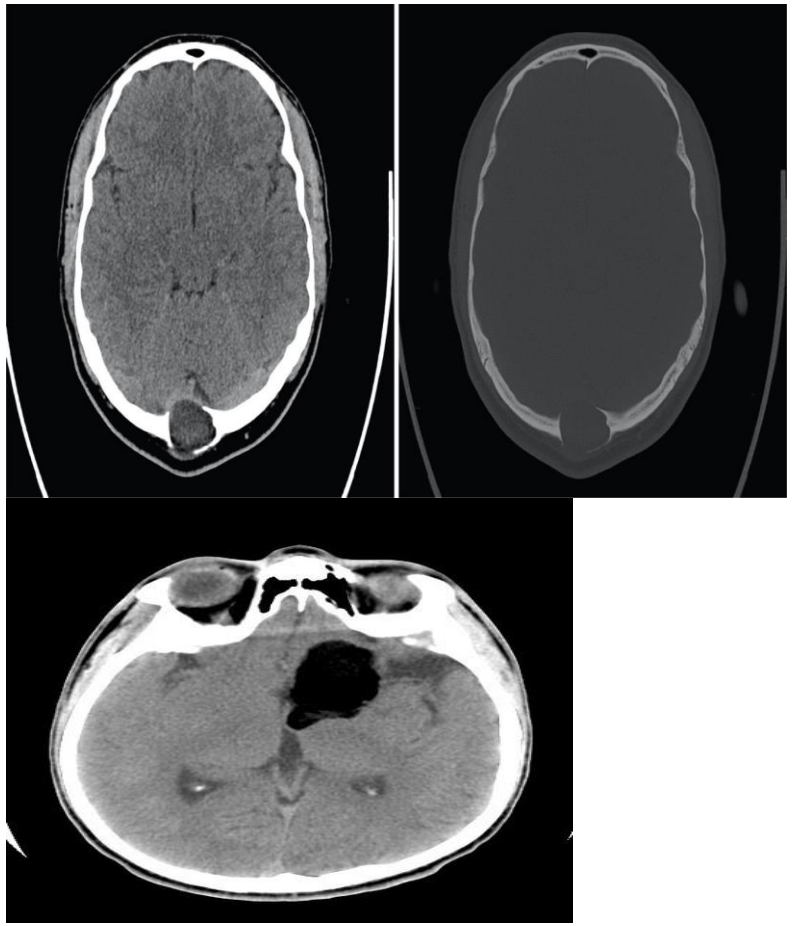

Chondrosarcoma

- Chondrosarcoma is a malignant bone cancer that mainly affects cartilage. Chondrosarcoma usually develops in patients between the age of 50 and 70. The tumor can begin in cells in the thighbone, arm, pelvis, knee and spine. It may also start in the face bones or skull base. Some of these cancers can be aggressive.



Figure 3. **(a)** Sagittal reformatted CT scan reveals bone sequestra at the distal end of a lytic clival lesion (arrows). **(b)** Axial CT scan of the skull base demonstrates the lesion with a clival origin and extension to the prepontine cistern with typical trabecular entrapment (arrow). Dystrophic calcification is also seen (arrowhead).

Radiographic features

- MRI and CT scan have complementary roles in tumor evaluation. CT evaluation is needed to assess the degree of bone involvement and to detect patterns of calcification within the lesion. MRI provides excellent anatomical delineation of adjacent structures and is able to characterize the signal of the lesion usually allowing for a confident preoperative diagnosis. MRI is, however, limited in its ability to evaluate calcification and the precise involvement of skull base osteolysis less well than CT, especially for skull base foramina.

CT

- centrally located ,well-circumscribed ,destructive lytic lesion, sometimes with marginal sclerosis ,expansile soft-tissue mass
- usually hyper-attenuating relative to adjacent brain; however, inhomogenous areas may be seen due to necrosis or hemorrhage
- soft-tissue mass is often disproportionately large relative to the bony destruction
- irregular intratumoral calcifications (thought to represent sequestra of normal bone rather than dystrophic calcifications)
- moderate to marked enhancement

Osteoma

- Osteomas are benign bone tumors (new bone growth) that usually develop on the skull base and facial bones. In general, these slow-growing tumors cause no symptoms. However, if large osteomas grow in certain areas of the brain, they may cause problems with breathing, vision or hearing.
- CT
- Osteomas appearing ivory-like as round, very radiodense lesions, similar to the normal cortex 5. Mature osteomas may demonstrate central marrow

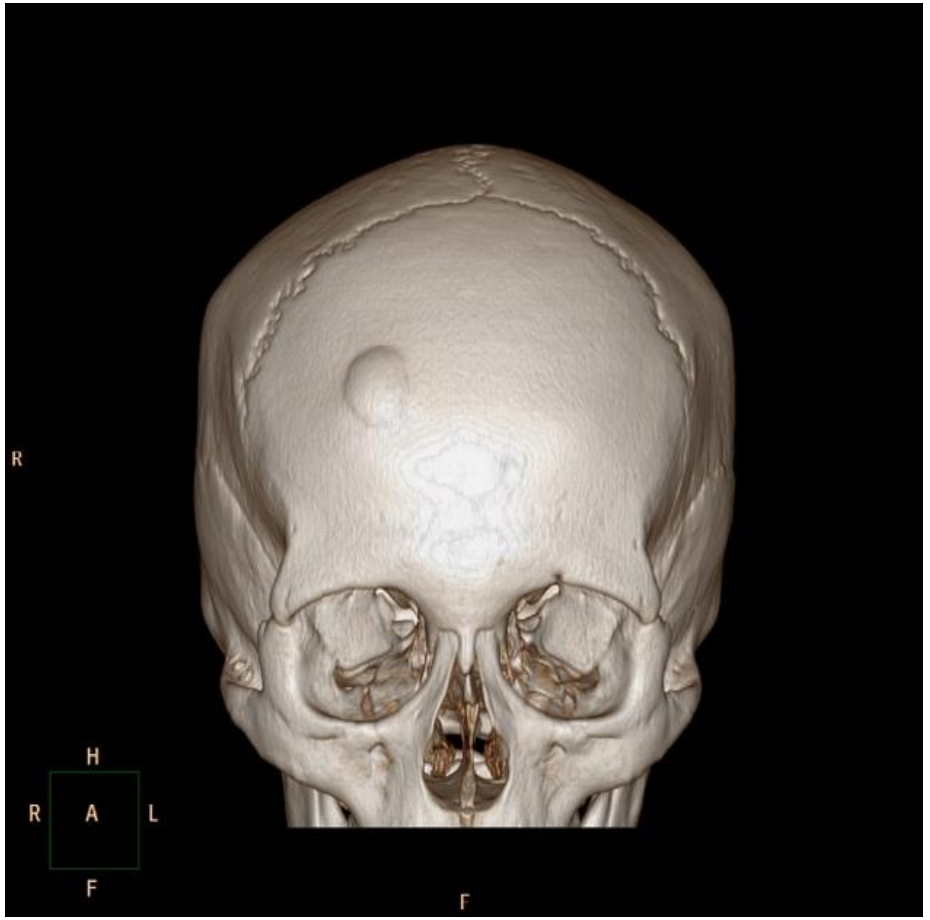

A glioma

- is a type of malignant tumor that starts in the brain or spine. Gliomas make up 80% of all malignant brain tumors. A glioma is a type of tumor that starts in the glial cells of the brain or the spine. Gliomas comprise about 30 percent of all brain tumors and central nervous system tumours, and 80 percent of all malignant brain tumours. Symptoms of gliomas depend on which part of the central nervous system is affected.

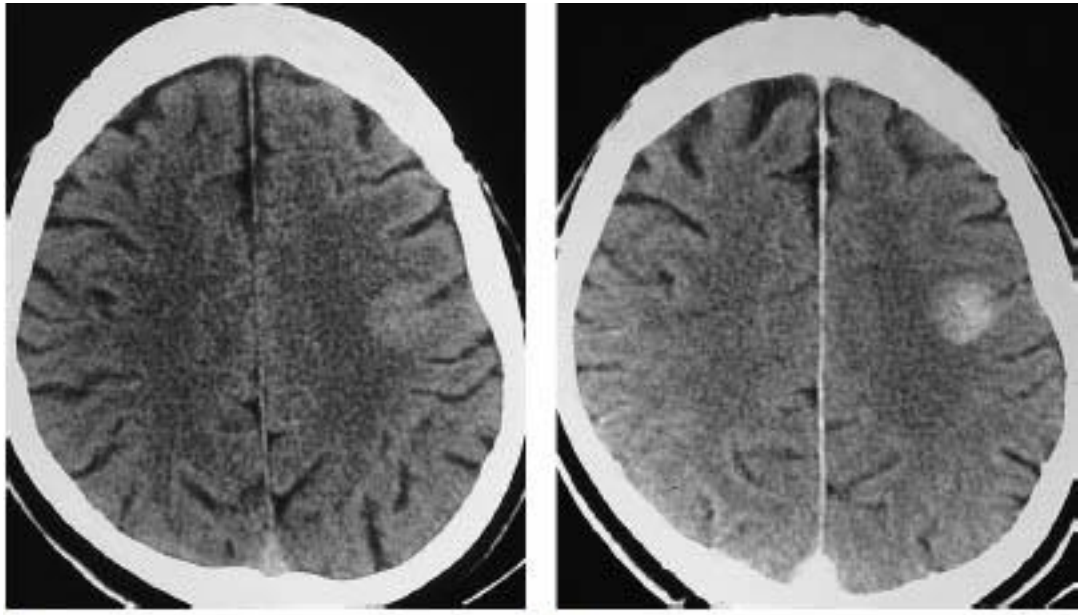

Lymphoma

- Lymphoma is a type of tumor that forms in part of the body's immune system, the lymphatic system. Lymphomas can spread from other body parts to the brain or form in the brain (primary central nervous system lymphomas).
- CT
- most primary CNS lymphomas are hyperattenuating (70%)
- show enhancement.
- hemorrhage is distinctly uncommon .
- often multiple lesions in patients with HIV/AIDS

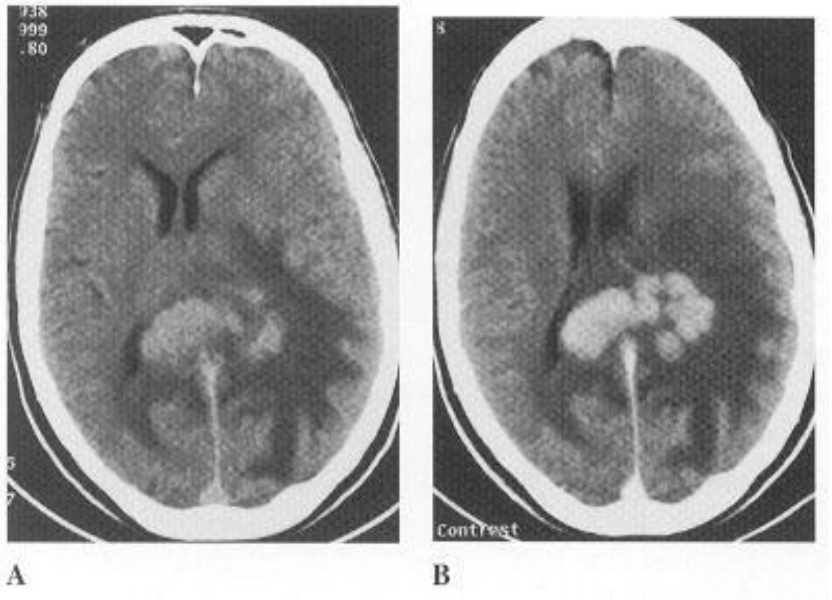

Primary cerebral lymphoma; CT before (A) and after intravenous contrast medium (B). An irregular mass which is hyperdense to grey matter, expands the splenium of the corpus callosum and extends into the left hemisphere. It is surrounded by extensive white matter oedema and enhances avidly with contrast.

Pineal tumors

- . Pineal tumors start in and around the brain's pineal gland. The pineal gland is located in the center of the brain. It makes a hormone called melatonin that helps with sleep. Pineal tumors can be benign or malignant. Pineoblastoma is a malignant type of pineal tumor that's most common in children.

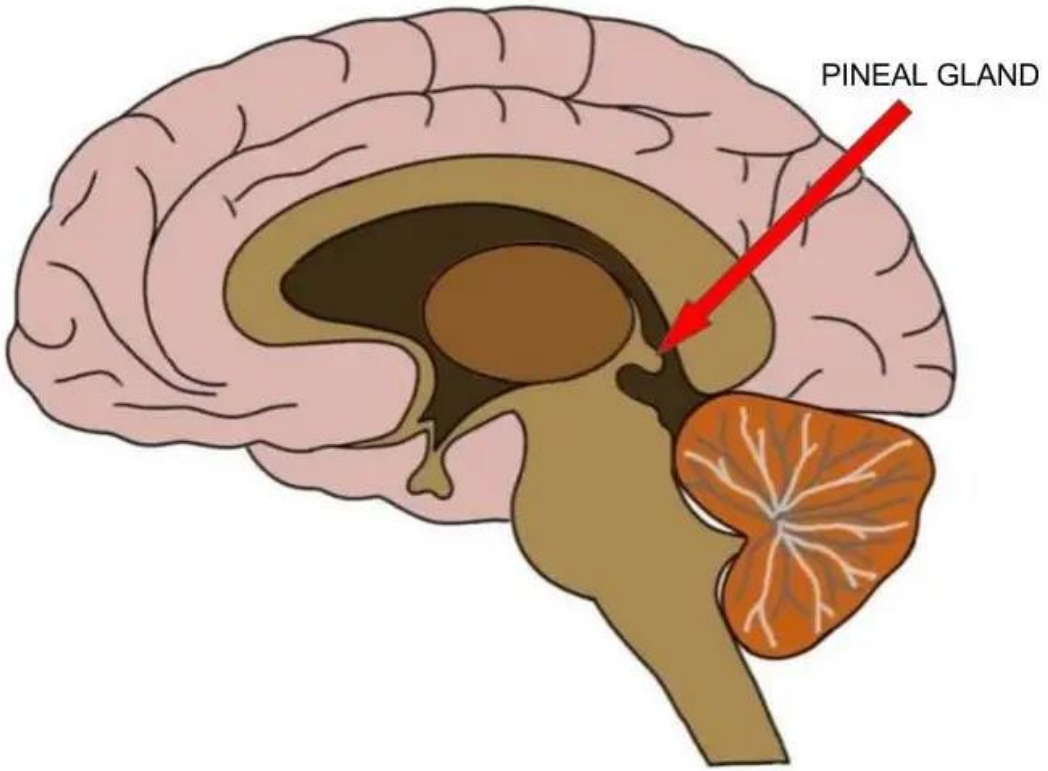

Pineal tumors

CT demonstrates the mass to be of intermediate density, similar to the adjacent brain. Pineal calcifications tend to be dispersed peripherally. This is the same pattern seen in other pineal parenchymal tumors, which is helpful in distinguishing these tumors from pineal germinomas that tend to engulf pineal calcification.



CT contrast brain: Diffuse enlargement of pineal tumour secondary to large intraparenchymal haemorrhage with intraventricular extension and acute hydrocephalus.

Merci



