Computed Tomography

- Prepared By: Ahmed Jasem Abass MSC Medical Imaging





Hydrocephalus

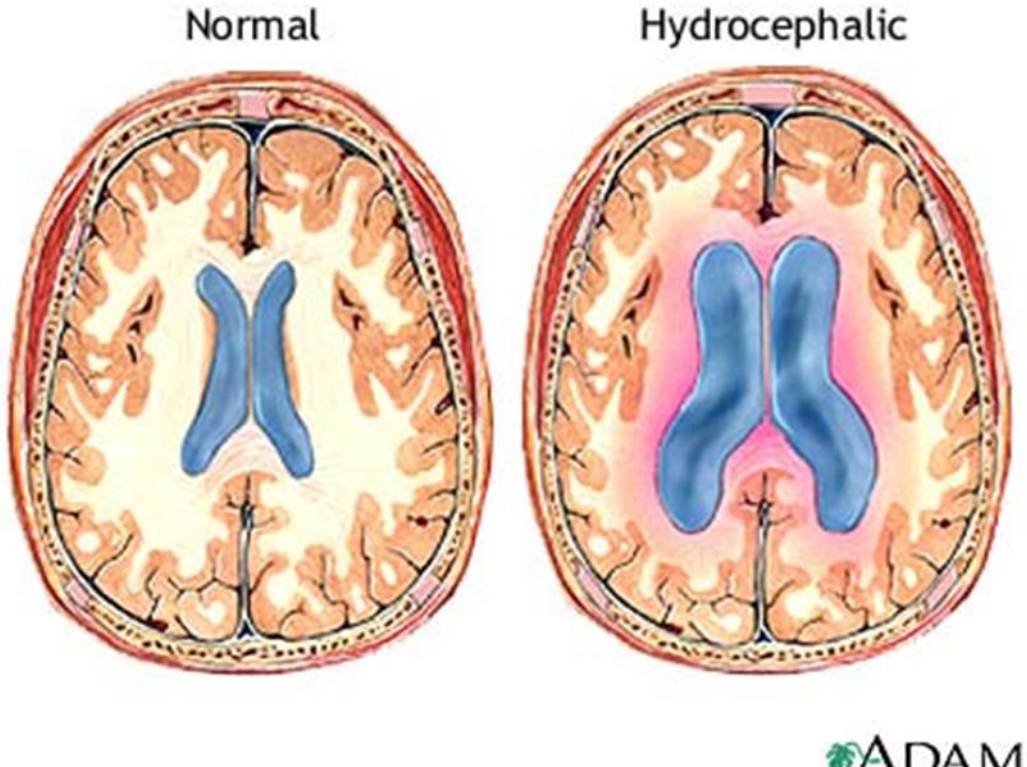

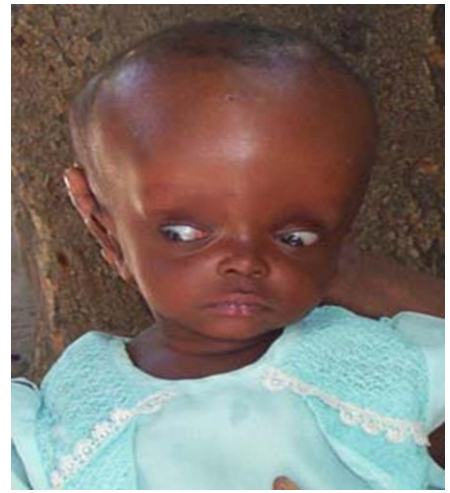

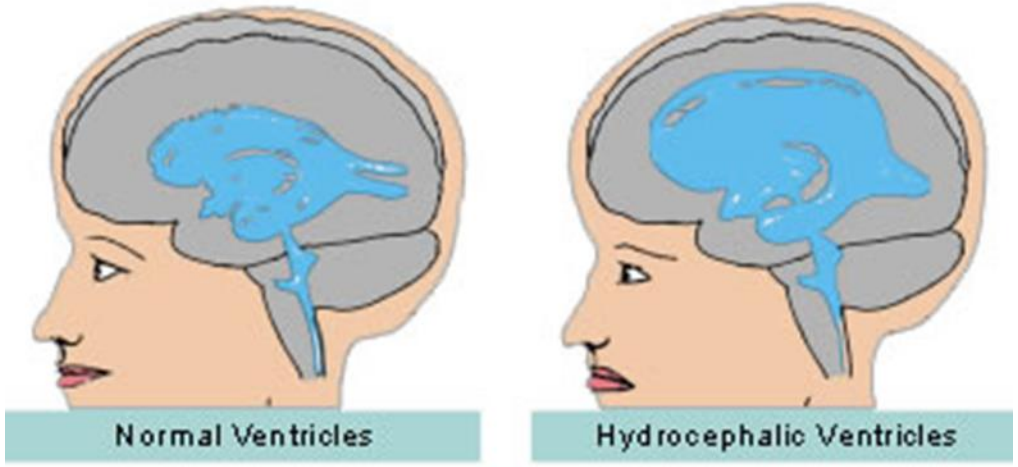

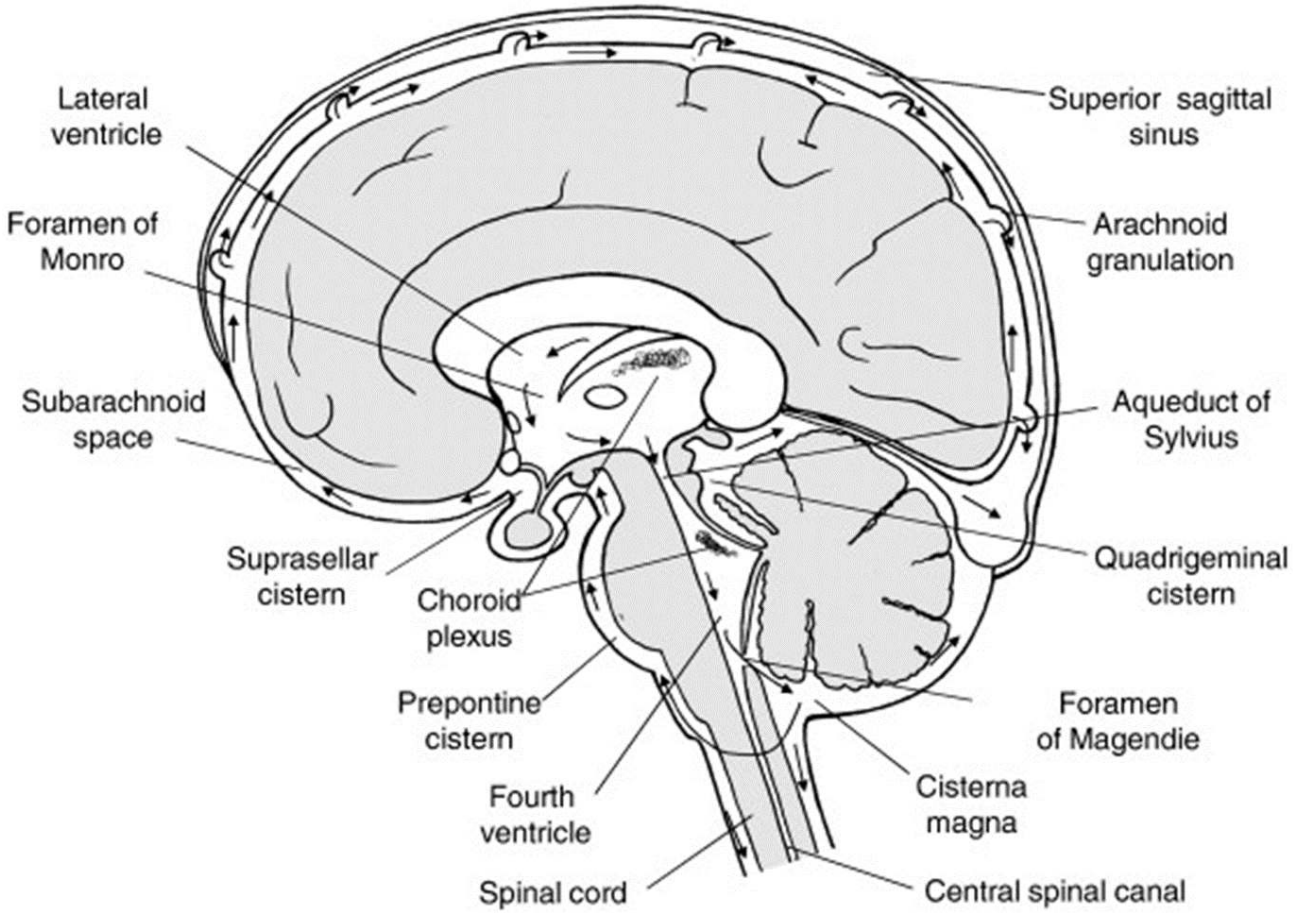
Lateral ventricle
Foramen of Monro
Subarachnoid space
Suprasellar cistern
Choroid plexus
Prepontine cistern
Fourth ventricle
Spinal cord
Superior sagittal sinus
Arachnoid granulation
Aqueduct of Sylvius
Quadrigeminal cistern
Foramen of Magendie
Cisterna magna
Central spinal canal

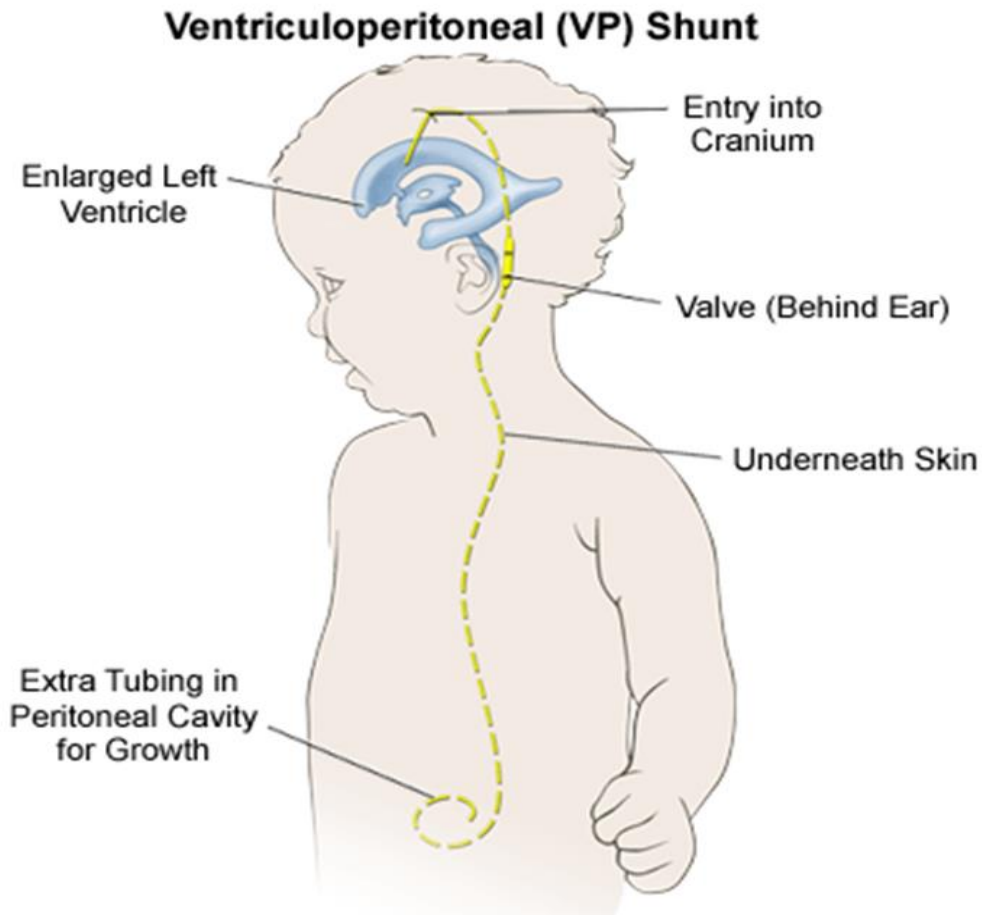
Ventriculoperitoneal (VP) Shunt
Entry into Cranium
Enlarged Left Ventricle
Valve (Behind Ear)
Underneath Skin
Extra Tubing in Peritoneal Cavity for Growth

The function of the CSF

- The CSF acts as a “water jacket” for the brain and spinal cord
- The 1300 g adult brain weighs approximately 45 g when suspended in CSF
- The CSF acts like a “sink”, effectively flushing waste products as new fluid is secreted reabsorbed
- A constant CSF electrolyte composition helps maintain a stable medium for excitable cells (neurons)



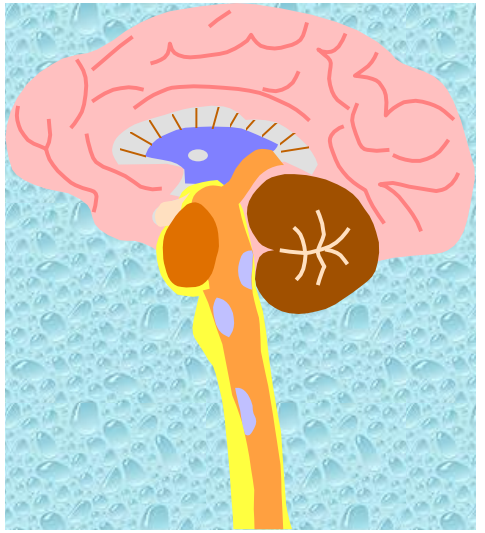

Hydrocephalus

- From Greek hydrokephalos, from hydr- + kephalE head

- CSF is produced in the choroid plexus and absorbed into the venous system via the arachnoid granulations
- Hydrocephalus results from an excess of CSF, due to an imbalance in CSF production and absorption, resulting in increased intra-ventricular pressure
- Classification:
- Communicating (non-obstructive) : blockage of CSF flow beyond the outlet of the 4th ventricle
- Non-communicating (obstructive) : blockage of CSF flow within the ventricular system, with dilatation proximal to the obstruction

Communicating Hydrocephalus

- Blockage of CSF flow over the cerebral convexities/absorption at the arachnoid granulations secondary to:
- SAH, meningeal mets, granulomatous meningitis

- Rapid CSF production
- eg. choroid plexus papilloma

- Radiological features:
- Symmetrical enlargement of the lateral, third and fourth ventricles
- Normal/effaced cerebral sulci
- Dilatation of subarachnoid cisterns
- Periventricular low attenuation transependymal flow of CSF

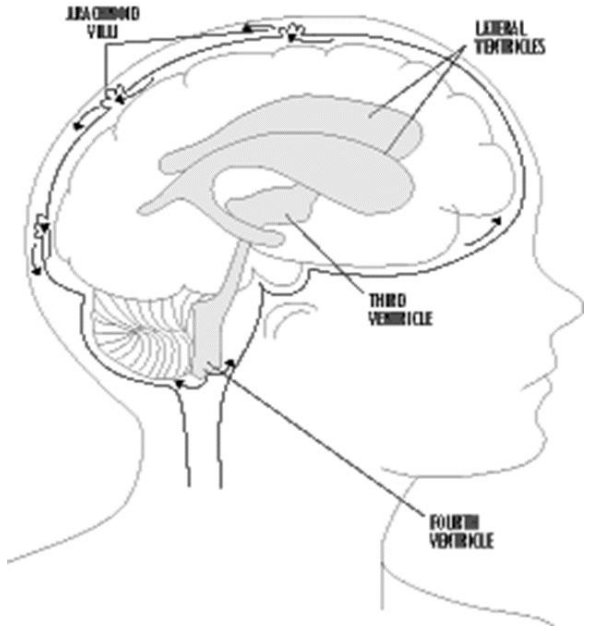

Non-communicating Hydrocephalus

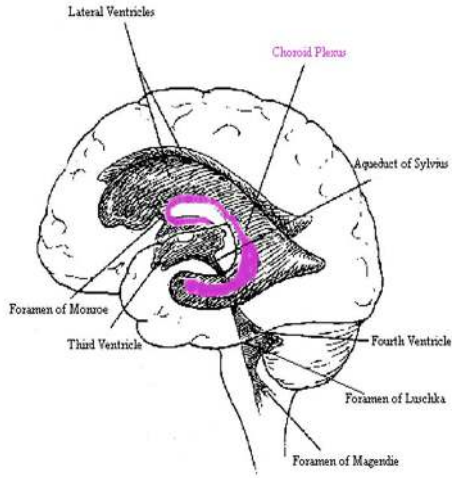

- Location of obstruction/causes:
- Lateral ventricles : ependymoma, meningioma
- Foramen of Monro : third ventricular colloid cyst
- Aqueduct of Sylvius : congenital aqueductal stenosis, IVH
- Fourth ventricle/foramen of Luschka and Magendie :congenital, tumour, extrinsic compression

- Radiological features:
- Ventricular dilatation proximal to the level of obstruction
- Earliest indication may be dilatation of the temporal horns
- Progressive enlargement of the ventricular system which is disproportionate to narrowed and effaced cortical sulci
- Periventricular low attenuation (transependymal CSF flow)

Hydrocephalus





Abscesses

- Etiology:
- Extension from adjacent sinonasal infection, mastoiditis, OM
- Generalized septicemia
- Penetrating trauma or surgery

- Radiological features:
- Location : supratentorial:infratentorial = 2:1; typically at the corticomedullary junction in the frontal and temporal lobes
- NECT : low density lesion with associated mass effect; +/- gas
- CECT : “ring-enhancement”, with central necrosis and surrounding edema (lesions <5mm enhance homogeneously)
- NB – Complication = ventriculitis (extension to ventricular system)

Abscesses





Meningitis

- Inflammation of the meninges

- Anatomic classification:
- Pachymeningitis : inflammation of the dura
- Leptomeningitis : inflammation of the arachnoid membran and subarachnoid space (more common)

- Meningoencephalitis : involvement of meninges and parenchyma

- Risk factures : concurrent infections eg. sinusitis, mastoiditis, otitis media

Meningitis – Radiologic Features

- Unenhanced CT often NORMAL

- Enhanced CT:
- Meningeal enhancement
- Meningeal thickening (TB, sarcoidosis)
- Sulcal effacement (edema)

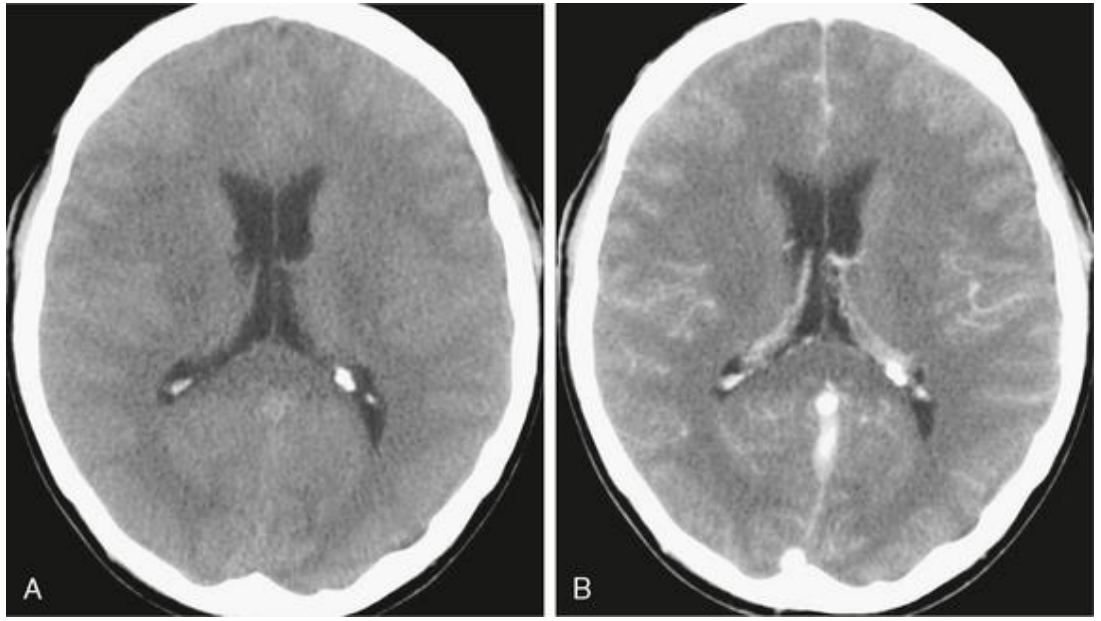

Bacterial meningitis. A 35-year-old man presented with headache and neurologic signs of meningeal disease. A, Axial noncontrast scan shows obliteration of the sulci over the hemispheres. No enlargement of the ventricles was observed. B, Subtle meningeal enhancement was noted on contrast-enhanced CT scan.

Merci



