Computed Tomography

- Chest CT
- Prepared By: BY AHMED JASEM ABASS
- MSC of Medical Imaging



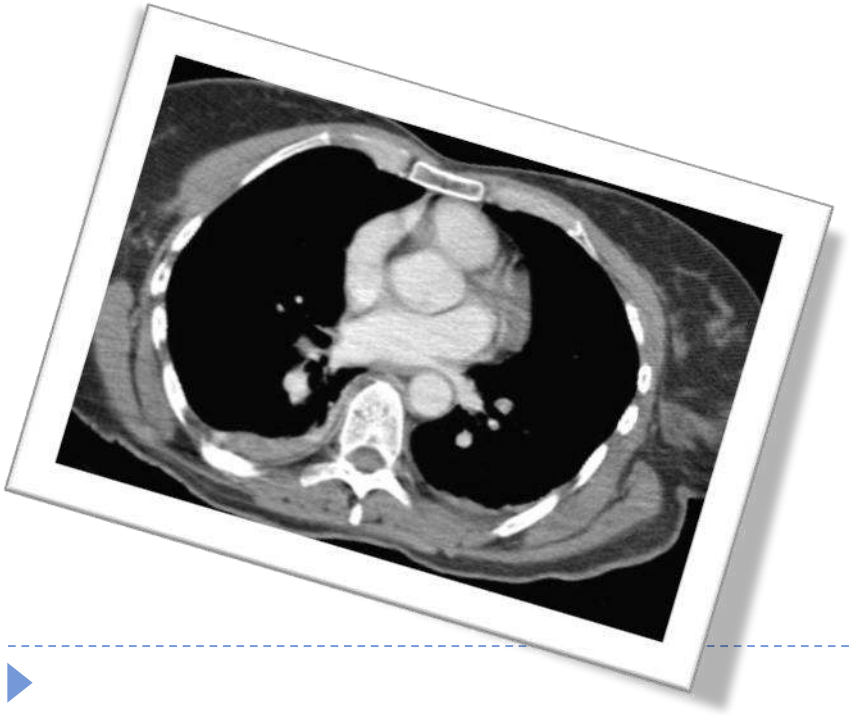



Chest CT scanning

- is a noninvasive medical test that helps physicians diagnose and treat medical conditions.
- CT scan is better for chest 
- CT it show many different types of tissue, including the lungs, heart, bones, soft tissues, muscle and blood vessels in short time.

Types of chest CT scan

- 1-Standard or conventional CT:
- 2- HRCT
- 3- Pathology (C+)
- 4- Pulmonary Embolism scan



1.Standard or conventional CT:

- Slice thickness: 3-10 mm
- Scans a large volume, very quickly
- Covers the full lung
- +/- contrast

- Indications
- Chest x- ray (CXR) abnormality
- Lung cancer staging
- F/U metastases
- Pleural and mediastinal abnormalities
- Empyema
- Chest trauma.



Contraindication

1. Pregnancy.
2. Hypersensitivity to iodinated contrast media(if contrast is used).
3. Renal failure.
4. Heart disorder



2- HRCT

- Without contrast.
- High kV, mAs & thin slices to produces a high spatial resolution and anatomic detail
- No preparation
- Sedation if needed.
- Narrow x-ray beam collimation: 1-1.3 mm vs. conventional 3-10 mm
- Cross sections are further apart: 10 mm
- High definition images of lung parenchyma: vessels, airspaces, airway and interstitium



HRCT Indications

- Diffusely abnormal CXR
- Baseline for patients with diffuse lung disease
- Solitary pulmonary nodules
- Reversible (active) vs. non-reversible (fibrotic) lung disease
- Hemoptysis
- Lung biopsy guide
- Follow up known lung disease



Patient position

- Supine, in the center of the table
- Head first in the gantry (child, head first to see the chest movement during the breathing after the sedation).
- Table height
- The arms are above the head.
- The external laser liner in the chine.

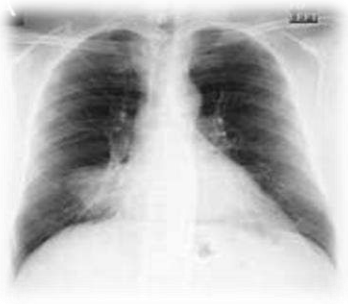

Scout Images:

- PA : plane 180°

Scan parameters:

Type of scan	KV	MA	Scan delay	Slice thick	Recon	pitch	FOV	Recon. Algorithm
Spiral (axial) Inspiration	120	Auto M.A	0.7 sec	2.5 ×2.5	1.25 ×5	1.375 speed 27.5	Large 30-40	standard lung
Spiral Expiration & Prone	120 Axial	Auto m.A	0.7 sec	1.25 ×10	_	_	Large	Lung

Window

		window	level	
spiral 1	Standard	500	35	Soft tissue
spiral 2 & 3		1500	- 300	Lung widow



- **Reformatting:** sagittal & coronal

- Note:

- FOV is as small as possible while still including all of the soft tissue and the upper abdominal part (to check the metastasis).



3- Pathology (C+)

Preparation:

- NPO 3-4 hours before the procedure.
- Not allergic or asthmatic.
- Renal function test normal
- Canulla in the Rt arm, size 18, 20 Gag.
- Sedation if needed



Procedure

- Inspiration technique: As HRCT

- Patient position: As HRCT

- IV Contrast media:

1. Omnipaque

- Adult : 300
- Child: 250



Contrast media

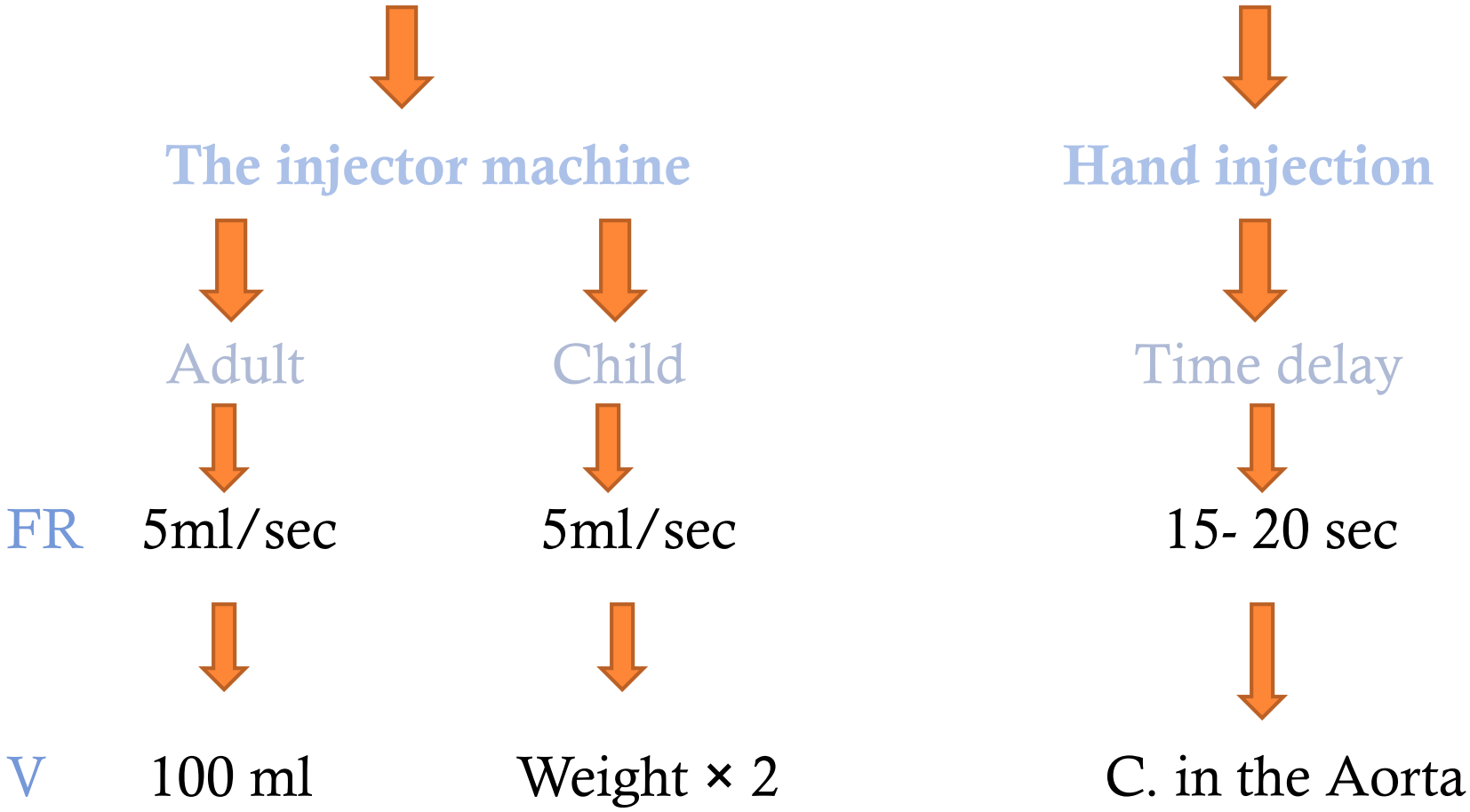

- **Scan parameters & Window :** as Inspiration HRCT
- 2nd Reconstruction: 1.25× 1.25
- **Axial & Sagittal – Soft window**

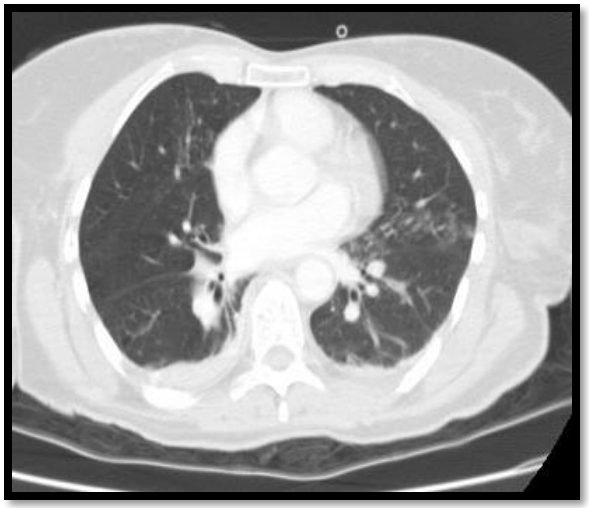

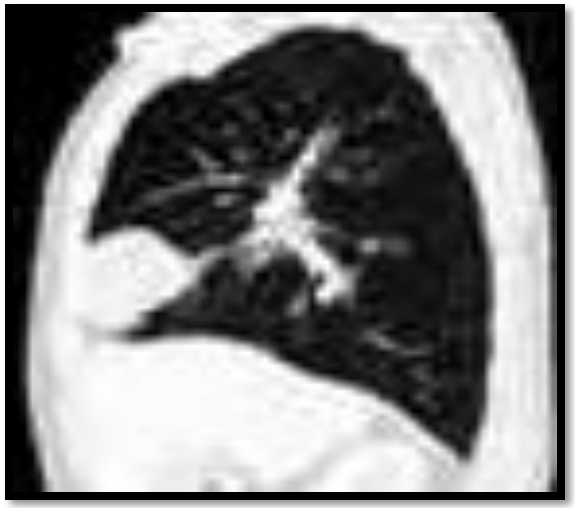

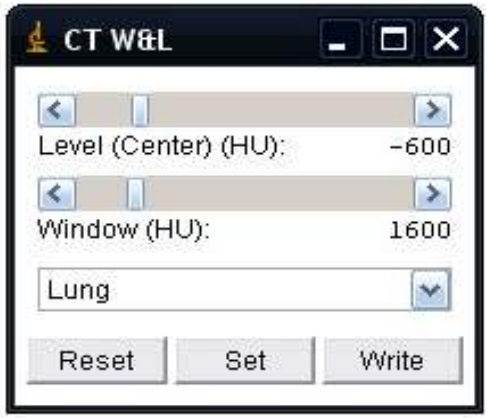

4- Pulmonary Embolism scan

- Fast helical CT scanning to visualization of the pulmonary vessels and lung parenchyma during the injection of a CM to detect any obstruction.

- Optimal contrast should be in the pulmonary arteries, but not in the pulmonary veins.

- Patient Preparation & position: As 2nd tech.

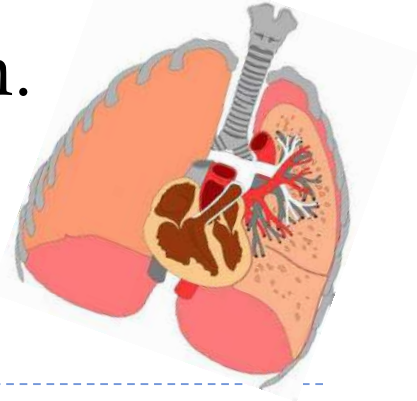

- Main thing: calculate the contrast time that start from the injection until it will enter in the **main pulmonary artery**



- Two ways to calculate the timing:

1. Smart Prep
2. Bolus timing

- Then selected in the computer.

A- Smart Prep

- In case if:

1. The heart rate abnormal (above 110-140)
2. Obese patient (above 110 Kg).

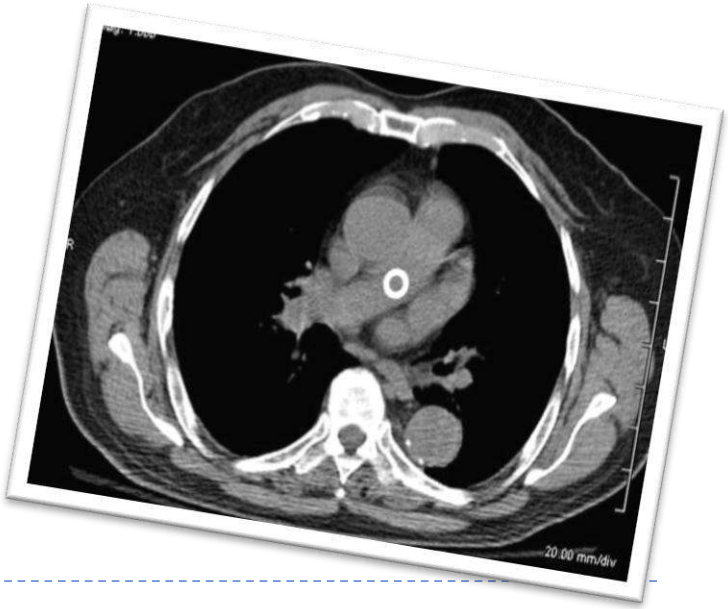

Scan parameters

Type of scan	KV	MA	Scan delay	sec	S.T	Recon.	pitch	FOV	Recon. Alga.
Helical spiral	120 - 140	auto	0.7 sec	0.7 sec	1.25 ×0.6	2.5 × 2.5	1.375 speed 27.5	large	- standard - lung

Window

		window	Level
spiral 1	soft tissue	800	100
spiral 2	lung window	1500	- 300



b- Bolus Timing

- In case if the heart rate normal (70-90)

- Procedure

1. PA scout (to localize the pulmonary trunk).
2. FOV only in the **bifurcation** of the trachea and take CT images.

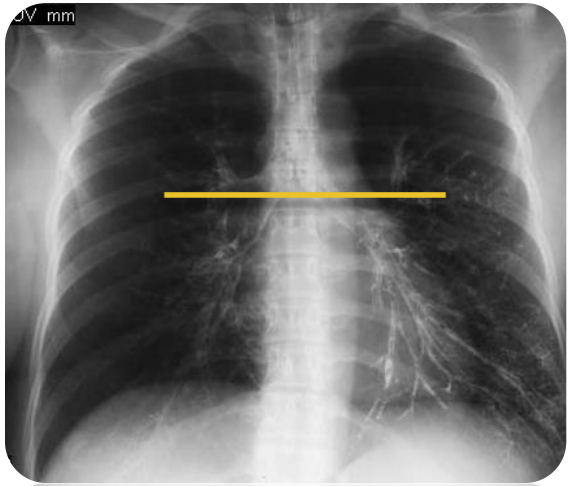

1 - Serview



2 - Locator

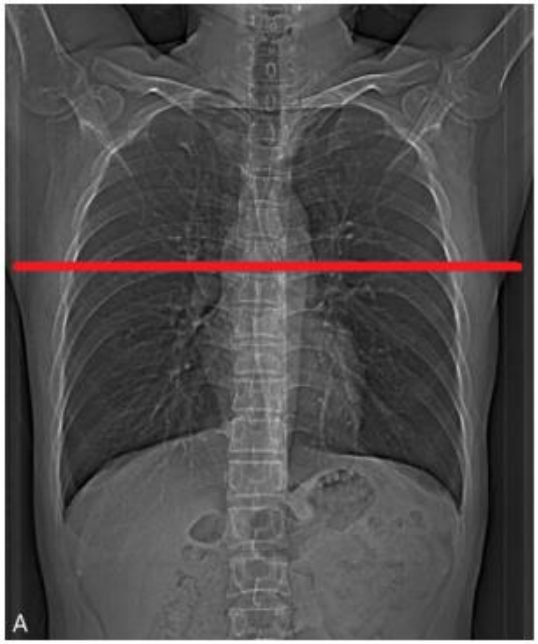

4 - Helical CTA



3 - Tracker (ROI)

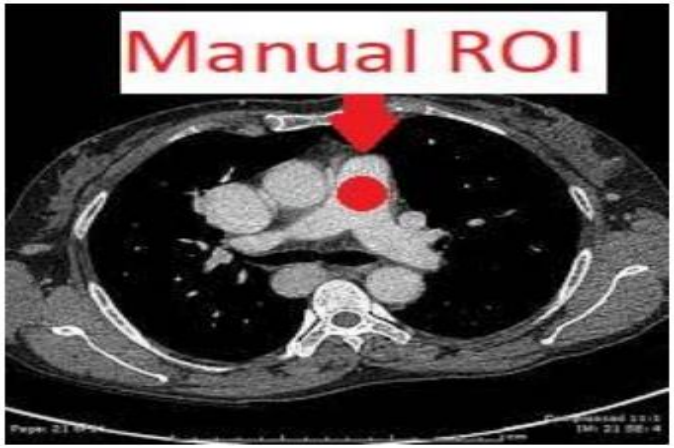

- Then do the normal image from down- up with same before and fixed the scan time manually.

- This graph shows that the contrast injected into the vein reached the pulmonary trunk in 8 seconds.

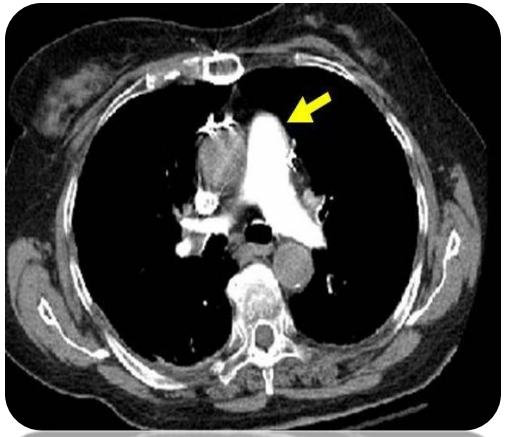

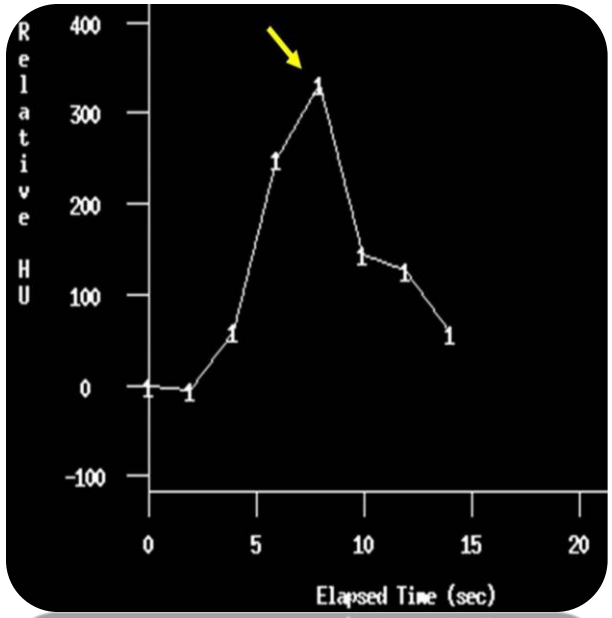

I.V. Contrast

1. Smart Prep: Adult: 100 ml – 5 ml/ sec
2. Bolus timing: Scan time × 5 = volume

Head first
70 cc contrast
4 cc/sec flow rate



The bolus timing is Better than the Smart Prep

- Less C. dose, so there is chance to repeat the scan again if there is any mistake (the max dose is 100 ml/ day).



After care

- Pt. can eat or drink as normal.
- Drink fluids to flush the contrast.
- Bandaged contrast injection site.
- Watch the patient for adverse contrast reactions.




Thank You!
shawnliv.com