Electrocardiogram (ECG)

An ECG is a test that measures the electrical activity of the heart. It helps in diagnosing various heart conditions by recording the timing and strength of the electrical signals as they pass through the heart. Here are some key points:

- **How it works**: Small electrodes are placed on the skin of your chest, arms, and legs. These electrodes detect the electrical signals produced by your heart each time it beats.
    - **What it shows**: The ECG can show if the heart is beating too fast, too slow, or irregularly. It can also indicate if parts of the heart are overworked or too large & The cause of chest pain. For example, it may show signs of blocked or narrowed heart arteries.

You may need an ECG if you have:

- Chest pain.
- Dizziness, lightheadedness or confusion.
- Pounding, skipping or fluttering heartbeat.
- Fast pulse.
- Shortness of breath.
- Weakness or fatigue.
- Reduced ability to exercise.

Types of ECG

- **Resting ECG**: Done while you are lying down.
- **Stress ECG**: Done while you are exercising.
- **Holter monitor**: A portable device worn for 24-48 hours to record heart activity over a longer period.

Parts of the ECG explained

- **P Wave**
  - Represents: Atrial depolarization.
  - Appearance: Small, upward deflection.
- **PR Interval**
  - Represents: Time for impulse to travel from atria to ventricles.
  - Duration: 0.12 to 0.20 seconds.
- **QRS Complex**
  - Represents: Ventricular depolarization.
  - Appearance: Series of three deflections (Q, R, S).
  - Duration: Less than 0.12 seconds.
- **ST Segment**
  - Represents: Period between ventricular depolarization and repolarization.
  - Appearance: Flat, isoelectric line.
- **T Wave**
  - Represents: Ventricular repolarization.
  - Appearance: Small, upward deflection.

- **QT Interval**
  - Represents: Total time for ventricular depolarization and repolarization.
  - Duration: Less than 0.44 seconds.
- **RR Interval**
  - Represents: Time between two consecutive R waves.
  - Significance: Used to calculate heart rate.
- **U Wave (if present)**
  - Represents: Repolarization of Purkinje fibers or papillary muscles.
  - Appearance: Small, upward deflection following the T wave.
  -

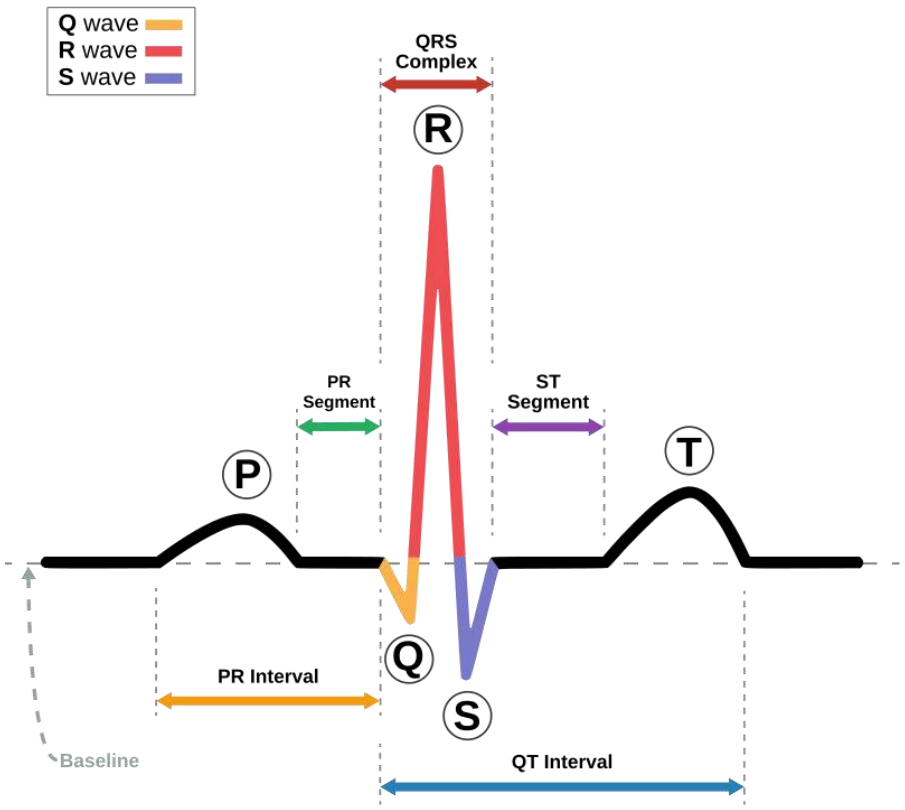

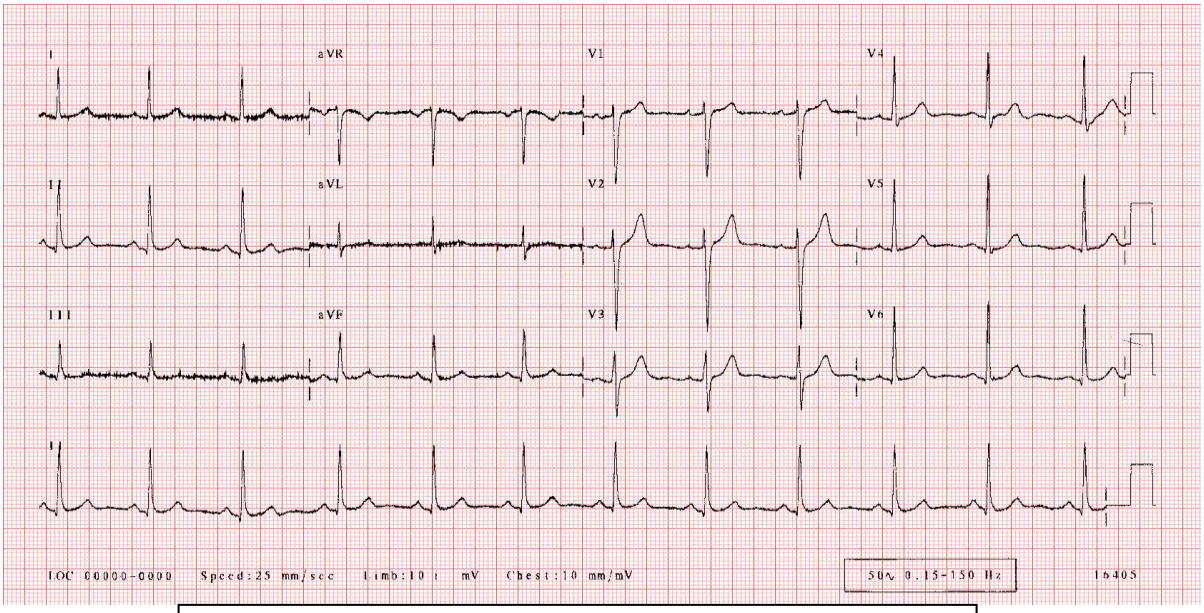

Normal Adult ECG

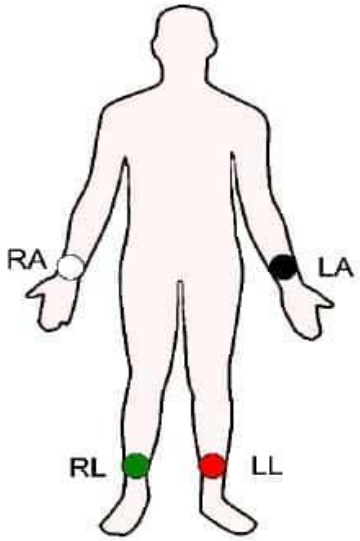

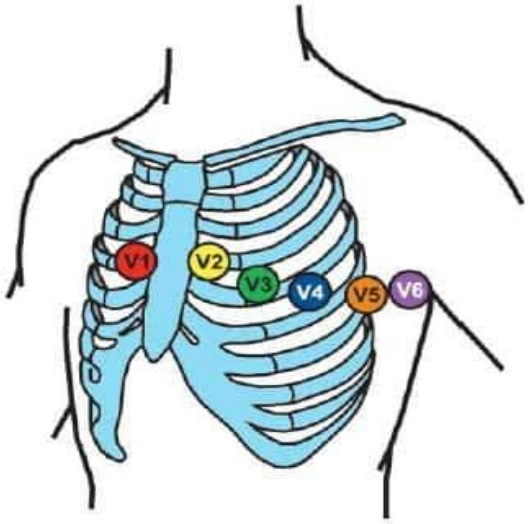

RA – right forearm or wrist
LA – left forearm or wrist
LL – left lower leg, proximal to ankle
RL – right lower leg, proximal to ankle
V1 – 4-th intercostal space, right sternal edge
V2 – 4-th intercostal space, left sternal edge
V3 – midway between V2 and V4
V4 – 5-th intercostal space, mid-clavicular line
V5 – anterior axillary line in straight line with V4
V6 – mid-axillary line in straight line with V4 and V5

ECG electrode placement