Endotracheal intubation

Is a skill performed by multiple medical specialists to secure a patient's airway as well as provide oxygenation and ventilation, Direct and indirect laryngoscopy are the two most common approaches utilized for endotracheal intubation

History of intubation

LARYNGOSCOPY began in the 1800s with indirect attempts to visualize the glottis, In the 1900s, Chevalier Jackson, Miller, and Magill pioneered the era of direct laryngoscopy. In the 1960s the flexible fiberoptic bronchoscope was established as the gold standard for difficult airway management.

In the 2000s, the era of video laryngoscopy began which is a very beneficial device helping in the management of difficult intubation with ease of use and portability.



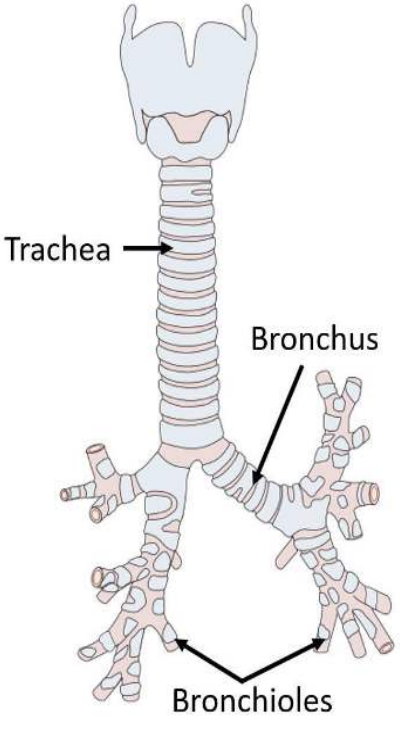

Anatomy

The upper airway consists of the oral cavity and pharynx, and larynx These structures humidify and warm the air.

The trachea bifurcates into the right and left mainstem bronchi at the fifth thoracic spine. The obtuse angle between the trachea and the right mainstem bronchus makes it more prone to right mainstem intubation if the endotracheal tube is advanced too distally.

Indications of endotracheal intubation

1. Upper airway obstruction.
2. Respiratory failure.
3. Loss of consciousness.
4. For supporting ventilation during general anesthesia.
5. Patients at risk of pulmonary aspiration.
6. Difficult mask ventilation.
7. Any patient in danger of upper airway obstruction (e.g. Burns of the upper airways).
8. Cardiac arrest (during CPR).

Airways assessment

1. Mallampati classification: This test is performed with the patient in the sitting position, head in a neutral position, the mouth wide open, and the tongue protruding to its maximum.

1. Class I: Visualization of the soft palate, uvula, and anterior and posterior pillars.
2. Class II: Visualization of the soft palate and uvula.
3. Class III: Visualization of soft palate and base of uvula.
4. Class IV: The only hard palate is visible. The soft palate is not visible at all. Class III, IV difficult to intubate.

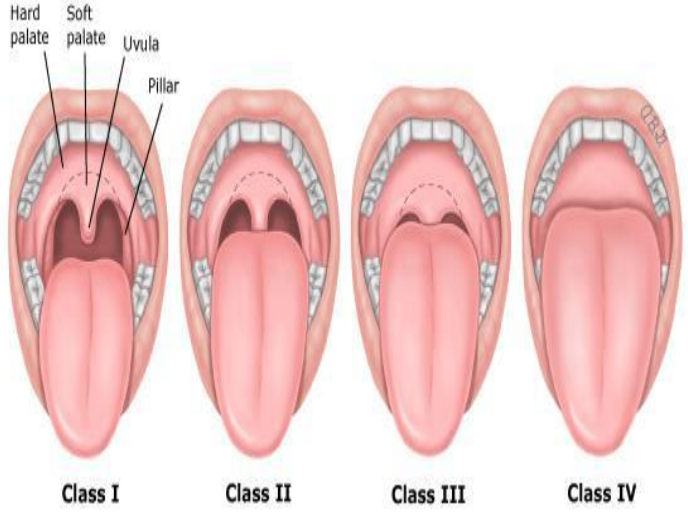



2.Interincisor gab: Normal >4.5 cm.
3. Thyromental distance: more than 6 cm.
4. Flexion and extension of the neck.
5. Others.

Preparing the procedure...

Essentials must be present to ensure safe intubation!
They can be remembered by the word **SALT**

• **Suction**: This is extremely important. Often patients will have secretions in the pharynx, making visualization of the vocal cords difficult.
• **Airway**: the oral airway is a device that lifts the tongue off the posterior pharynx, often making it easier to mask and ventilate a patient. Also, a source of O2 with a delivery mechanism (Ambu bag and mask) must be available.
• **Laryngoscope**: This is vital to placing an endotracheal tube.
• **Tube**: Endotracheal tubes come in many sizes. In the average adult a size 7.0 or 8.0 ID endotracheal tube.

Instruments used...

- Ambu bag, tube, and oxygen source.
- Plaster or tube holder.
- Introducer (stylets or Magill forceps).
- Laryngoscope.
- Suction apparatus.
- Syringe, 10-mL, to inflate the cuff.
- Gloves.
- Pulse oximeter.
- Stethoscope.

Verifying Tube Placement

1. Visualize the tube passing through the cords.
2. Misting of the tube with respirations (not always reliable).
3. Movement of the chest with respirations.
4. Auscultation of the chest (You should hear breath sounds on both sides of the chest).
5. Auscultation of the stomach (You shouldn't hear gurgles here when bagging).
6. Waveform EtCO2 with numeric reading. (The best method)
7. Esophageal detector device.
8. Rising or stable O2 saturation.

Difficult Intubation

2021 American Society of Anesthesiologists defines a difficult airway as the clinical situation in which anticipated or unanticipated difficulty or failure is experienced by a physician trained in anesthesia care, including but not limited to one or more of the

following: facemask ventilation, laryngoscopy, ventilation using a supraglottic airway (LMA), tracheal intubation.

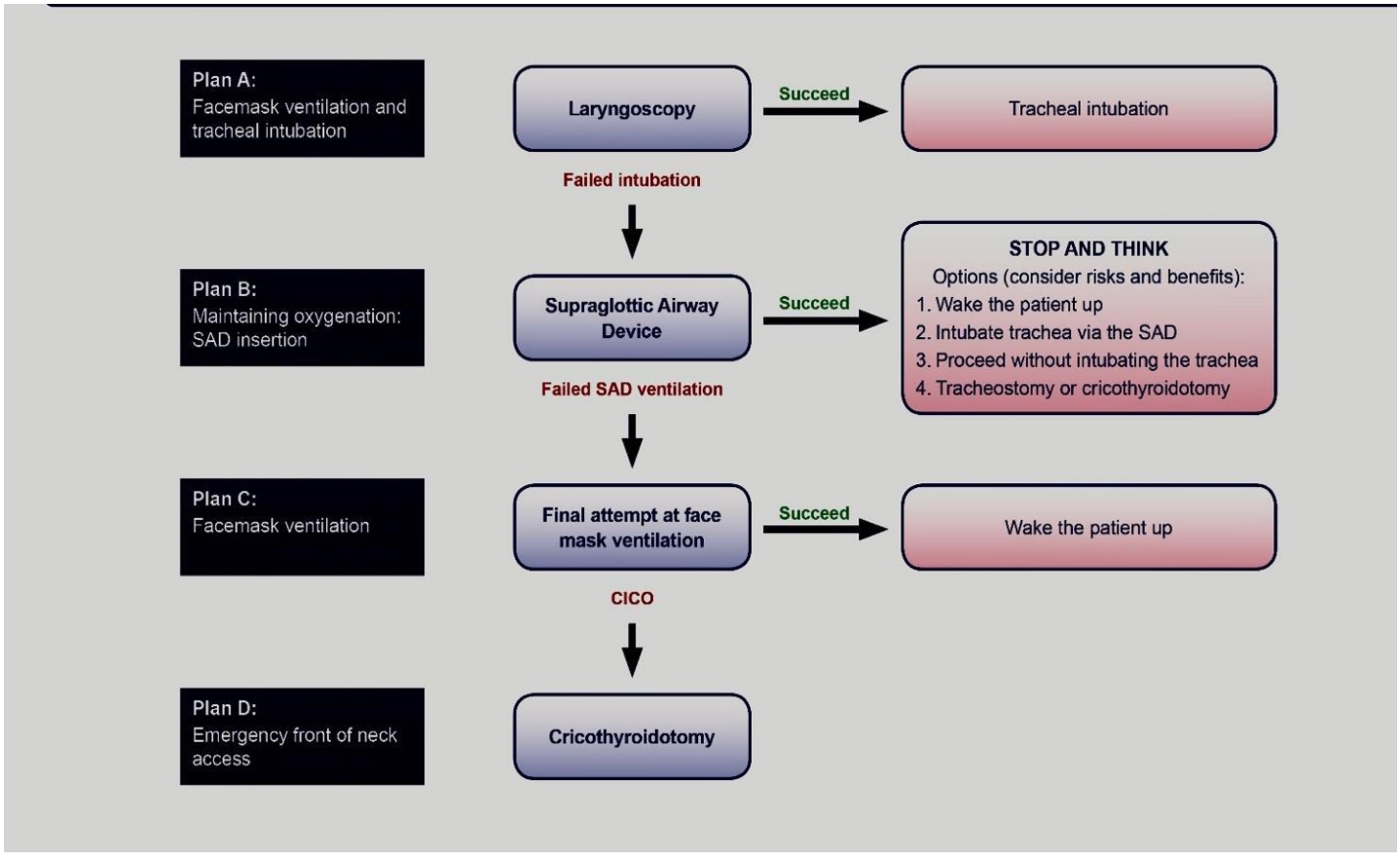

UNANTICIPATED DIFFICULT INTUBATION

1. **Call** for help, **communicate** the problem and **delegate**.
2. Request difficult airway trolley.
3. Monitor the time, SpO_2 and $EtCO_2$.
4. Confirm bag and mask ventilation.

If ventilation is unsuccesful,

5. Maximize laryngeal view: neck flexion head extension
   adjust cricoid pressure
   attempt external manipulation
   consider long or straight blade
   McCoy or video laryngoscope
6. Allow up to 4 intubation attempts if SpO_2 permits
7. Attempt 2 LMA™ insertions*
8. If after attempted ventilation and intubation,
   SpO_2 <90% with FiO_2=1
   No breath sounds or chest movement
   Flat $EtCO_2$ trace *then*
   Call CICV emergency response.

This is not a checklist but a protocol requiring regular rehearsal.

There is overlap of the **'Difficult Mask Ventilation'** and **'Difficult Intubation'** protocols, as each technique uses the other as a rescue alternative.

The following summarizes the protocols.

1. Can't bag and mask	*Options:* Wake the patient if possible Use LMA™ as rescue device Intubate
2. Can't intubate	*Options:* Wake the patient if possible Bag and mask Use LMA™ as rescue device

If none of the above options is successful, implement the CICV emergency response.

Always delegate **a timekeeper and SpO_2 observer** (calling elapsed time intervals and saturations) and be aware that multiple intubation attempts can convert a 'can't intubate ***can*** ventilate' to a 'can't intubate ***can't*** ventilate' emergency (also known as 'cant intubate can't oxygenate').

Given the variability in difficult airway scenarios, familiarity with the decision making process and the underlying principles is a prerequisite for safe practice.

*Trying LMA™ insertion after muscle relaxation (given for attempted intubation) may improve rescue success rate.

Once ventilation of the lungs is established with persistent CO_2 waveform, the airway can be secured by an increasing number of techniques available. The clinician should use that which is most familiar and likely to be successful in the particular clinical circumstance.

Always preoxygenate the patient before induction if possible.

CAN'T INTUBATE CAN'T VENTILATE

Cannula Cricothyroidotomy

1. Palpate (NDH) and puncture (DH) the cricothyroid membrane.
2. Stabilize syringe (DH) and slide cannula into trachea (NDH).
3. Confirm position by aspirating the full length of the syringe.
4. Attach the ventilation system to the cannula.
5. Begin cautious ventilation – 1 second inflation, 3 second pause with high pressure (jet) ventilation.
6. Confirm ventilation of lungs and exhalation through the upper airway.
7. If unsuccessful or complications develop, proceed immediately to surgical cricothyroidotomy.

Recommendations:

Choose a 14g kink resistant cannula.
Syringe size between 5 and 20ml. DAS (UK) suggests 20ml.

Review equipment on difficult airway trolley on a regular basis.
Be familiar and confident with high pressure ventilation.
Regularly rehearse the steps outlined.
Attend advanced airway workshops for hands on experience.

DH=dominant hand
NDH=non dominant hand

Surgical Cricothyroidotomy

If the anatomy is palpable.

1. Identify cricothyroid membrane.
2. Stab incision through skin and membrane. *Enlarge with dilator or blunt dissection (scalpel handle or forceps).*
3. Caudal traction on cricoid cartilage with tracheal hook.
4. Insert ETT or tracheostomy tube.
5. Ventilate from a standard low pressure source.
6. Confirm ventilation with $EtCO_2$.

Alternatively, once a horizontal stab incision is made, the scalpel blade can be rotated caudally and with lateral pressure allowing a space for a **ventilating bougie** to be passed.

If the anatomy is not palpable, a 6 to 8cm midline vertical neck incision with blunt finger dissection to separate the strap muscles will expose the trachea. Cannula cricothyroidotomy can then be achieved under vision.

In all cases, once there has been successful oxygenation, early conversion to a definitive airway is required.

CICV sometimes referred to as **CICO** *(can't intubate can't oxygenate).*

Selects the best single choice

1- Regarding airway assessment for difficult intubation (all true except one)
a) For mallampati score patient in sitting position.
b) Class I and II difficult to intubate.
c) Thyromental distance more than 6cm.
d) Mallampati Class IV: The only hard palate is visible.
e) Normal Interincisor gab: >4.5 cm.
2- Verifying Tube Placement (all true except one)
a) Movement of the chest with respirations.
b) Visualize the tube passing through the cords.
c) Auscultation of the chest, you should hear breath sounds
d) Auscultation of the stomach, you should hear gurgles
e) Capnography.
3- Unanticipated difficult intubation (all true except one)
a) Allow up to 5 intubation attempts if SPO2 permit
b) Attempts 2 LMA insertion.
c) Maximize laryngeal view by extension of the neck.
d) Maximize laryngeal view by head extension.
e) Use of video-laryngoscope