Hepatic masses, the role of images

Hepatic Masses: Opening the Mystery with Imaging

The liver, our body's essential processing unit, can sometimes develop abnormal growths known as hepatic masses. These masses can be benign (noncancerous) or malignant (cancerous). Early and accurate diagnosis is crucial for determining the best course of treatment.

Challenges in Diagnosing Hepatic Masses

- Non-specific symptoms: Hepatic masses often present with vague symptoms like fatigue, abdominal pain, or nausea, making diagnosis challenging.
- Variable presentation: Masses can vary in size, location, and appearance, further complicating diagnosis.

Diagnosing hepatic masses can be challenging due to several factors. Often, patients experience non-specific symptoms like fatigue, abdominal pain, or nausea, which can be attributed to various other conditions. Additionally, hepatic masses themselves can present with a wide range of characteristics, making it difficult to pinpoint the cause solely based on clinical presentation.

Imaging Techniques for Hepatic Masses

- Ultrasound: A widely available and non-invasive imaging test using sound waves to visualize the liver and detect masses. It can provide initial assessment and guidance for biopsy.
- CT scan: A detailed X-ray imaging technique that creates cross-sectional views of the liver. It can be used with contrast dye to differentiate between benign and malignant lesions.
- MRI scan: A powerful imaging modality using magnetic fields and radio waves to produce detailed images of the liver. It can help identify the characteristics of the mass including fat content and blood flow patterns.
- Angiography: An X-ray technique that uses contrast dye to visualize blood vessels supplying the liver. It can be helpful in certain cases to assess vascularity and differentiate tumors.
- **Positron Emission** Tomography-Computed Tomography (PET-CT):

PET-CT is valuable for evaluating hepatic masses, especially in oncologic settings. It provides functional information by detecting metabolic activity, aiding in the differentiation of benign from malignant lesions and detecting metastases.

Role of Images in Characterization of Hepatic Masses

- Size and location: The size and location of the mass can provide clues about its origin and potential malignancy. Well-defined, smooth-bordered masses are generally less suspicious for malignancy than irregular, poorly defined ones.
- Morphology: Well-defined, smooth-bordered masses are less likely to be malignant compared to irregular, lobulated masses.
- Contrast enhancement: The pattern of contrast enhancement on imaging studies can help differentiate between benign and malignant lesions. Malignant tumors tend to enhance rapidly and wash out the contrast agent quickly, while benign lesions may show slower and more uniform enhancement.
- Diffusion-weighted MRI: This MRI technique can assess the movement of water molecules within the mass, which can be helpful in distinguishing benign from malignant tumors. Restricted diffusion, indicated by high signal intensity on the images, is suggestive of malignancy.

Image-Guided Interventions for Hepatic Masses

- Biopsy: A minimally invasive procedure where a small tissue sample is extracted from the mass using a needle guided by imaging techniques, usually ultrasound or CT scan. Biopsy is essential for definitive diagnosis.

- Ablation: Image-guided techniques like radiofrequency ablation (RFA) or microwave ablation can destroy tumors using heat energy delivered through a needle inserted into the mass.



Contrast-enhanced CT showing a large liver mass of the VI, VII and VIII segments, with a maximum diameter of 24 cm (line), along with a sub-capsular haematoma of the VI and VII segments. The inferior vena cava is compressed

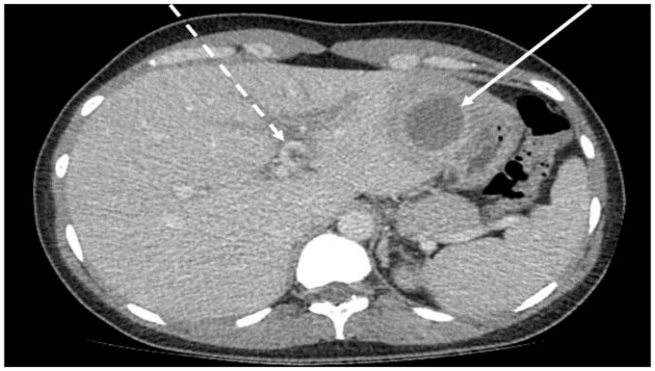

C T of the chest, abdomen, and pelvis with intravenous contrast showed a rim enhancing abscess in the left lobe of the liver and a filling defect in the portal vein consistent with portal vein thrombosis

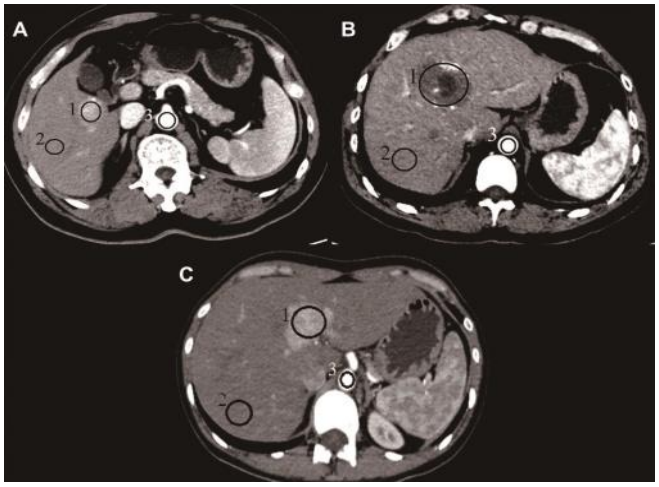

DECT imaging of liver lesions.
Circular or elliptical ROIs were placed in the lesion (#1), normal hepatic parenchyma (#2), and aorta (#3) on the default 70-keV monochromatic images. DECT, dual-energy computed tomography; ROI, region of interest.

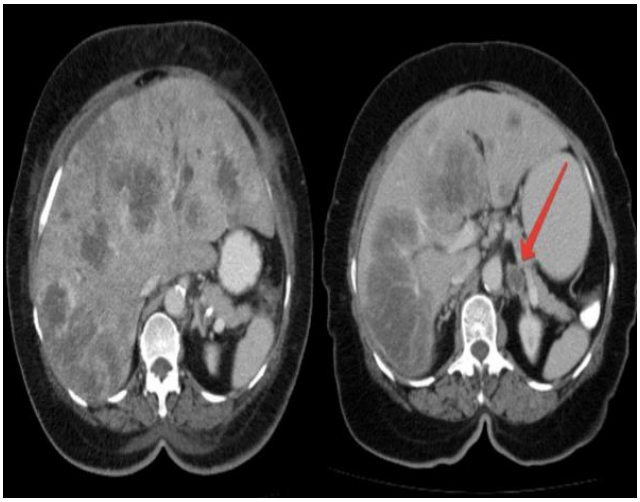

1a: Hepatic mass in the junction of the segment 4a and 4b and multiple liver metastases 1b: 12x16 mm measured solitary mass in the left adrenal gland.

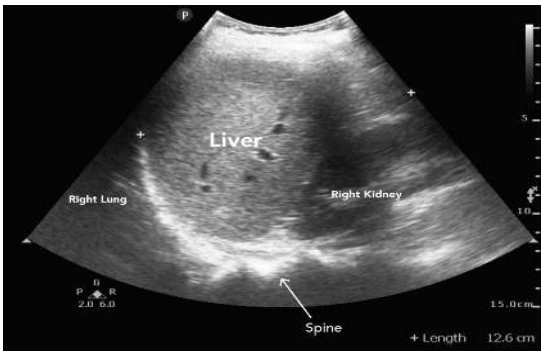







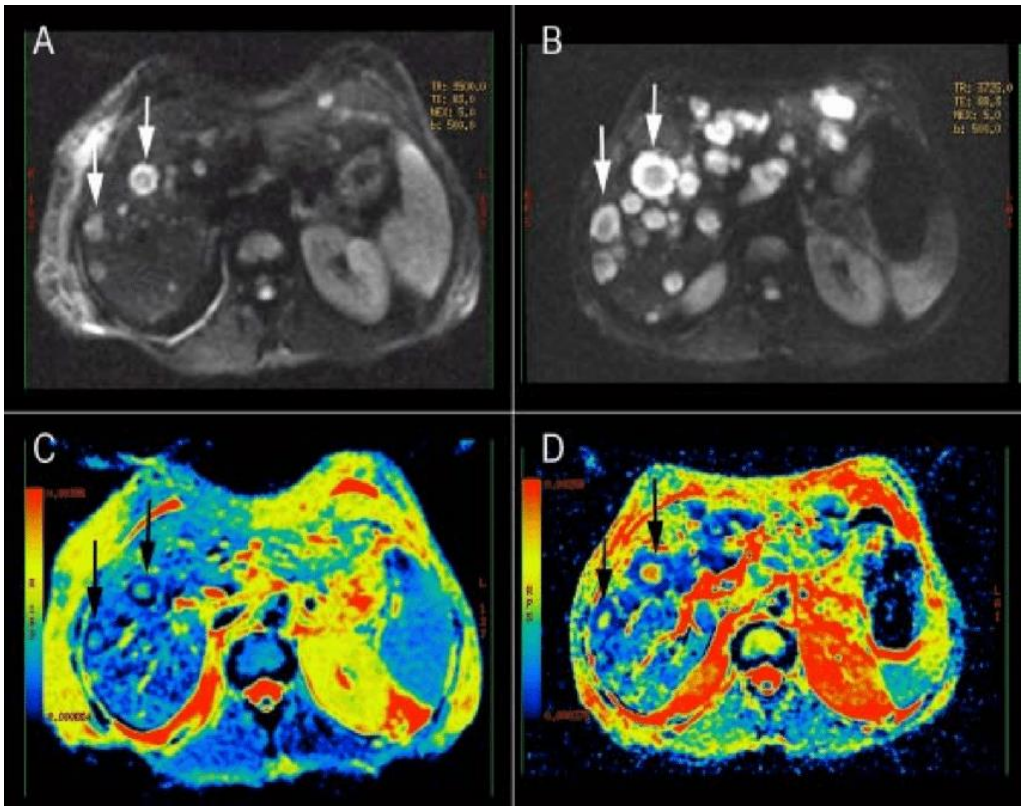

Diffusion weighted (DW) images of the liver in a patient with metastatic small cell lung cancer. A, B. DW images (b value, 500 s/mm 2) showing multiple areas of hyperintensity from metastatic lesions. C, D. ADC (Apparent Diffusion Coefficient) maps of the correspondent DW images; it is possible to identify the variability in the intensity-dependent colouring of some metastatic lesions, showing a darker cell-dense rim and a colored necrotic center (white arrows)..