1.X.RAY HUMERUS: The **AP view of the humerus** is part of the humerus series and is usually taken in a standing position. However, it can also be obtained in a supine position.



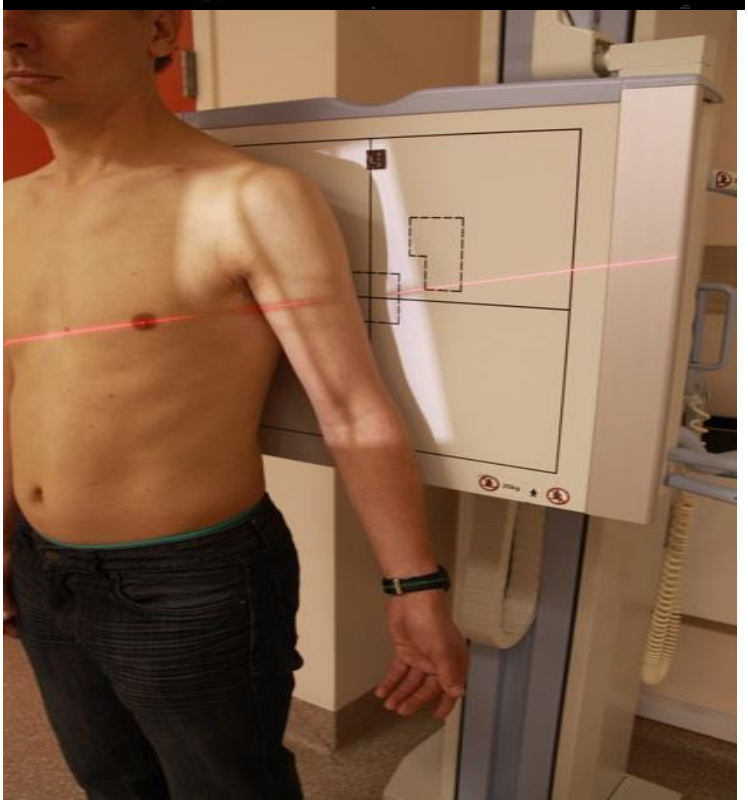

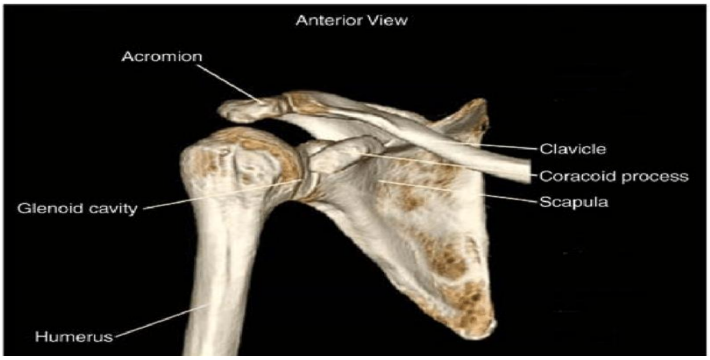

2.CT 3D (SSD)

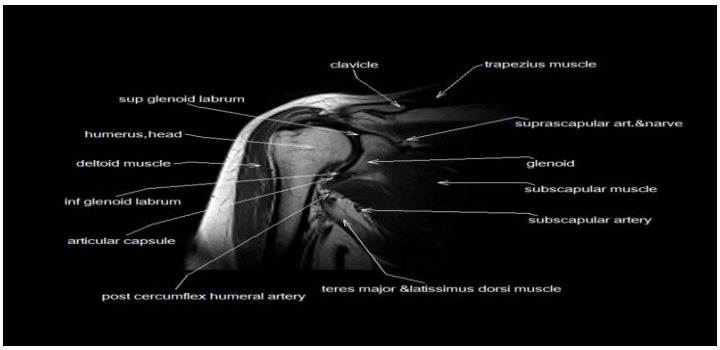

3.MRI(CORONAL)

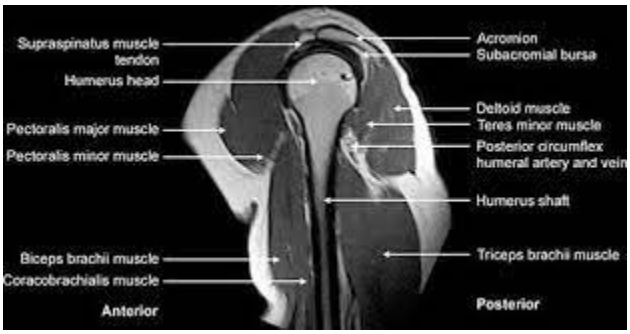

4.MRI sagittal