Infertility

Understanding Infertility: Causes and the Role of Imaging

Infertility is a challenging condition affecting millions of individuals and couples worldwide. Defined as the inability to conceive after one year of regular, unprotected intercourse, infertility can be emotionally and psychologically distressing.

Some common causes include:

- Ovulatory Disorders: Irregular or absent ovulation can significantly impact fertility in women. Conditions such as polycystic ovary syndrome (PCOS) and primary ovarian insufficiency (POI) disrupt normal ovulatory function.
- Tubal Factors: Damage or blockage of the fallopian tubes hinders the transport of eggs from the ovaries to the uterus, resulting in infertility. Pelvic inflammatory disease (PID), endometriosis, and previous pelvic surgeries are common culprits.
- Uterine Abnormalities: Structural abnormalities within the uterus, such as fibroids, polyps, or congenital malformations, can interfere with implantation or embryo development, leading to infertility or recurrent pregnancy loss.
- Male Factors: Male infertility contributes to approximately 40-50% of all infertility cases. Factors include abnormal sperm production, structural abnormalities, or obstruction of the reproductive tract.

- Unexplained Infertility: In some cases, despite extensive evaluation, the cause of infertility remains unidentified, posing additional challenges for diagnosis and treatment.

Role of Imaging in Infertility Diagnosis:

Various imaging modalities offer detailed visualization of reproductive organs, aiding clinicians in making accurate diagnoses and formulating appropriate treatment plans.

- Transvaginal Ultrasound (TVUS): TVUS is a non-invasive imaging technique that provides high-resolution images of the female reproductive organs, including the uterus, ovaries, and fallopian tubes. It helps identify structural abnormalities, such as fibroids, ovarian cysts, or uterine polyps, which may contribute to infertility.
- Hysterosalpingography (HSG): HSG is a specialized X-ray procedure used to evaluate the uterine cavity and fallopian tubes. By injecting a contrast dye into the uterus, clinicians can assess tubal patency and detect abnormalities such as blockages or adhesions that impede fertility.
- Sonohysterography: This procedure involves the infusion of saline solution into the uterus during transvaginal ultrasound, enhancing visualization of uterine abnormalities such as polyps, fibroids, or intrauterine adhesions.
- Magnetic Resonance Imaging (MRI): MRI provides detailed images of pelvic structures with superior soft tissue contrast, making it valuable for assessing complex uterine or ovarian abnormalities not adequately visualized by other modalities.
- Semen Analysis: While not a form of medical imaging, semen analysis plays a crucial role in evaluating male fertility. It assesses sperm count, motility, morphology, and other parameters essential for male reproductive function.

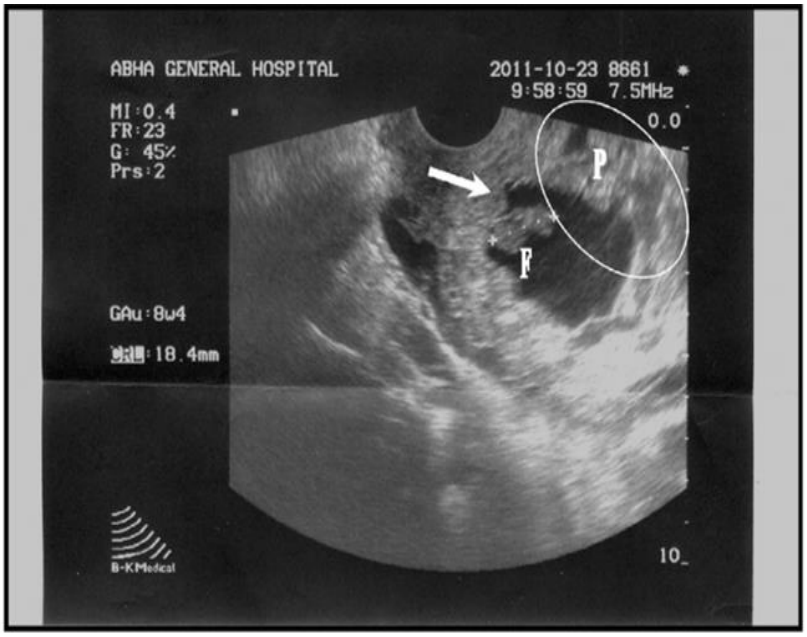

A trans-vaginal ultrasound scan showing the placenta implanted low and anteriorly with irregular-shaped hypoechoic and anechoic spaces that infiltrated the retroplacental zone and adjacent myometrium. The arrow indicates the internal os.

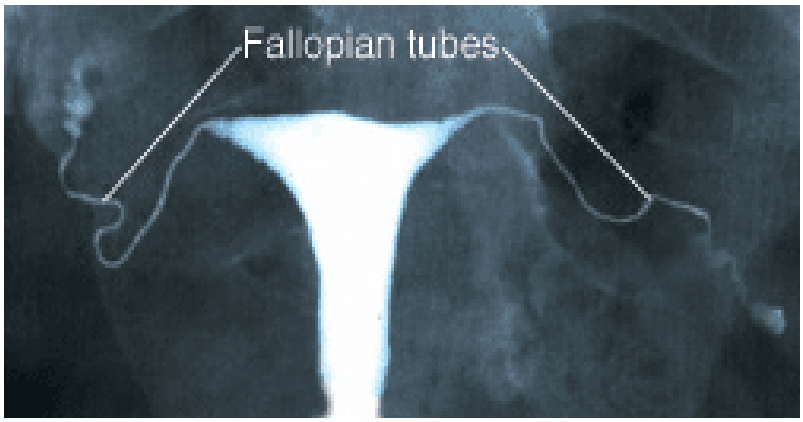

NORMAL Hysterosalpingography



Hysterosalpingography

Septum of Uterus

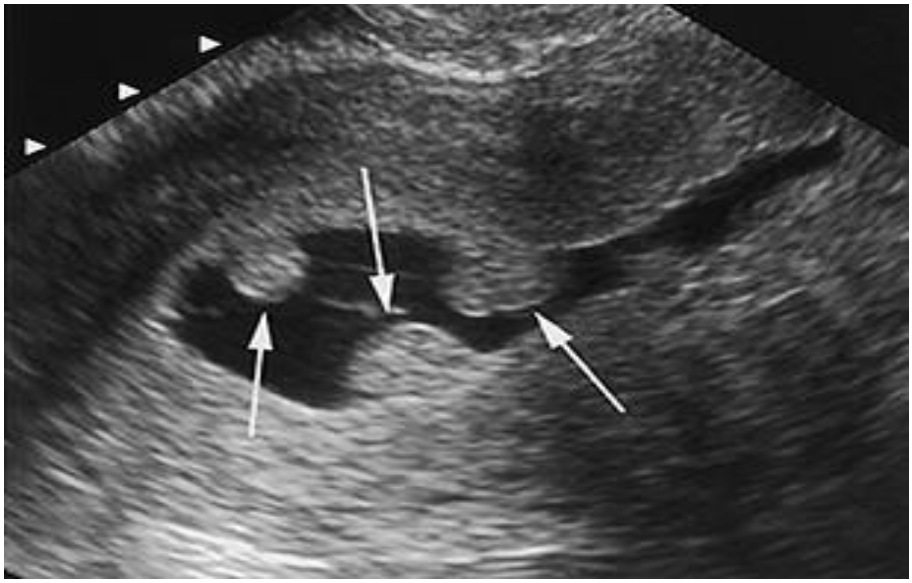

Sonohysterography

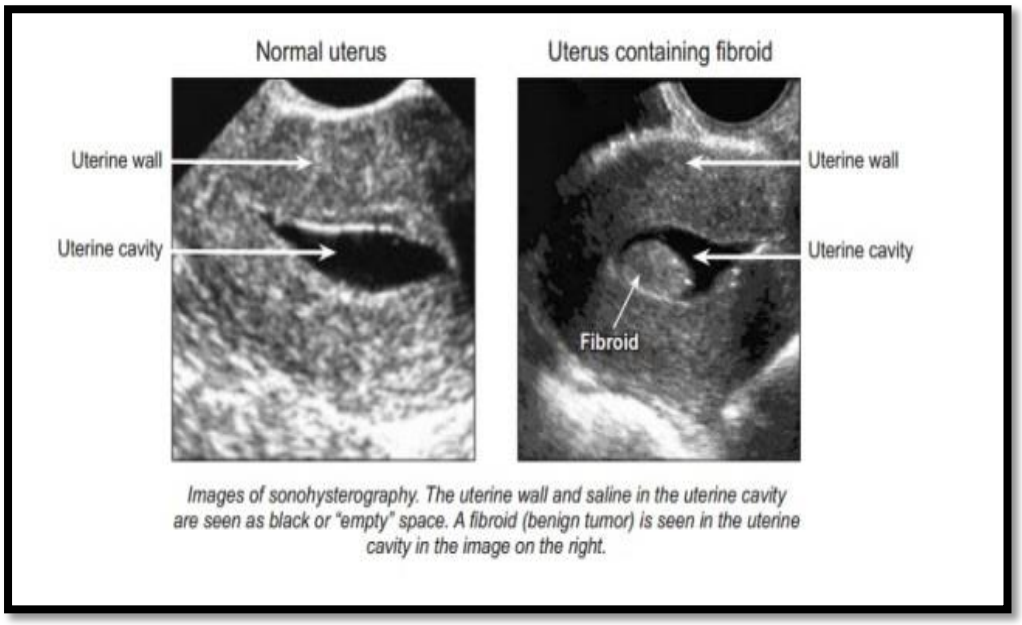

Images of sonohysterography. The uterine wall and saline in the uterine cavity are seen as black or "empty" space. A fibroid (benign tumor) is seen in the uterine cavity in the image on the right.

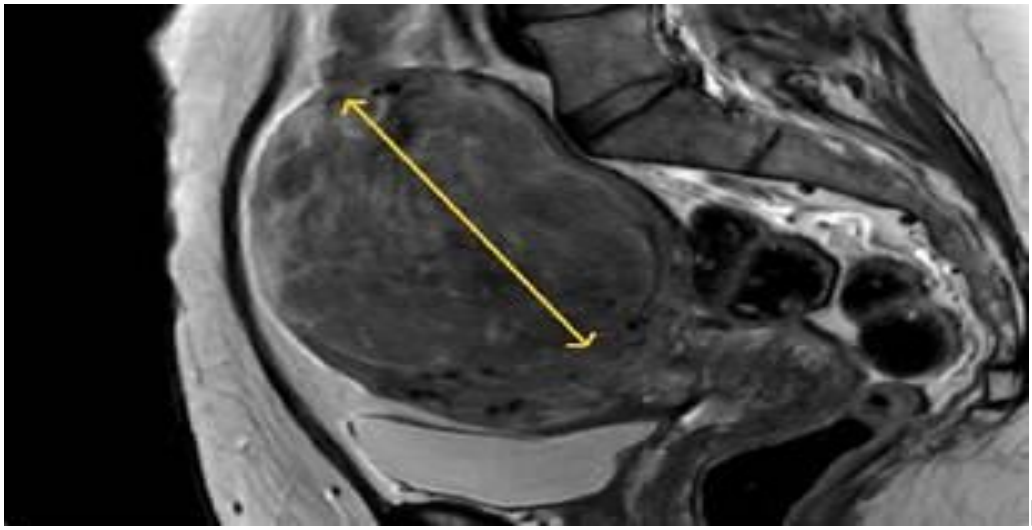

RMI FIBROID