Lateral skull radiograph

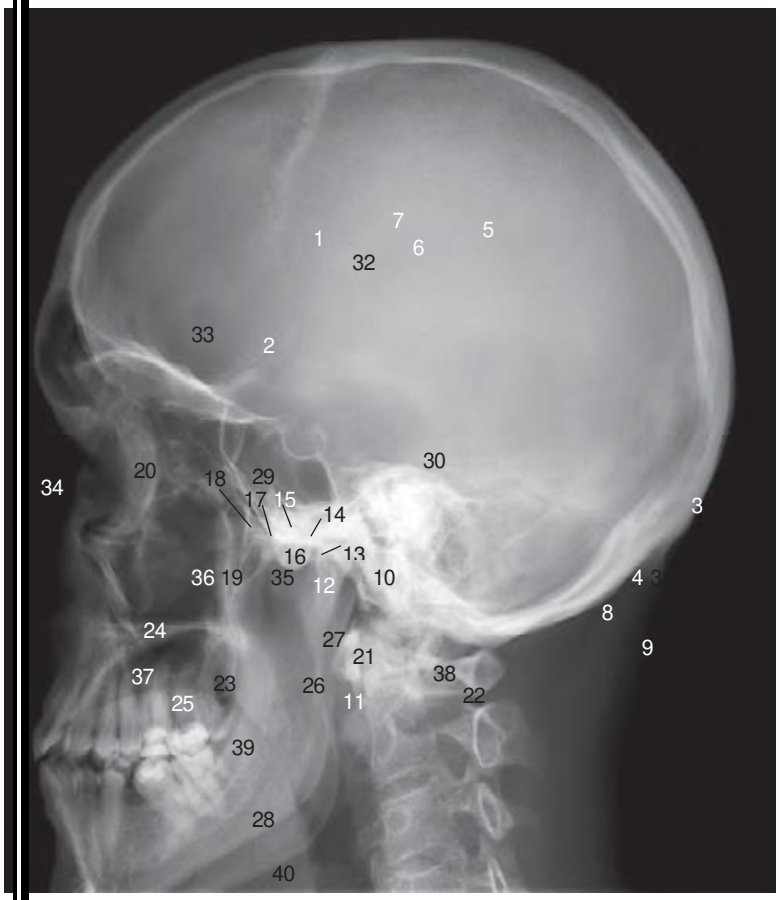

Bony landmarks

1. Bregma
2. Coronal suture
3. Lambda
4. Lambdoid suture
5. Vertex
6. Inner skull table
7. Outer skull table
8. Internal occipital protuberance
9. External occipital protuberance
10. External auditory meatus
11. Styloid process
12. Clivus
13. Dorsum sellae
14. Posterior clinoid process
15. Anterior clinoid process

17. Tuberculum sellae
18. Planum sphenoidale
19. Greater wings of sphenoid
20. Undulating floor of anterior cranial fossa (roof of orbit)
21. Anterior limit of foramen magnum
22. Posterior limit of foramen magnum
23. Posterior wall of maxillary sinus
24. Floor of orbit
25. Hard palate
26. Neck of mandible
27. Temporomandibular joint
28. Condylar (mandibular) canal

Vascular markings

29. Middle meningeal vessels: anterior branches
30. Middle meningeal vessels: posterior branches
31. Transverse sinus
32. Diploic vein
33. Diploic venous confluence: parietal star

Sinuses/air cells

34. Frontal sinus
35. Sphenoid sinus
36. Posterior ethmoidal cells
37. Maxillary sinus
38. Mastoid air cells

Soft tissues

39. Soft palate
40. Base of tongue

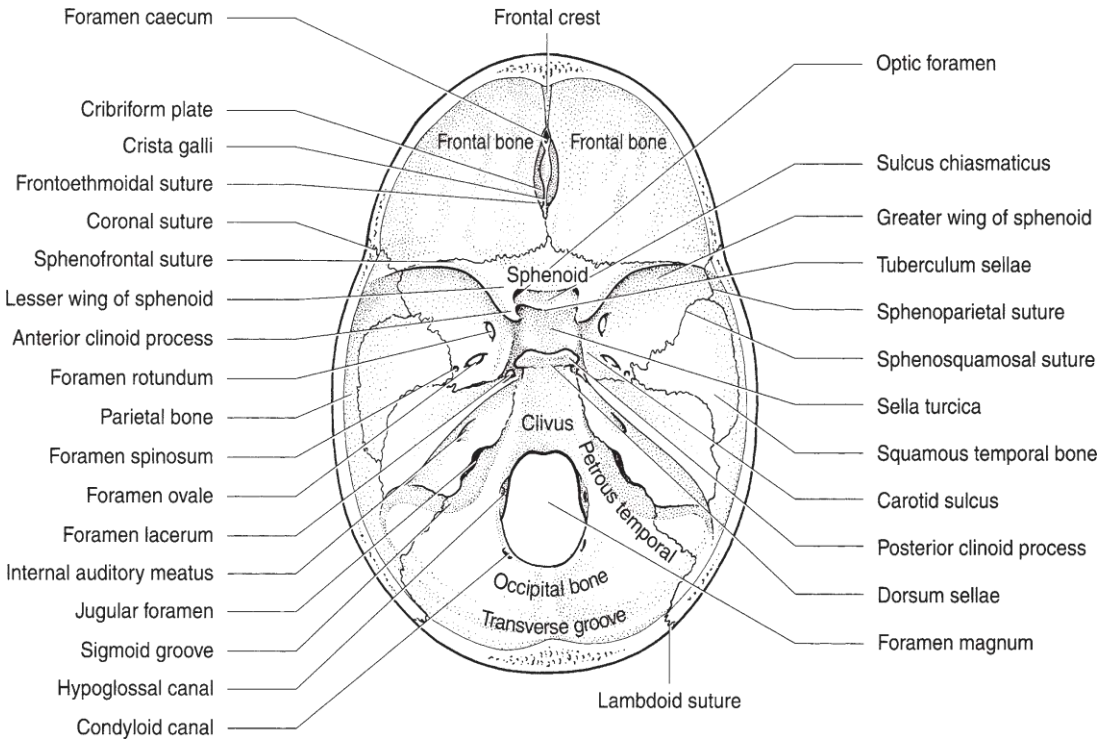
Foramen caecum
Cribriform plate
Crista galli
Frontoethmoidal suture
Coronal suture
Sphenofrontal suture
Lesser wing of sphenoid
Anterior clinoid process
Foramen rotundum
Parietal bone
Foramen spinosum
Foramen ovale
Foramen lacerum
Internal auditory meatus
Jugular foramen
Sigmoid groove
Hypoglossal canal
Condyloid canal
Frontal crest
Frontal bone
Frontal bone
Sphenoid
Clivus
Petrous temporal
Occipital bone
Transverse groove
Lambdoid suture
Optic foramen
Sulcus chiasmaticus
Greater wing of sphenoid
Tuberculum sellae
Sphenoparietal suture
Sphenosquamosal suture
Sella turcica
Squamous temporal bone
Carotid sulcus
Posterior clinoid process
Dorsum sellae
Foramen magnum


1
5
6
2
3
4
7
8
9
10
11
B

(A) Skull base: internal aspect
(B) 3D CT of skull base, internal aspect

1. Crista galli
2. Anterior clinoid process
3. Optic canal
4. Posterior clinoid process
5. Cribriform plate
6. Posterior ethmoidal foramen

7.Foramen ovale
8.Foramen spinosum
9.Foramen lacerum
10.Jugular foramen
11.Foramen magnum



Lateral radiograph of nasal bones

1. Frontonasal synchondrosis
2. Nasal spine of frontal bone
3. Groove for anterior ethmoidal nerve

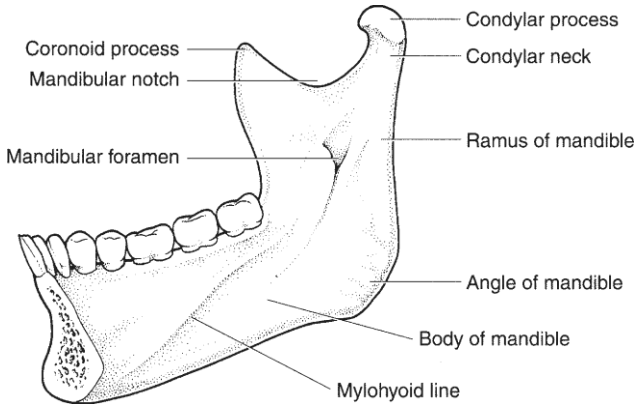

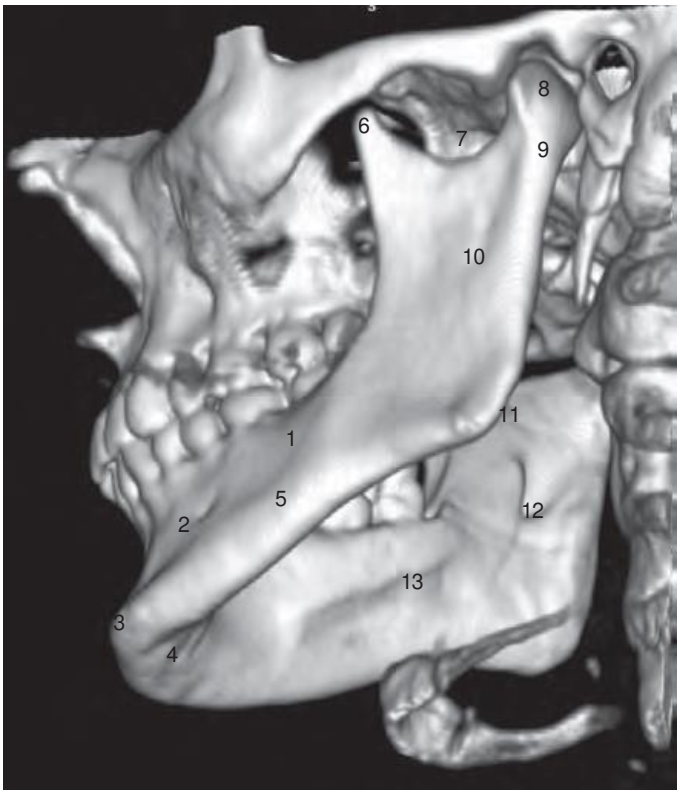

3D CT of mandible

1. Oblique line
2. Mental foramen
3. Mental protuberance
4. Mental tubercle
5. Body of mandible
6. Coronoid process
7. Mandibular notch
8. Condylar process
9. Neck
10. Ramus
11. Angle
12. Mandibular foramen
13. Mylohyoid line