Lec.5 & 6

Electrocardiography (ECG)

Physiology of the heart

Properties of Cardiac Cells	
Property	Ability
Automaticity	Generate electrical impulse independently, without involving the nervous system.
Excitability	Responds to electrical stimulation.
Conductivity	Passes or propagates electrical impulses from cell to cell.
Contractility	Shortens in response to electrical stimulation.

Electrical Conduction System of the heart

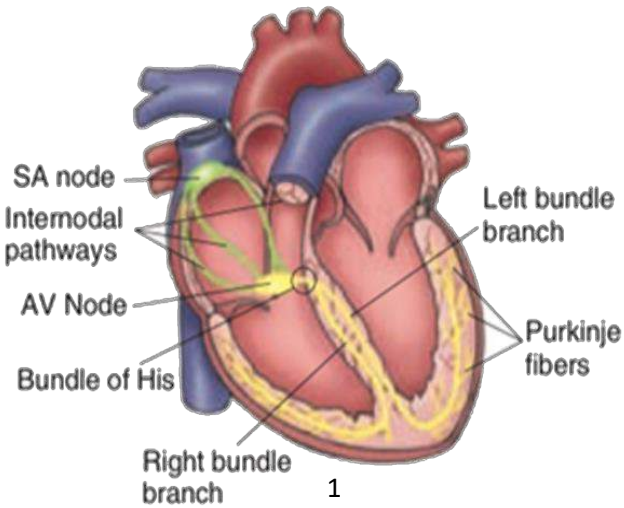

1

Conduction System Structures and Functions	
Structure	Function and Location
Sinoatrial (SA) Node	Dominant pacemaker of the heart, located in the upper portion of the right atrium. Intrinsic rate 60-100 bpm.
Internodal Pathway	Direct electrical impulses between SA and AV nodes.
Atrioventricular (AV) Node	Part of AV junctional tissue. Slows conduction, creating a slight delay before impulse reach ventricles. Intrinsic rate 40-60 bpm.
Bundle of His	Transmit impulses to bundle branches. Located below AV node.
Left Bundle Branch	Conduct impulses that lead to left ventricle.
Right Bundle Branch	Conduct impulses that lead to right ventricle.
Purkinje System	Network of fibers that spreads impulses rapidly throughout ventricular walls. Located at the terminals of bundle branches. Intrinsic rate 20-40 bpm.

Electrophysiology	
Action	Effect
Depolarization	The electrical charge of a cell is altered by a shift of electrolytes on either side of the cell membrane. This change stimulates muscle fiber to contract.
Repolarization	Chemical pumps re-established an internal negative charge as tl cells return to their resting state.

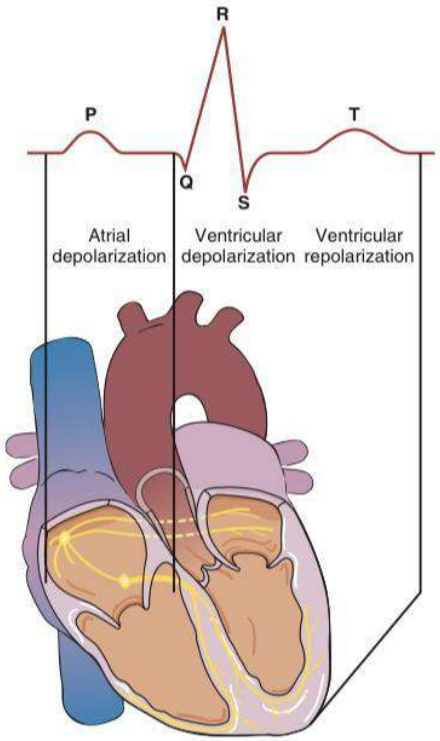

Depolarization and repolarization of the heart.

♥ **Clinical Tip:** Mechanical and electrical functions of the heart are influenced by proper electrolyte balance. Important components of this balance are sodium, calcium, potassium, and magnesium.

ECG

1- Electrocardiography is the process of producing an electrocardiogram (ECG or EKG , a recording of the heart's electrical activity through repeated cardiac cycles.

2- It is an electrogram of the heart which is a graph of voltage versus time of the electrical activity of the heart using electrodes placed on the skin.

3- These electrodes detect the small electrical changes that are a consequence of cardiac muscle depolarization followed by repolarization during each cardiac cycle (heartbeat).

Limb Leads

Electrodes are places on the right arm (RA), left arm (LA), right leg (RL), and left leg (LL). With only four electrodes, six leads are viewed.

Standard leads: I, II, III.

Augmented leads: aVR, aVL, aVF.

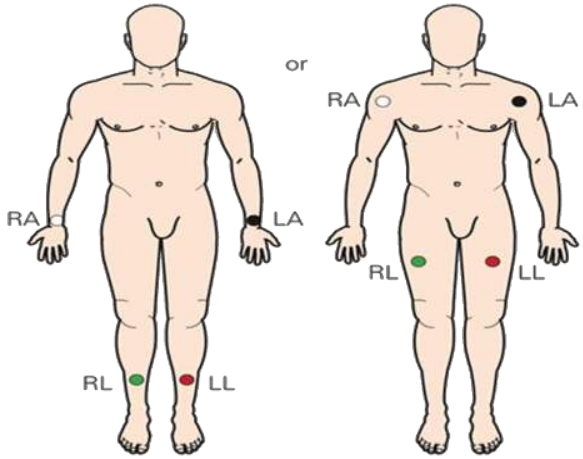

Standard Limb Leads

Elements of Standard Limb Leads			
Lead	Positive Electrode	Negative Electrode	View of Heart
I	LA	RA	Lateral
II	LL	RA	Inferior
III	LL	LA	Inferior

Leads I, II, and III are bipolar leads, which consist of two electrodes of opposite polarity (positive and negative). The third (ground) electrode minimizes electrical activity from other sources.

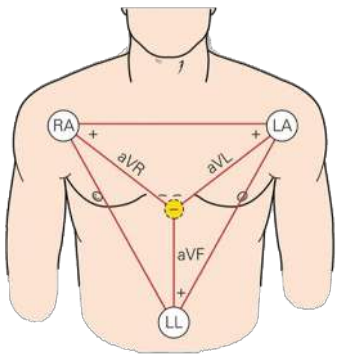

Augmented Limb Leads

Elements of Augmented Limb Leads		
Lead	Positive Electrode	View of Heart
aVR	RA	None
aVL	LA	Lateral
aVF	LL	Inferior

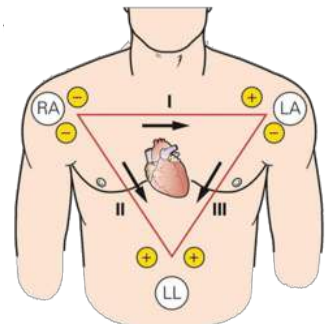

Leads aVR, aVL, and aVF are unipolar leads and consist of a single positive electrode and a reference point (with zero electrical potential) that lies in the center of the heart's electrical field.

Chest Leads

Elements of Chest Leads		
lead	Positive Electrode Placement	View of Heart
V1	4th Intercostal space to right of sternum	Septum
V2	4th Intercostal space to left of sternum	Septum
V3	Directly between V2 and V4	Anterior
V4	5th Intercostal space at left midclavicular line	Anterior
V5	Level with V4 at left anterior axillary line	Lateral
V6	Level with V5 at left midaxillary line	Lateral

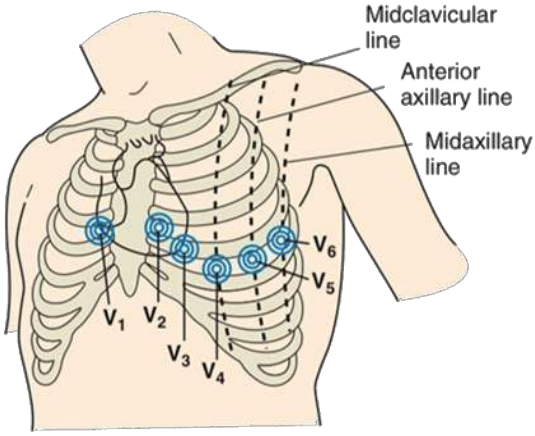

The Right-Sided 12-Lead ECG

- The limb leads are placed as usual but the chest leads are a mirror image of the standard 12-lead chest placement
- The ECG machine cannot recognize that the leads have been reversed. It will still print V1-V6 next to the tracing. Be sure to cross this out, and write the new leads positions on the ECG paper.

The Right-Sided 12-Lead ECG	
lead	Positive Electrode Placement
V_{1R}	4th Intercostal space to left of sternum
V_{2R}	4th Intercostal space to right of sternum
V_{3R}	Directly between V_{2R} and V_{4R}
V_{4R}	5th Intercostal space at right midclavicular line
V_{5R}	Level with V4 at right anterior axillary line
V_{6R}	Level with V5 at right midaxillary line

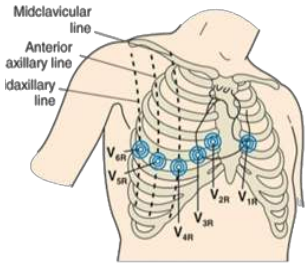

- Clinical Tip: patients with acute inferior MI should have right sided ECGs to assess for possible right ventricular infarction.

The 15-Lead ECG

Areas of the heart are not well visualized by the six chest leads include the wall of the right ventricle and the posterior wall of the left ventricle. A 15-lead ECG, which includes the standard 12 leads plus leads V_{4R}, V_8, and V_9, increase the chance of detecting an MI in these areas.

Chest Leads	Electrode Placement	View of Heart
V_{4R}	5th Intercostal space in right anterior midclavicular line	
V_8	Posterior 5th intercostal space in left midscapular line	
V_9	Directly between V_8 and spinal column at posterior 5th intercostal space	

- Clinical Tip: Use a 15-lead ECG when the 12-lead is normal but the history is still suggestive of an acute infarction.

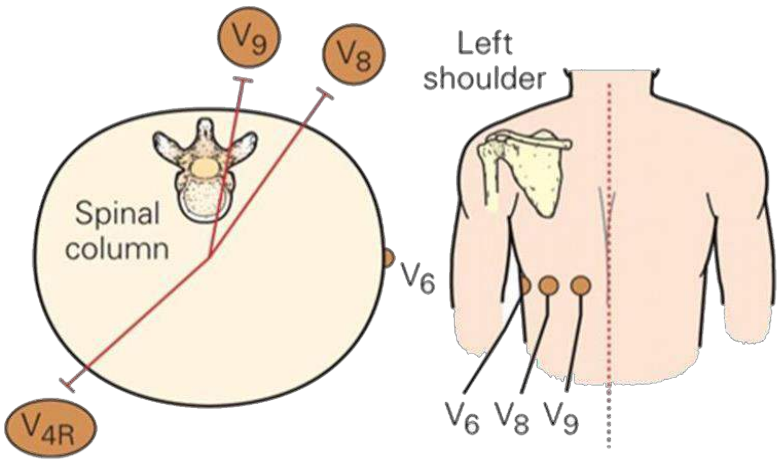

Components of an ECG Tracing

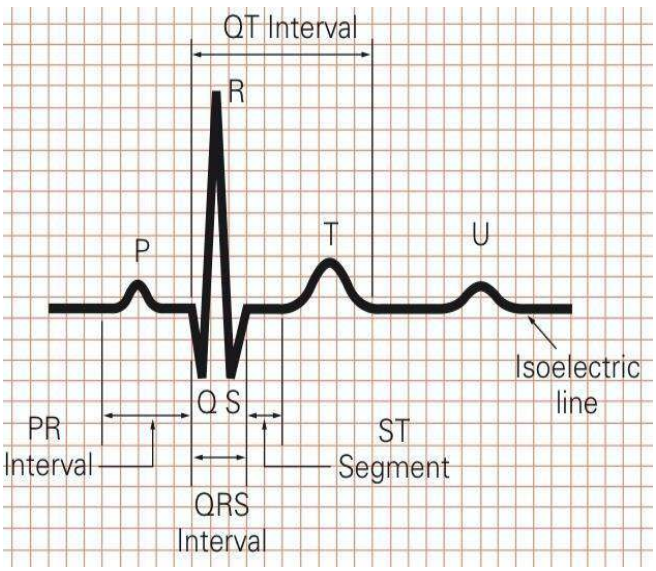

Components of an ECG

Electrical Components	
Deflection	Description
P Wave	First wave seen. Small rounded, upright (positive) wave indicating atrial depolarization (and contraction)
PR Interval	Distance between beginning of P wave and beginning of QRS complex. Measures time during which a depolarization wave travels from the atria to the ventricles.
QRS Interval	Three deflections following P wave. Indicates ventricular depolarization (and contraction). Q Wave: First negative deflection. R Wave: First positive deflection. S Wave: First negative deflection after R wave.
ST Segment	Distance between S wave and the beginning of T wave. Measures time between ventricular depolarization and beginning of repolarization.
T Wave	Rounded upright (positive) wave following QRS. Represent ventricular repolarization.
QT Interval	Measured from the beginning of QRS to the end of T wave. Represents total ventricular activity.
U Wave	Small rounded upright wave following T wave. Most easily seen with slow HR. Represents repolarization of Purkinje fibers

Recording of the ECG

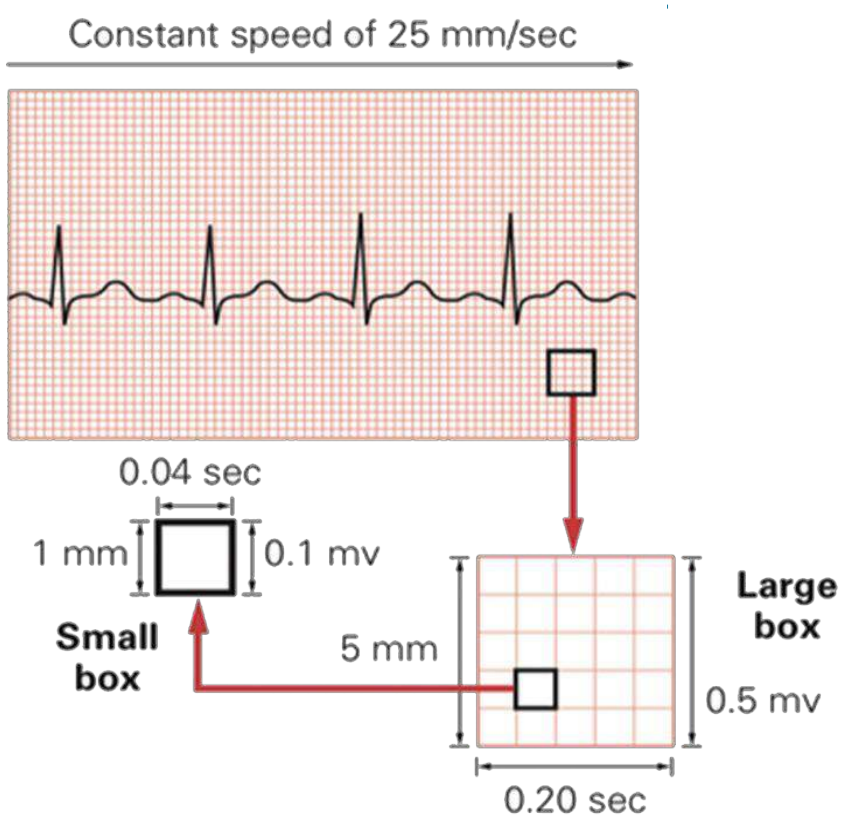

Reporting an ECG recording

The reporting of an ECG recording is best done in a methodical manner to ensure that the report is comprehensive and doesn't overlook any potentially important details

Patient Data

Begin by checking key information on the ECG and/or request form relating to the patient:

- Patient name
- Date of birth
- Identification number (e.g. hospital number)
- Reason for the request
- Relevant past medical history
- Relevant medication

Technical Data

- Date and time of recording
- Paper speed and calibration
- Technical quality
- Any atypical settings
- Additional leads (e.g. posterior leads, right-sided chest leads)
- Physiological manoeuvres (e.g., ECG recorded during deep inspiration
- Diagnostic or therapeutic manoeuvres (e.g. ECG recorded during carotid sinus massage)

Standerd ECG

ECGs are normally printed on a grid. The horizontal axis represents time and the vertical axis represents voltage. The standard values on this grid are shown in the adjacent image at
25mm/sec:

A small box is 1 mm × 1 mm and represents 0.1 mV × 0.04 seconds.
A large box is 5 mm × 5 mm and represents 0.5 mV × 0.20 seconds.

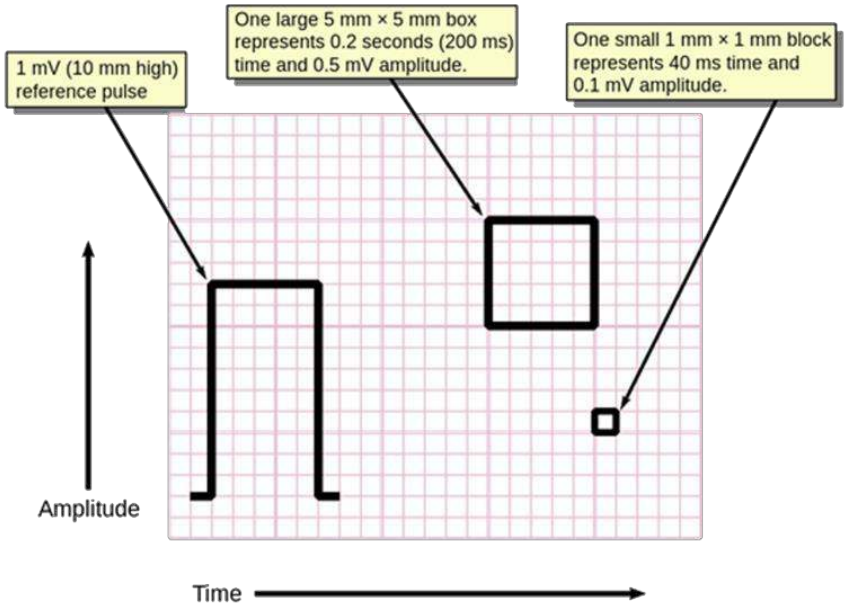

ECG Fundamentals

Next, report on the fundamental features of the ECG recording itself, namely:

- Rate
- Rhythm
  - Supraventricular
  - Ventricular
  - Conduction problems
- Axis

ECG Details

Next, review the individual features of the ECG using a step-by-step approach. Describe:

- P wave
- PR interval
- Q wave
- QRS complex
- ST segment
- T wave
- QT interval
- U wave

Heart Rate

Methods for Calculating Heart Rate:

Method 1: Count Large Boxes

Regular rhythms can be quickly determined by counting the number of large graph boxes between two R waves.

That number is divided into 300 to calculate bpm.

The rates for the first one to six large boxes can be easily memorized.

Remember: 60 sec/min divided by 0.20 sec/large box 300 large boxes/min.

Method 2: Count Small Boxes

Sometimes it is necessary to count the number of small boxes between two R waves for fast heart rates.

That number is divided into 1500 to calculate bpm.

Remember: 60 sec/min divided by 0.04 sec/small box 1500 small boxes/min.

Examples: If there are six small boxes between two R waves: 1500/6 250 bpm.

If there are ten small boxes between two R waves: 1500/10 150 bpm

Methods 1 and 2 for Calculating Heart Rate

Methods 1 and 2 for Calculating Heart Rate			
Number of Large Boxes	Rate/Min	Number of Small Boxes	Rate/Min
1	300	2	750
2	150	3	500
3	100	4	375
4	75	5	300
5	60	6	250
6	50	7	214
7	43	8	186
8	38	9	167
9	33	10	150
10	30	11	136
11	27	12	125
12	25	13	115
13	23	14	107
14	21	15	100
15	20	16	94

Method 3: Six-Second ECG Rhythm Strip

The best method for measuring irregular rates with varying R-R intervals is to count the number of R waves in a 6-sec strip and multiply by 10

This gives the average number of bpm

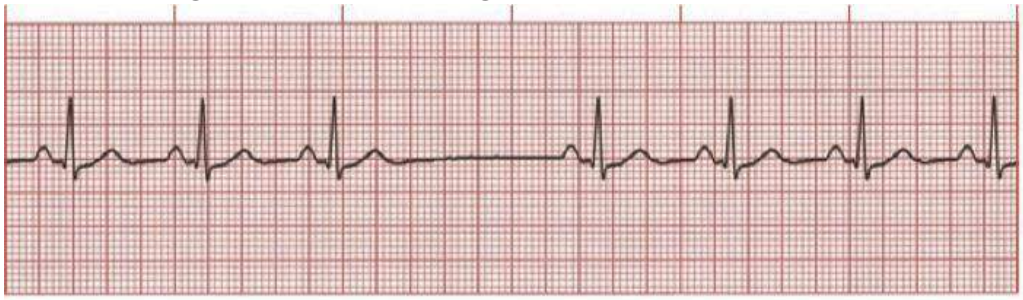

Using 6-sec ECG rhythm strip to calculate heart rate. Formula: 7 × 10 = 70 bpm

Heart Rate

Once you have measured the heart rate, you need to decide whether it is normalor abnormal.

As a general rule, a heart rate between 60 and 100/min is normal.

If the rate is below 60/min, the patient is said to be bradycardic.

With a heart rate above 100/min, the patient is tachycardic.

Therefore, the two questions you need to ask about heart rate are:

1. Is the heart rate below 60/min?
2. Is the heart rate above 100/min?

Is The Heart Rate Below 60/Min?

Bradycardia is defined as a heart rate below 60/min. Identification of the cardiac rhythm and any conduction disturbances is essential, and this is discussed in the following chapters.

Problems to consider in the bradycardic patient are:

1. Sinus bradycardia
2. Sick sinus syndrome

Management of patient with bradycardia

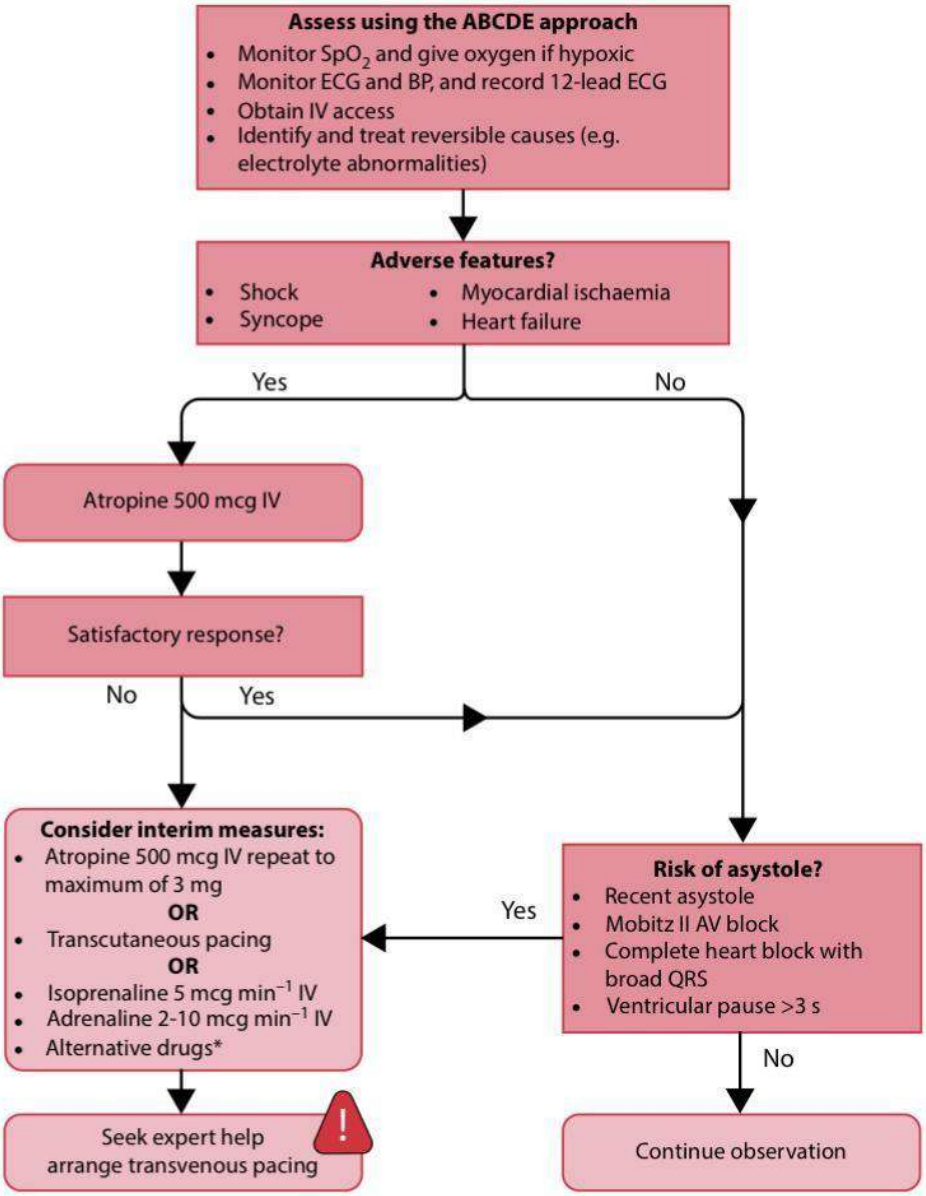

*** Alternatives include:**
- Aminophylline
- Dopamine
- Glucagon (if bradycardia is caused by beta-blocker or calcium channel blocker)
- Glycopyrrolate (may be used instead of atropine)

Is The Heart Rate Above 100/Min?

Tachycardia is defined as a heart rate above 100/m

When Begin the process of identification by checking whether the QRS complexes are:

1. Narrow (<3 small squares)
2. Broad (>3 small squares)

Narrow-complex tachycardias

Always arise from above the ventricles – that is, they are supraventricular in origin.

The possibilities are:

- Sinus tachycardia
- Atrial tachycardia
- Atrial flutter
- Atrial fibrillation
- AV re-entry tachycardia (AVRT)
- AV nodal re-entry tachycardia (AVNRT)

Broad-complex tachycardia:

- Ventricular tachycardia
- Accelerated idioventricular rhythm
- Torsade's de pointes

Broad-complex tachycardia should also make you think of ventricular arrhythmias.

Management of tachycardia depends on the underlying rhythm

1. The first step, as with managing a bradycardia, is to assess the urgency of the situation – in the peri-arrest situation, use the ABCDE approach and assess the patient for adverse features
2. Clues to the nature of the arrhythmia may be found in the patient's history.
3. Ask the patient about:
   - How any palpitations start and stop (sudden or gradual)
   - Whether there are any situations in which they are more likely to happen (e.g. during exercise, lying quietly in bed)
   - How long they last.
   - Whether there are any associated symptoms (dizziness, syncope, falls, fatigue, breathlessness and chest pain)
   - Also ask the patient to 'tap out' how the palpitations feel – this will give you clues about the rate or slow) and rhythm (regular or irregular).
4. Also enquire about symptoms of related disorders (e.g. hyperthyroidism) and obtain a list of current medications.
5. Check for any drugs (e.g., salbutamol) that can increase the heart rate (positively chronotropic)

6. Do not forget to ask about caffeine intake (e.g., coffee, tea and energy drinks)
7. A thorough examination is always important, looking for evidence of hemodynamic disturbance (hypotension, cardiac failure and poor peripheral perfusion) and coexistent disorders (e.g., thyroid goiter)
8. Use the history, examination and further investigations (e.g., plasma electrolytes, thyroid function tests) to reach a diagnosis.

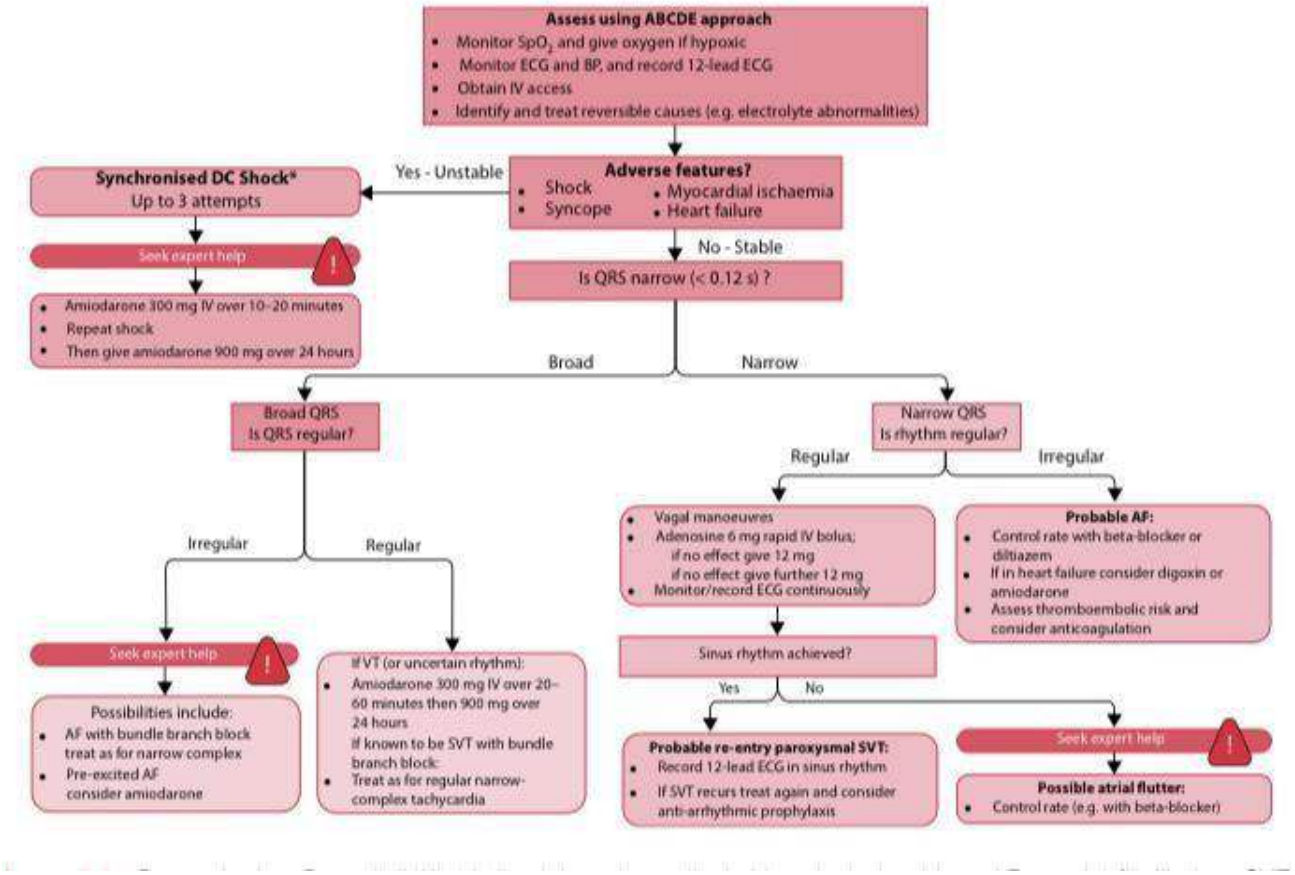

An Approach to Heart Rhythms

To identify the cardiac rhythm with confidence you need to begin with a rhythm strip - a prolonged recording of the ECG from just one lead. Most ECG machines automatically include a rhythm strip at the bottom of a 12-lead ECG

The rhythm strip:

The standard lead used for the rhythm strip is lead II, but alternative leads can be selected if it helps to clarify the cardiac rhythm

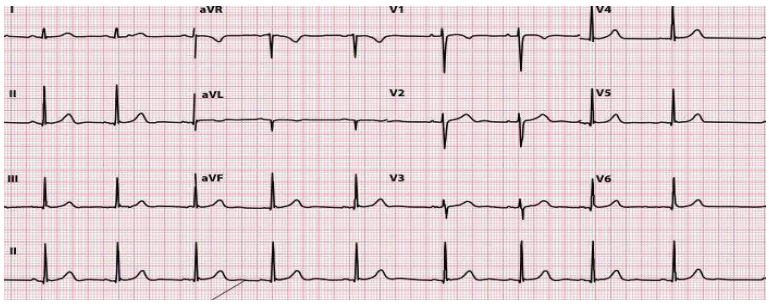

Identifying The Cardiac Rhythm

When you analyze the cardiac rhythm, always keep in mind the two primary questions that you are trying to answer:

Where does the impulse arise from?

- Sinoatrial (SA) node
- Atria
- Atrioventricular (AV) junction
- Ventricles

How is the impulse conducted?

- Normal conduction
- Impaired conduction
- Accelerated conduction (e.g. Wolff-Parkinson-White [WPW] syndrome)

The following seven questions will help you to narrow down the possible diagnoses:

1. How is the patient?
2. Is ventricular activity present?
3. What is the ventricular rate?
4. Is the ventricular rhythm regular or irregular?
5. Is the QRS complex width normal or broad?
6. Is atrial activity present?
7. How are atrial activity and ventricular activity related?

1- How is the patient?

The clinical context will also help you decide how urgently to deal with an arrhythmia. When assessing a 'sick' patient, use the ABCDE approach:

Airway: Check for any evidence of airway obstruction
Breathing: Assess the patient's breathing, paying attention to respiratory rate, chest percussion and auscultation, and oxygenation
Circulation: Assess the patient's circulation, including pulse rate, blood pressure and capillary refill time
Disability: Assess level of consciousness and neurological status
Exposure: Ensure adequate exposure to permit a full examination. As you assess a patient with an arrhythmia, be alert for 'adverse features' which indicate hemodynamic instability:
Shock: As evidenced by hypotension (systolic blood pressure <90 mmHg), clamminess, sweating, pallor, confusion or reduced conscious level.
Syncope: As a consequence of cerebral hypoperfusion.
Myocardial ischemia: Indicated by ischemic chest pain and/or ischemic ECG changes
Heart failure: Pulmonary oedema, elevated jugular venous pressure, peripheral/sacral oedema.

2- Is Ventricular Activity Present ?

Look at the ECG as a whole for the presence of electrical activity. If there is none, Assess:

The patient (do they have a pulse?)
The electrodes (has something become disconnected?)
The gain setting (is the gain setting on the monitor too low?)

If QRS complexes are present, move on to the next question.

3- What Is the Ventricular Rate?

Ventricular activity is represented on the ECG by QRS complexes. Once you have calculated the ventricular rate, you will be able to classify the rhythm as:

Bradycardia (<60 beats/min)24
Normal (60-100 beats/min)
Tachycardia (>100 beats/min)

4- Is The Ventricular Rhythm Regular or Irregular?

Having determined the ventricular rate, go on to assess regularity. Look at the spacing between QRS complexes - is it the same throughout the rhythm strip?

Irregularity can be subtle, so it is useful to measure the distance between each QRS complex.

One way to do this is to place a piece of paper alongside the rhythm strip and make a mark on it next to every QRS complex. By moving the marked paper up and down along the rhythm strip, you can soon see if the gaps between the QRS complexes are the same or vary. Once you have assessed the regularity, you will be able to classify the ventricular rhythm as:

Regular (equal spacing between QRS complexes)
Irregular (variable spacing between QRS complexes)

Table 6.2 Regular and irregular cardiac rhythms

- Regular rhythms
  - Sinus rhythm
  - Sinus bradycardia
  - Sinus tachycardia
  - Atrial flutter (if constant AV block, e.g. 2:1)
  - Atrial tachycardia
  - AV re-entry tachycardia (AVRT)
  - AV nodal re-entry tachycardia (AVNRT)
  - Accelerated idioventricular rhythm
  - Monomorphic ventricular tachycardia (VT)
  - Polymorphic ventricular tachycardia (torsades de pointes)
  - Third-degree AV block (if regular escape rhythm)
- Irregular rhythms
  - Sinus arrhythmia (rate varies with respiration)
  - Ectopic beats (atrial, junctional, ventricular)
  - Atrial fibrillation
  - Atrial flutter (if variable AV block)
  - Sinus arrest and SA block
  - Mobitz type I second-degree AV block
  - Mobitz type II second-degree AV block

5- Is The QRS Complex Width Normal or Broad?

By answering this question, you will have narrowed down the origin of the impulse to one half of the heart.

This allows us to use the width of the QRS complex to try to determine how the ventricles were depolarized.

If the QRS complex is narrow (<3 small squares), the ventricles must have been rapidly depolarized by an impulse that came through the AV node - the only way into the His-Purkinje system. The patient is then said to have a supraventricular rhythm (arising from above the ventricles).

If the QRS complex is broad (>3 small squares), there are two possible explanations.

1. The impulse may have arisen from within the ventricles and thus been unable to travel via the HisPurkinje system (ventricular rhythm).
2. The impulse may have arisen from above the ventricles but not been able to use all the HisPurkinje system because of a conduction problem (supraventricular rhythm with aberrant conduction).

6- Is Atrial Activity Present?

Presence of P waves indicates atrial depolarization. However, it does not mean that the depolarization necessarily started at the SA node. P waves will appear during atrial depolarization regardless of where it originated.

7- How Are Atrial Activity and Ventricular Activity Related?

If every QRS complex is associated with a P wave, this indicates that the atria and ventricles are being activated by a common source. This is usually, but not necessarily, the SA node (e.g. AV junctional rhythms will also depolarize both atria and ventricles). If there are more P waves than QRS complexes, conduction between atria and ventricles is being either partly blocked (with only some impulses getting through) or completely blocked (with the ventricles having developed their own escape rhythm). More QRS complexes than P waves indicates AV dissociation, with the ventricles operating independently of the atria and at a higher rate.

Table 6.3 Broad-complex versus narrow-complex rhythms

Rhythm origin	Rhythm conduction	QRS complex
Supraventricular	Normal	Narrow
Supraventricular	Aberrant (e.g. bundle branch block)	Broad
Ventricular	Myocyte to myocyte	Broad

Note: Only supraventricular rhythms with normal conduction can gain access to the His–Purkinje system to rapidly depolarize the ventricles.

Supraventricular Rhythms

Supraventricular rhythms are those which arise above the level of the ventricles. The supraventricular rhythms we will consider are:

Sinus rhythm
Sinus arrhythmia
Sinus bradycardia

Sinus tachycardia
Sick sinus syndrome
Atrial ectopic beats
Atrial fibrillation
Atrial flutter
Atrial tachycardia
Focal atrial tachycardia
Multifocal atrial tachycardia
Atrioventricular re-entry tachycardia (AVRT)
Atrioventricular nodal re-entry tachycardia (AVNRT)

1- Sinus Rhythm

Sinus rhythm is the normal cardiac rhythm, in which the SA node acts as the natural pacemaker, discharging at a rate of 60-100/min
The characteristic features of sinus rhythm are:

Heart rate is 60-100/min
P wave morphology is normal (e.g. upright in lead II and inverted in lead aVR)
Every P wave is followed by a QRS complex

Normal SINUS RHYTHM



Figure 7.1 Normal sinus rhythm.

Key point: • The heart rate is 75/min, the P waves are upright (lead II) and every P wave is followed by a QRS complex.

2- Sinus Arrhythmia

- Sinus arrhythmia is the variation in heart rate that is seen during inspiration and expiration. The characteristic features of sinus arrhythmia are:
- The heart rate varies with respiration, with the difference between the longest and shortest P-P intervals being >0.12 s (3 small squares)

- During inspiration, the heart rate increases as a reflex response to the increased volume of blood returning to the heart (which triggers baroreceptors that inhibit vagal tone)
- During expiration, the heart rate decreases as a reflex response to the decreased volume of blood returning to the heart (vagal tone is no longer inhibited)
- P wave morphology is normal (e.g. upright in lead II and inverted in lead aVR)
- Every P wave is followed by a QRS complex

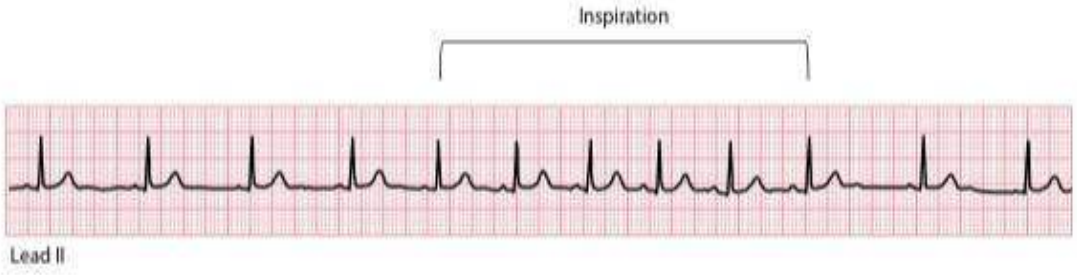

gure 7.2 Physiological sinus arrhythmia.

y point: • The heart rate increases during inspiration, the P waves are upright (lead II) and every P wave is followed by a QRS complex.

3- Sinus Bradycardia

Sinus bradycardia is sinus rhythm with a heart rate of less than 60/min. The characteristic features of sinus bradycardia are:

- The heart rate is less than 60/min
- P wave morphology is normal (e.g. upright in lead II and inverted in lead aVR).
- Every P wave is followed by a QRS complex

Always consider the following possible causes:

1. Drugs (e.g. digoxin, beta blockers - including beta blocker eye drops)
2. Ischemic heart disease and myocardial infarction
3. Hypothyroidism
4. Hypothermia
5. Electrolyte abnormalities
6. Obstructive jaundice
7. Uremia
8. Raised intracranial pressure
9. Sick sinus syndrome

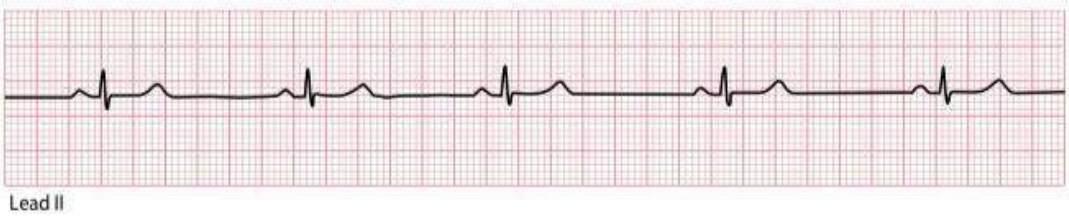

Figure 7.3 Sinus bradycardia.

Key point: • The heart rate is 46/min, the P waves are upright (lead II) and every P wave is followed by a QRS comple

4- Sinus Tachycardia

Sinus tachycardia is sinus rhythm with a heart rate of greater than 100/min. The characteristic features of sinus tachycardia are:

- The heart rate is greater than 100/min
- P wave morphology is normal (e.g. upright in lead II and inverted in lead aVR)
- Every P wave is followed by a QRS complex

Always consider the following causes as well:

1. Drugs, e.g. adrenaline, atropine, salbutamol (do not forget inhalers and nebulizers), caffeine, and alcohol
2. Ischemic heart disease and acute myocardial infarction
3. Heart failure
4. Pulmonary embolism
5. Fluid loss
6. Anemia
7. Hyperthyroidism

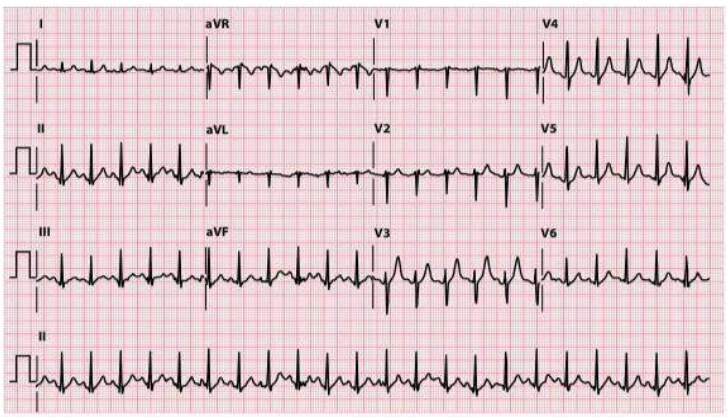

Figure 7.4 Sinus tachycardia.

Key point: • The heart rate is 136/min, the P waves have a normal orientation in each lead, and every P wave is followed by a QRS complex.

5- Atrial Ectopic Beats

Atrial ectopic beats are also called atrial extrasystoles, atrial premature complexes (APCs), atrial premature beats (APBS) or premature atrial contractions (PACs).

Atrial ectopic beats are identified by a P wave that appears earlier than expected and has a different shape to the normal P waves. Although atrial ectopic beats will usually be conducted to the ventricles and give rise to a QRS complex.

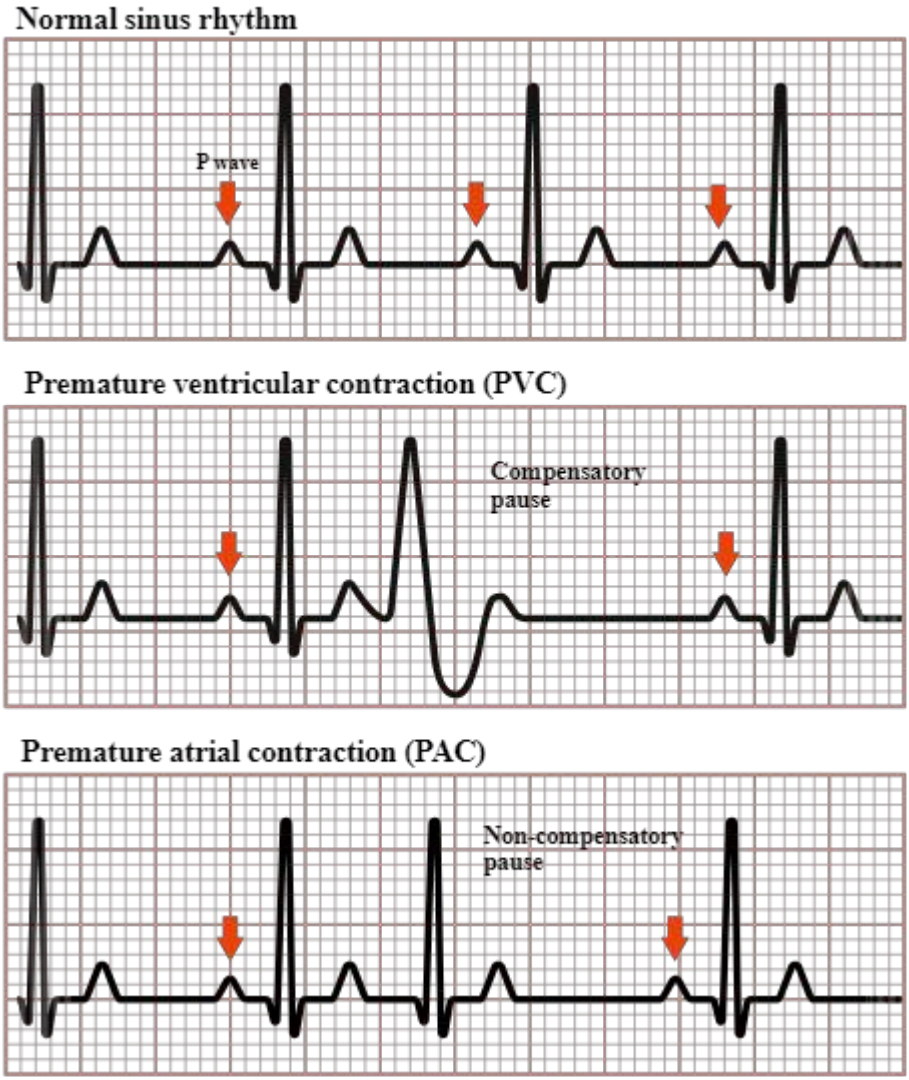

6- Atrial Fibrillation

- The basis of AF is rapid
- No P waves are seen
- ECG baseline consists of low-amplitude oscillations (fibrillation or f waves).
- Although 400-600 impulses reach the AV node every minute, only some will be transmitted to the ventricles.

- The ventricular rate is typically fast (100-180/min), although the rate can be normal or even slow. Transmission of the atrial impulses through the AV note is erratic, making the ventricular (QRS complex) rhythm 'irregularly irregular'.

Five categories of AF are recognized:

1. First-diagnosed AF: Namely, patients presenting in AF for the first time.
2. Paroxysmal AF: Self-terminating episodes of AF, typically lasting <48 hours although they can last up to 7 days
3. Persistent AF: An episode of continuous AF lasting >7 days or requiring cardioversion
4. Long-standing persistent AF: Where AF has been present for at least one year, but there is still an aim to restore sinus rhythm
5. Permanent AF: Continuous AF where the arrhythmia is 'accepted' and there is no plan to restore sinus rhythm

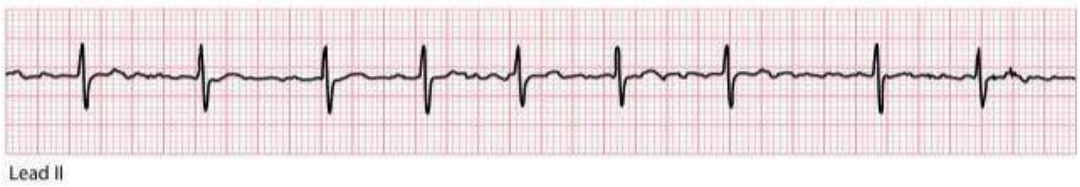

Figure 7.7 Atrial fibrillation.
Key point: • The ventricular rhythm is irregularly irregular, with an absence of distinct P waves.

Key issues to consider in managing patients with AF are:

- Reducing stroke risk
- Ventricular rate control
- Rhythm control

Reducing stroke risk

• The presence of AF increases a patient's stroke risk fivefold and one in five strokes occurs as a result of
• Strokes that occur in AF are more likely to be disabling or fatal.
• Reducing stroke risk in AF is therefore important, and the approach can be summarized as
follows:
✓ For patients with valvular AF (including rheumatic valve disease and prosthetic valves),
anticoagulation is recommended for all, unless there are contraindications

✓ For those with non-valvular AF, anticoagulation is recommended for all, except in those
patients who are at low risk (aged <65 years and lone AF), or with contraindications
Ventricular rate control
• Commonly used drugs for ventricular rate control include beta blockers and nondihydropyridine calcium channel blockers (verapamil or diltiazem).
• Digoxin is good for rate control at rest but is poor at rate control during exercise.
• Although amiodarone is effective for rate control,
• Amiodarone also carries the risk of chemical cardioversion to sinus rhythm, which could
lead to thromboembolism unless the patient has been anticoagulated, where appropriate.
• Rate control is the preferred strategy (instead of rhythm control) in elderly patients and
those with minimal symptoms
• aiming for a resting ventricular rate <110/min. If patients remain symptomatic, a stricter rate
control strategy can be used, aiming for a resting heart rate <80/min (with a heart rate
<110/min during moderate exercise).
• If drug therapy cannot attain satisfactory rate control in AF, and restoration of sinus rhythm
cannot be achieved, an alternative strategy is to undertake ablation of the AV node plus
permanent pacing.

Rhythm control

Patients with symptomatic AF despite adequate ventricular rate control should be considered for a
rhythm control strategy, where the aim is to restore and maintain sinus rhythm.

Table 7.1 EHRA classification of AF symptoms

EHRA class	Severity of AF symptoms
I	Asymptomatic
II	Mild symptoms (not affecting daily activities)
III	Severe symptoms (affecting daily activities)
IV	Disabling symptoms (unable to undertake daily activities)

Cardioverting to sinus rhythm

• For those with recent onset AF and who are hemodynamically unstable, urgent electrical
cardioversion is advised.
• Similarly, patients who e stable and who present within 48 hours of the onset of AF can
have urgent electrical cardioversion
• In both cases, anticoagulant cover using intravenous unfractionated heparin is advised
initially, followed by a minimum of 4 weeks' oral anticoagulation (unless the patient is aged <65 years and has had 'lone' AF).

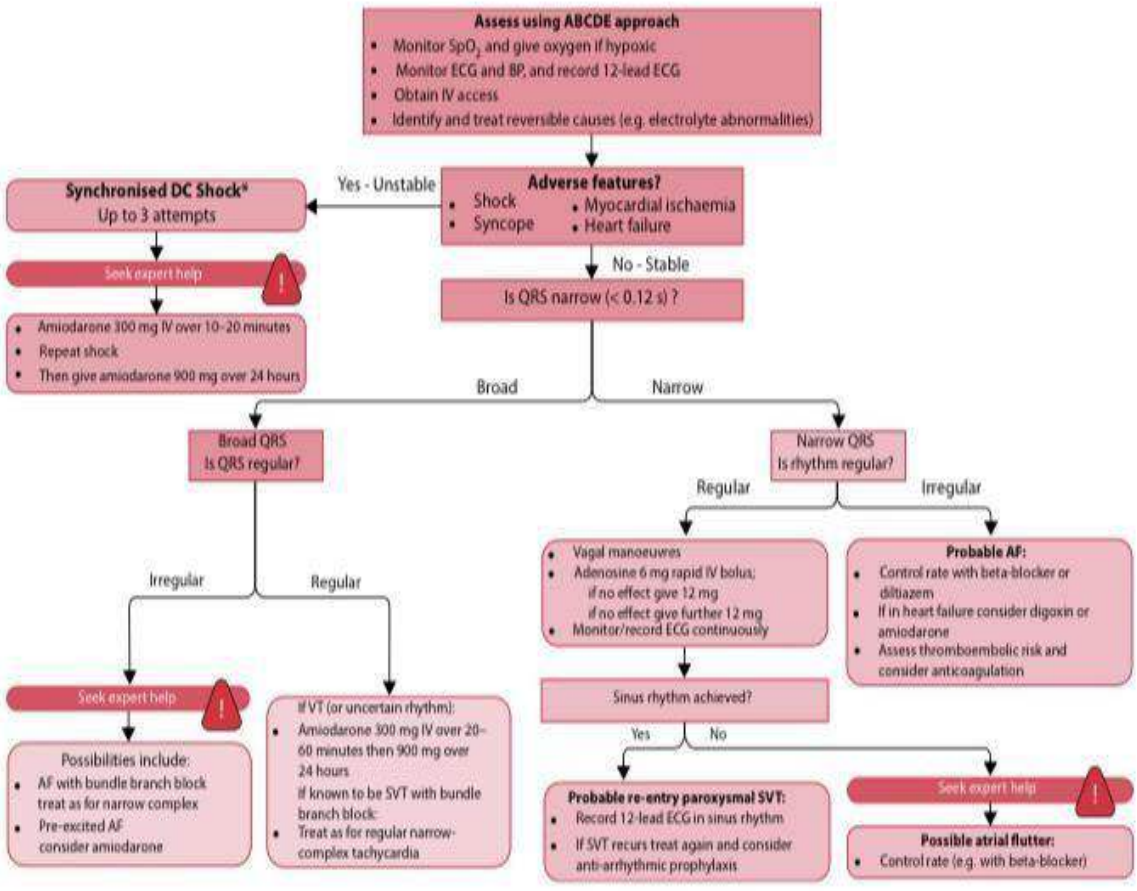

7- Atrial Flutter

• In atrial flutter the atrial rate is usually 250-350/min
• and often almost exactly 300/min.
• The AV node cannot normally keep up with such a high atrial rate and AV block occurs.
• This is most commonly 2:1 block, where only alternate atrial impulses get through the AV node to initiate a QRS complex, although 3:1, 4:1 or variable degrees of block are also seen.
• Thus, the ventricular rate is less than the atrial rate, and is often 150, 100 or 75/min. You should always suspect atrial flutter with 2:1 block when a patient has a regular tachycardia with a ventricular rate of about 150/min.
• The rapid atrial rate gives a characteristic 'sawtooth' appearance to the baseline of the ECG, made up of flutter or 'F' waves.

The rapid atrial rate gives a characteristic 'sawtooth' appearance to the baseline of the ECG, made up of flutter or 'F' waves. The characteristic features of atrial flutter are:

• Atrial rate around 300/min
• 'Sawtooth baseline
• AV block (commonly 2:1, but can be 3:1, 4:1 or variable)

Atrial flutter carries a risk of thromboembolism, and patients with atrial flutter are usually assessed for anticoagulant therapy according to the same guidelines as those used in AF (see earlier).

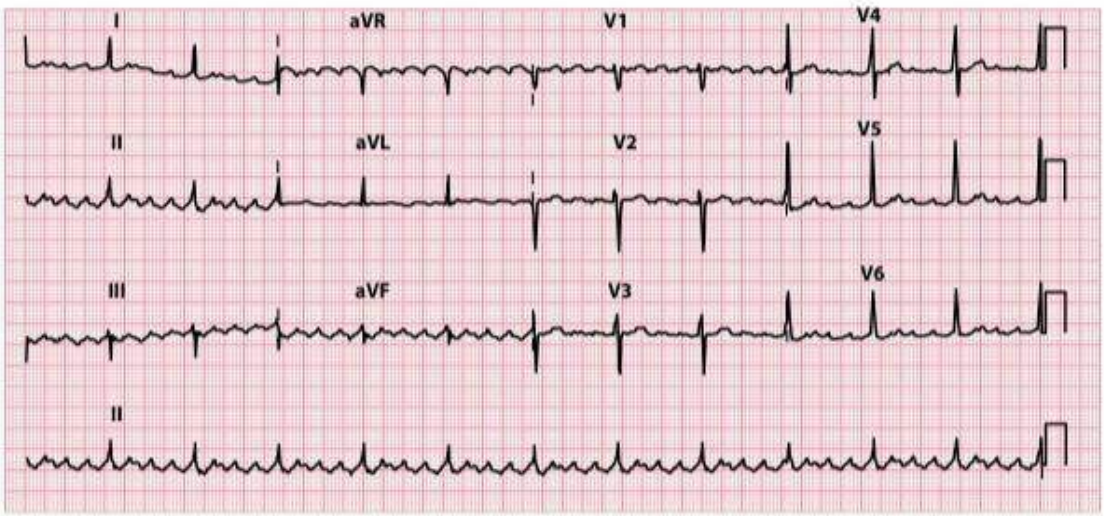

Figure 7.9 Atrial flutter.

Key point: • There is a 'sawtooth' pattern of atrial activity, with an atrial rate of 288/min and a ventricular rate of 72/ in (indicating 4:1 AV block).

Treatment of Atrial Flutter

Medicines for the treatment of atrial flutter include:

- Medicines to slow down your heart rate: Calcium channel blockers and beta-blockers.
- Medicines to stop the abnormal rhythm: Antiarrhythmic drugs.

Procedures:

- Procedures to treat atrial flutter include:
  - Cardioversion via electrical shock.
  - Catheter ablation, a procedure a provider can use to destroy the tissue that's creating abnormal signals.
  - Temporary change in your pacemaker or implantable cardioverter defibrillator (ICD) setting.

Ventricular fibrillation

• ECG show irregular waves varying morphology and amplitude



Causes

✓ IHD

✓ Antiarrhythmic drugs

✓ Severe hypoxia

Management

• DC shock: immediate non synchronized DC shock at 200 J if ineffective repeated at
200-360 J

• IF DC shock fails start basic and advanced life support

• Drugs

✓ Amiodarone id drug of choice

✓ Others: lidocaine procainamide

MCQ test

1- Conduction system structures and its functions (all true except one)
   a) SA node=pacemaker of the heart
   b) Internodal pathway=direct impulse between SA and AV node
   c) AV node=slows impulse
   d) His bundle=transmits impulses between branches
   e) Left bundle branch=conduct impulses that lead to right ventricles

2- Leads of ECG (all true except one)
   a) Lead I=view of lateral heart
   b) Lead II=view of inferior heart
   c) Lead III=view of posterior of heart
   d) aVL= view lateral of the heart
   e) aVF= view inferior of the heart

3- the characteristic features of atrial flutter are (all true except one)
   a) Atrial rate around 300/min
   b) Sawtooth baseline
   c) carries a risk of thromboembolism
   d) treated by Cardioversion via electrical shock.
   e) No response to calcium channel blockers

4- Atrial Fibrillation (all true except one)
   a) The basis of AF is rapid
   b) No P waves are seen
   c) ECG baseline consists of low-amplitude oscillations (fibrillation or f waves).
   d) The ventricular rate is typically fast (100-180/min)
   e) No risk for thromboembolic events

5- Causes of sinus tachycardia (all true except one)42
   a) salbutamol
   b) acute myocardial infarction
   c) Heart failure
   d) Pulmonary embolism
   e) Fluid overload

6- Narrow complex tachycardia (all true except one)
    a) Sinus tachycardia
    b) Atrial tachycardia
    c) Atrial flutter
    d) Atrial fibrillation
    e) Ventricle tachycardia
7- Located at 5th. Intercostal space at left midclavicular line
    a) V1
    b) V2
    c) V4
    d) V5
    e) V6
8- All the following drugs are used in management of bradycardia except one
    a) Glycopyrrolate
    b) Isoprenaline
    c) Atropine
    d) Glucagon
    e) Atenolol
9- Ventricular fibrillation (all true except one)
    a) Irregular waves
    b) Caused by sever hypotension
    c) Treated by DC shock43
    d) Alternative management is amiodarone
    e) varying morphology and amplitude.
10- Rate control drugs (all true except one)
    a) beta blockers
    b) verapamil
    c) diltiazem).
    d) atropine
    e) amiodarone
11- Dominant pacemaker of the heart is
    a) AV node
    b) SA node
    c) Purkinje fiber
    d) Bundle of His
    e) None of the above1