Introduction of Anatomy

Anatomy First
Stage

Dr Hawraa kareem

The Human Body – An Orientation

- Anatomy – study of the structure and shape of the body and its parts (and how those structures relate to each other).
- Anatomy:
  - »Tomy- "to cut"
  - »Ana- "apart"

- Anatomy is a broad study with many subdivisions.

Anatomy – Levels of Study

- Gross Anatomy
  - Large structures
  - Easily observable with the naked eye
  - Ex: the heart, the stomach

Anatomy – Levels of Study

- Methods of studying **Gross Anatomy**:

1. **Regional anatomy:** studying **specific regions of the body** such as the head or leg (muscles, bone, blood vessels, and nerves).
2. **Systemic anatomy:** studying the **different systems of the body** such as the circulatory, reproductive, respiratory and digestive system.

- **Microscopic Anatomy**
  - Very small structures
  - Can only be

viewed with
a microscope

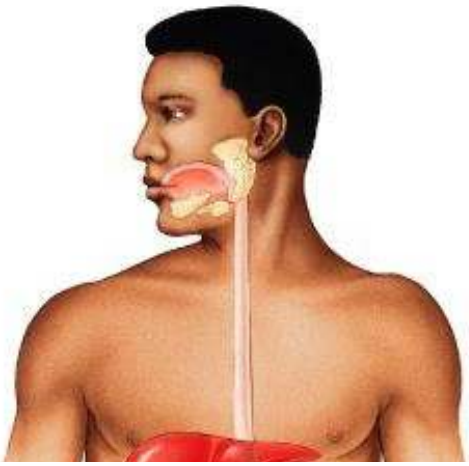

– Histology (body tissues): light
– Cytology (cells): electron mic

Anatomy – L

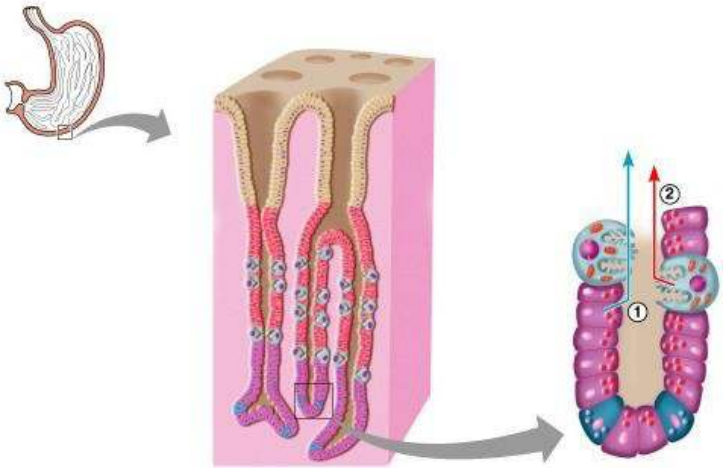

Figure 14.4

Levels of Structural Organization

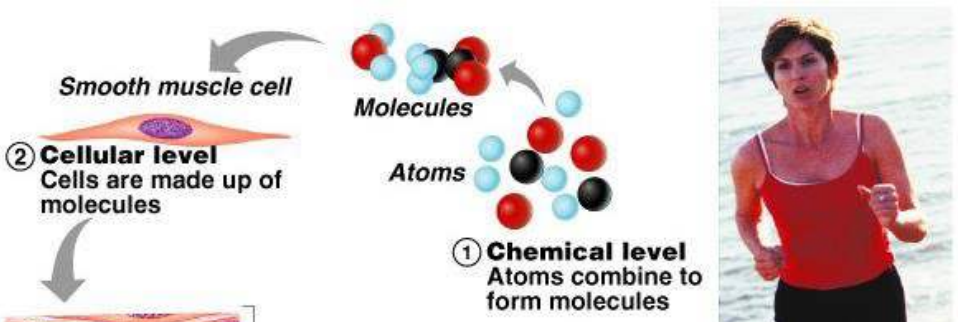

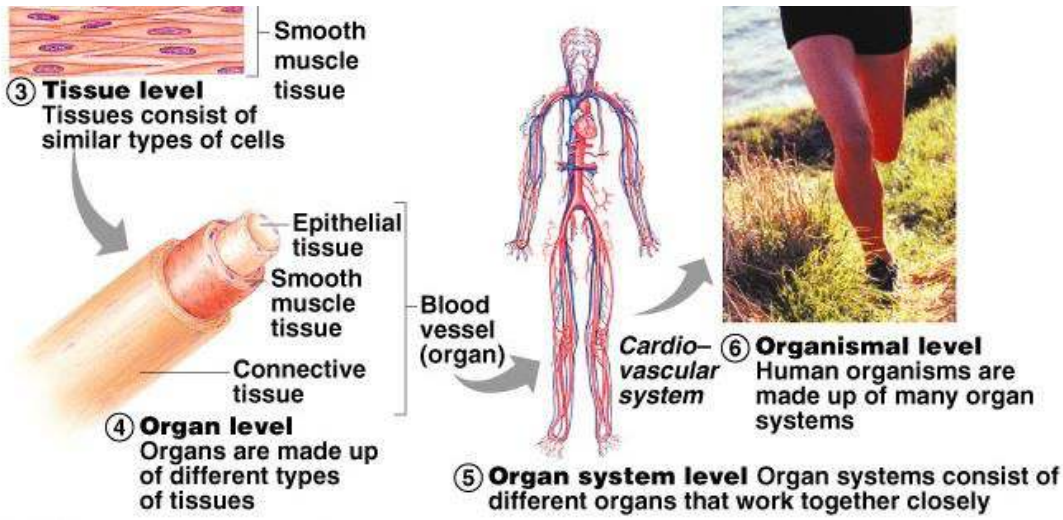

Figure 1.1

- A … an systems … organism

5

- Groups of cells that perform a function are **tissues**

Levels of Organization

- Groups of tissues that perform a function are **organs**
- Groups of organs that perform a function are **organ systems**.

The Language of Anatomy

- **Special terminology** is used to prevent misunderstanding

6

- **Anatomical Position**:
  - Body upright
  - Feet flat & parallel
  - Arms at sides

– Palms forward

– Thumbs point away from the body

Term	Definition	Illustration	Example
Superior (cranial or cephalad)	Toward the head end or upper part of a structure or the body; above	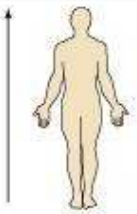	The forehead is superior to the nose.
Inferior (caudal)†	Away from the head end or toward the lower part of a structure or the body; below	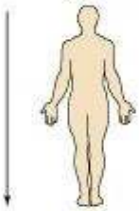	The navel is inferior to the breastbone.
Anterior (ventral)*	Toward or at the front of the body; in front of		The breastbone is anterior to the spine.
Posterior (dorsal)*	Toward or at the backside of the body; behind		The heart is posterior to the breastbone.

†The term *caudal*, literally "toward the tail," is synonymous with *inferior* only to the inferior end of the spine.

**Ventral* and *anterior* are synonymous in humans; this is not the case in four-legged animals. *Ventral* refers to the "belly" of an animal and thus is the inferior surface of four-legged animals. Likewise, although the dorsal and posterior surfaces are the same in humans, the term *dorsal* refers to an animal's back. Thus, the dorsal surface of four-legged animals is their superior surface.

Term	Definition	Illustration	Example
Medial	Toward or at the midline of the body; on the inner side of	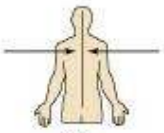	The heart is medial to the arm.
Lateral	Away from the midline of the body; on the outer side of	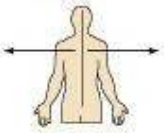	The arms are lateral to the chest.
Intermediate	Between a more medial and a more lateral structure	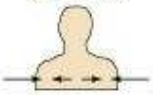	The armpit is intermediate between the breastbone and shoulder.
Proximal	Close to the origin of the body part or the point of attachment of a limb to the body trunk	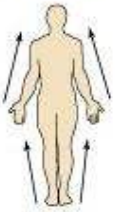	The elbow is proximal to the wrist (meaning that the elbow is closer to the shoulder or attachment point of the arm than the wrist is).

Table 1.1

Distal	Farther from the origin of a body part or the point of attachment of a limb to the body trunk	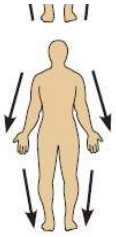	The knee is distal to the thigh.
Superficial (external)	Toward or at the body surface	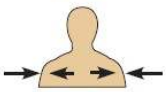	The skin is superficial to the skeleton.
Deep (internal)	Away from the body surface; more internal		The lungs are deep to the rib cage.

*The term *caudal*, literally "toward the tail," is synonymous with *inferior* only to the inferior end of the spine.
†*Ventral* and *anterior* are synonymous in humans; this is not the case in four-legged animals. *Ventral* refers to the "belly" of an animal and thus is the inferior surface of four-legged animals. Likewise, although the dorsal and posterior surfaces are the same in humans, the term *dorsal* refers to an animal's back. Thus, the dorsal surface of four-legged animals is their superior surface.

Table 1.1 (cont)

Figure 1.6

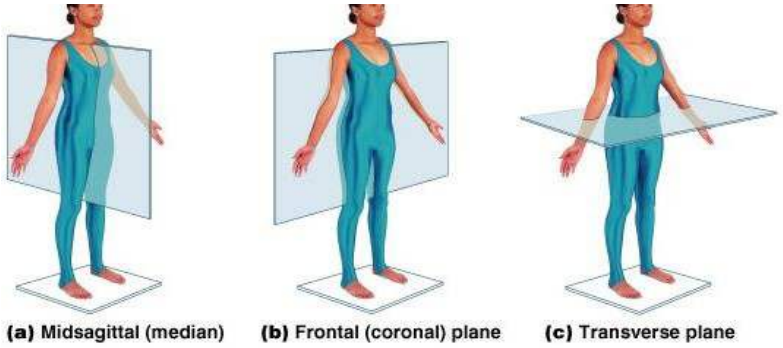

- 3 major planes of section (each results in a different view):
- Sagittal- right & left halves (median/midsagittal)
- Frontal – anterior & posterior (coronal)
- Transverse- superior & inferior (horizontal/cross section)

Table 1.1 (cont)

11

Figure 1.6

Body Planes

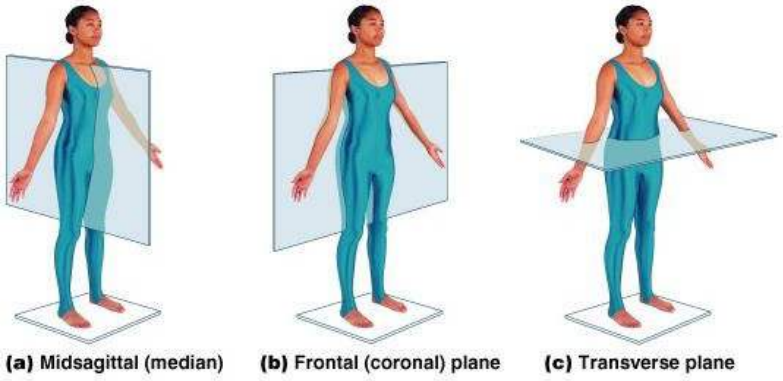

Body ca

- are clos
  outside

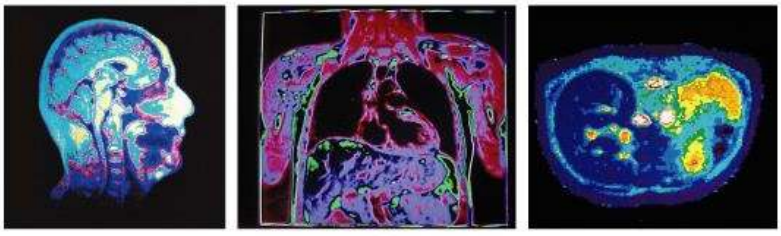

▪ Provide
the organ
within th

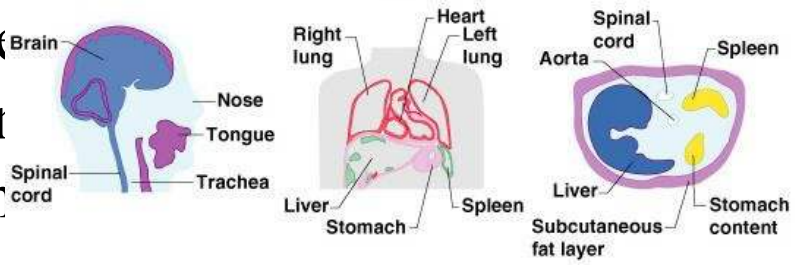

Major body cavities

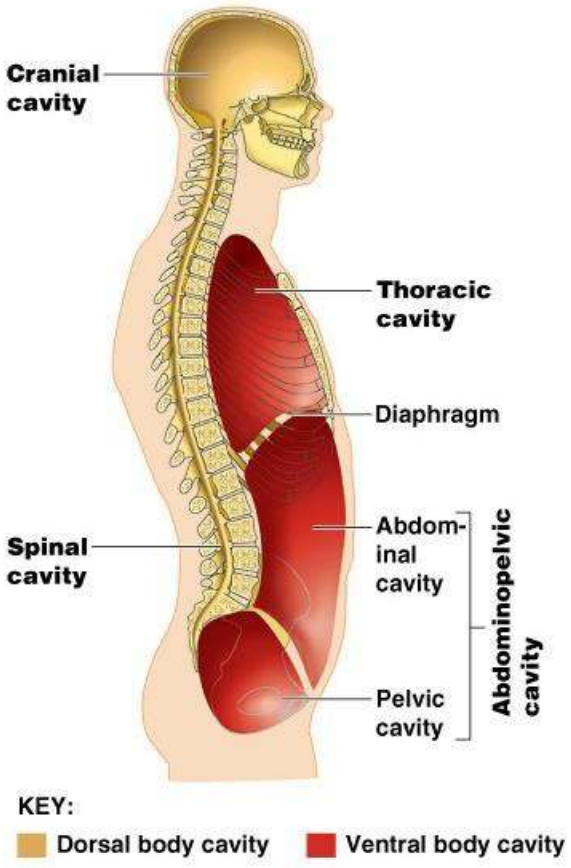

- Dorsal-
  - Cra
  - Spi
- Ventral
  - Th
    trachea, esophagus
  - Abdominal- viscera
  - Pelvic- internal reproductive organs, urinary bladder, rectum

Major body cavities

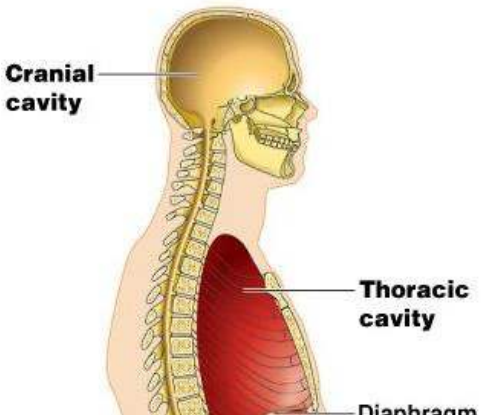

Figure 1.7

- Thoracic cavity is subdivided

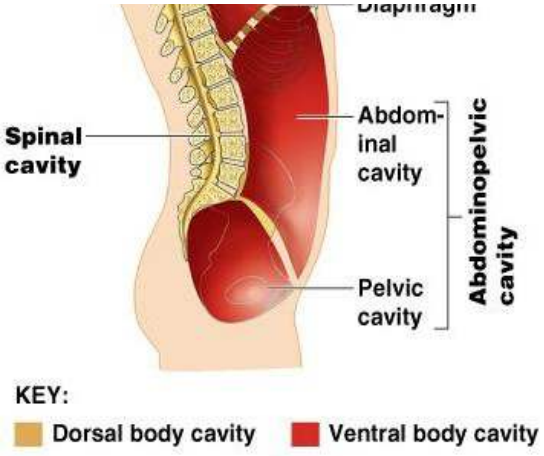

into:

- Pleural cavities (lungs)
- Mediastinum- a central region, separates the lungs; contains heart (pericardial cavity), thymus, trachea, esophagus (superior mediastinum).
- Diaphragm muscle separates thoracic and abdominal cavities.

Figure 1.7

Major body cavities

Figure 1.7

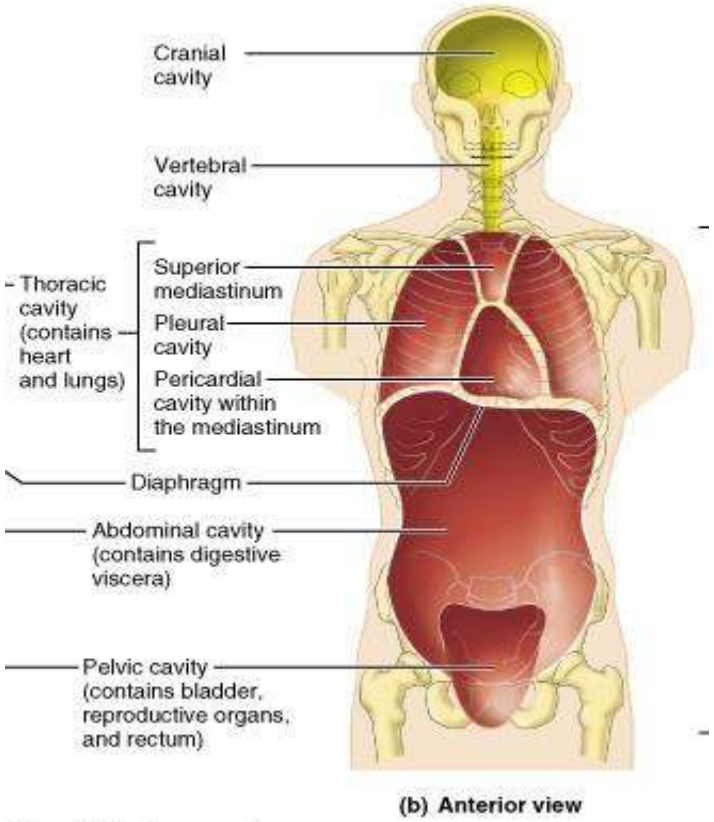

(b) Anterior view

ddison Wesley Longman, Inc.

16

Minor b

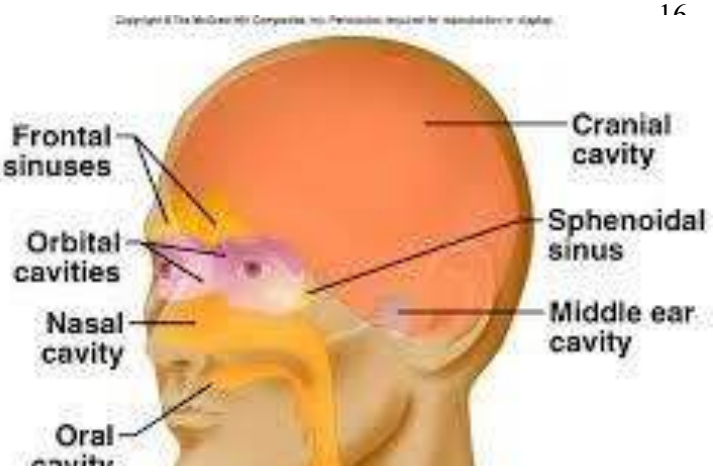



Figure 1.8a

Abdominopelvic Quadrants

Abdominopel Major Organs

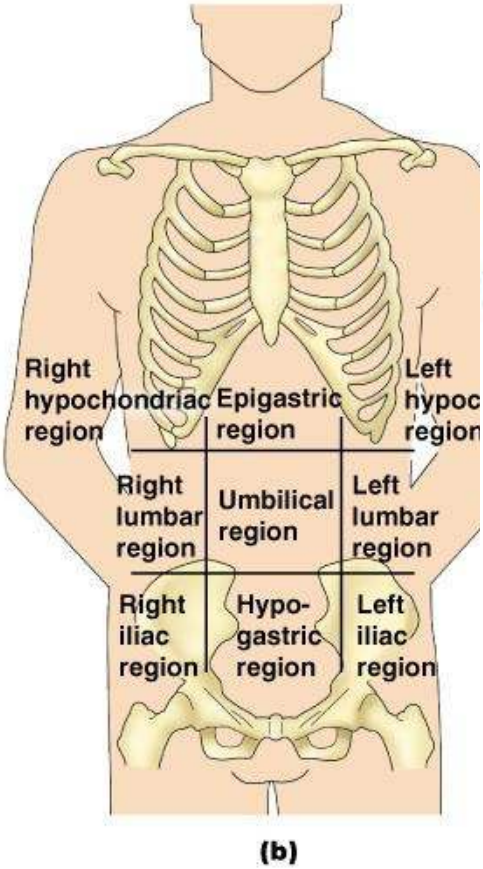

(b)

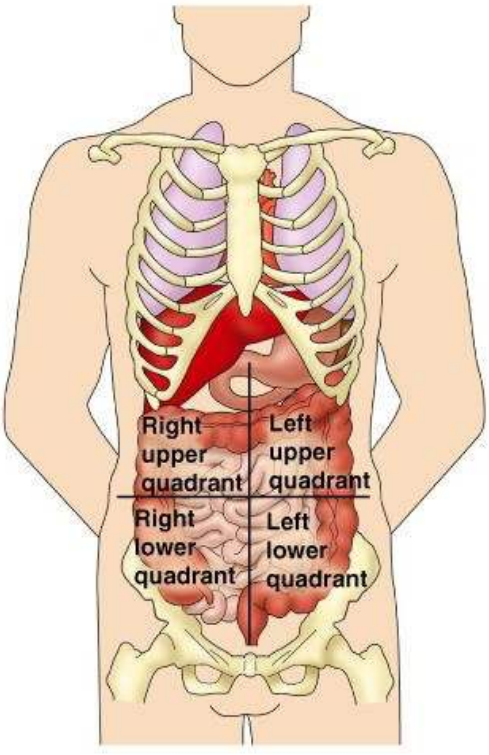

(a)

Figure 1.8b