Skeletal System

Anatomy First Stage

Dr Hawraa kareem

The Skeletal System

- Divided into two divisions
  - Axial skeleton
  - Appendicular skeleton

- Parts of the skeletal system
  - Bones (skeleton)
  - Joints
  - Cartilage
  - Ligaments (bone to bone)
  - Tendon (bone to muscle)

The Skeletal System



Axial skeleton (highlighted in blue)

Skull, Bony thorax, Vertebrae, Hyoid bone

Appendicular skeleton (highlighted in yellow)

Upper and lower limb , Pectoral and Pelvic girdle

- **The skeleton has 206 bones**

Functions of the Bones

- Support of the body
- Protection of soft organs
- Movement due to attached skeletal muscles
- Storage of minerals and fats
- Blood cell formation

Classification of Bones on the Basis of Shape

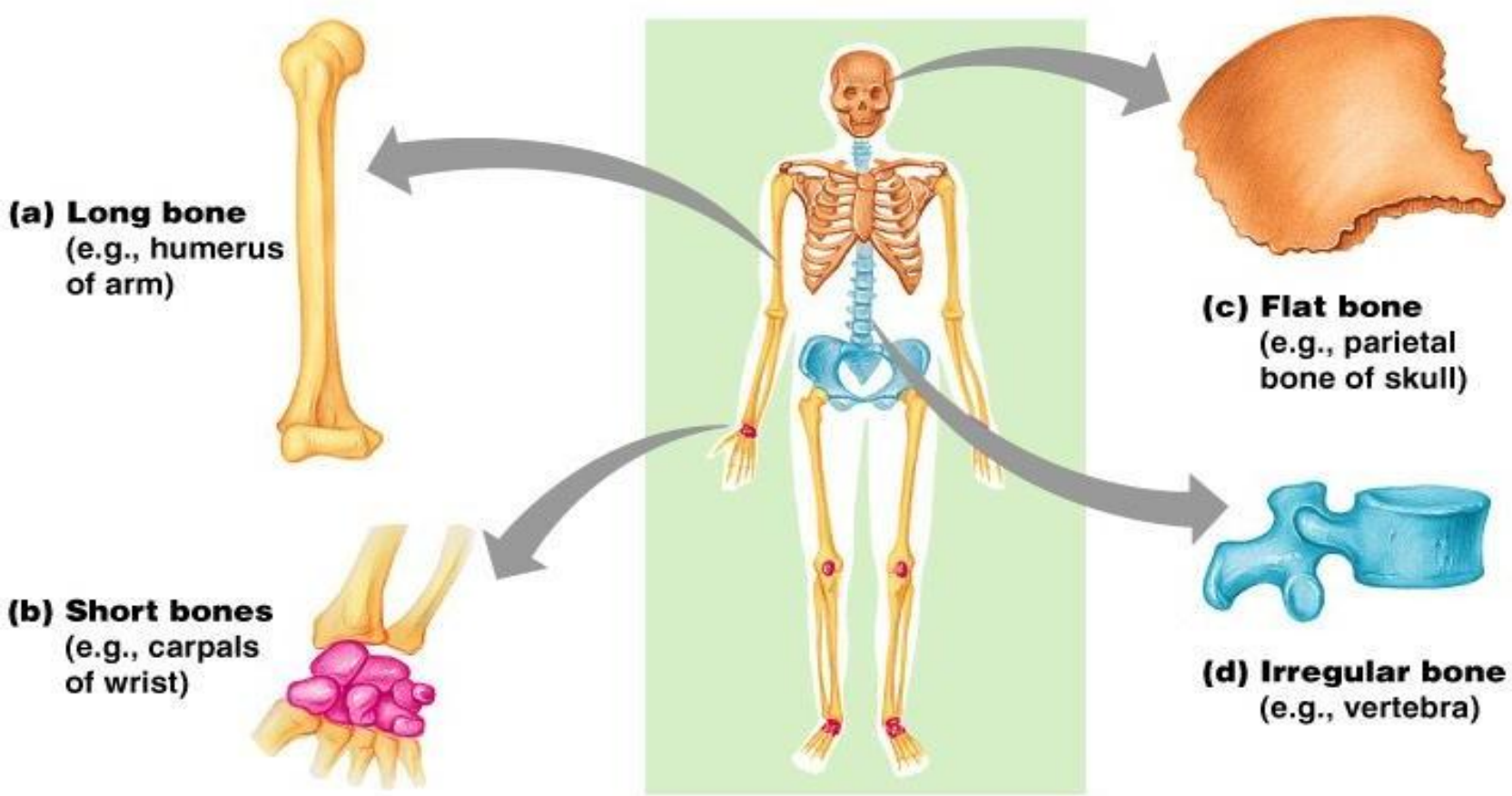

Classification of Bones

1. Long bones
   - Typically longer than wide
   - Have a shaft with heads at both ends
   - Contain mostly compact bone
2. Short bones
   - Generally cube-shape
   - Contain mostly spongy bone

Classification of Bones

3. Flat bones
   - Thin and flattened
   - Usually curved
   - Thin layers of compact bone around a layer of spongy bone
4. Irregular bones
   - Irregular shape
   - Do not fit into other bone

Classification of Bones

- Two basic types depend on osseous tissue
  1. Compact bone
     - ✓ Is dense and looks smooth
     - ✓ Homogenous
  2. Spongy bone
     - ✓ Small needle-like pieces of bone
     - ✓ Many open spaces

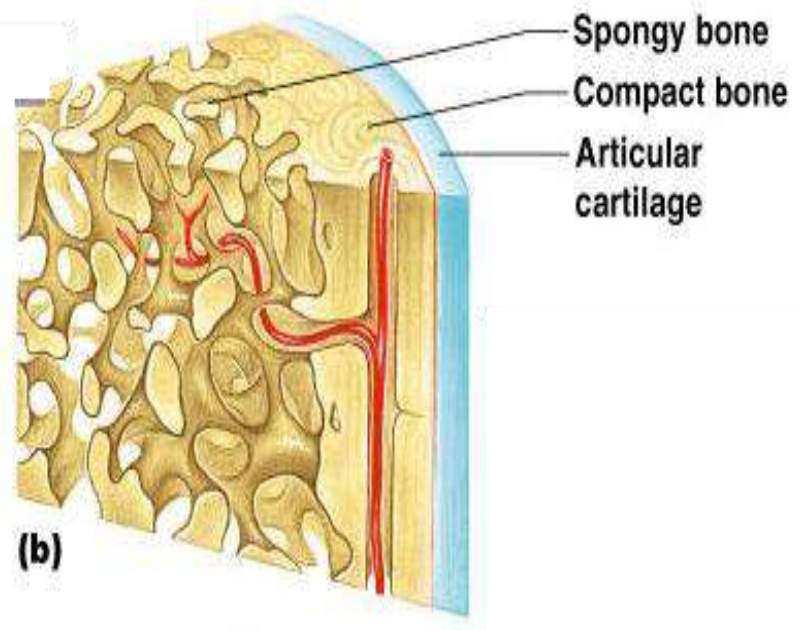

Gross Anatomy of a Long Bone

- Diaphysis
  - Shaft
  - Composed of compact bone
- Epiphysis
  - Ends of the bone
  - Composed mostly of spongy bone

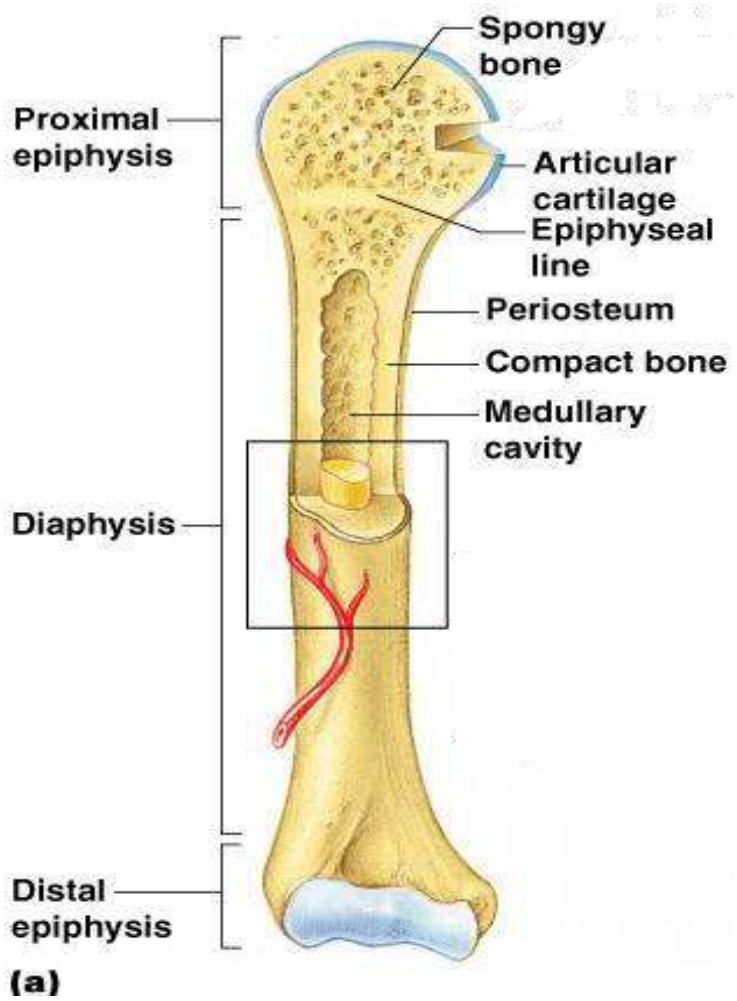

Structures of a Long Bone

- Periosteum
  - Outside covering of the diaphysis
  - Fibrous connective tissue membrane
- Sharpey's fibers
  - Secure periosteum to underlying bone
- Arteries
  - Supply bone cells with nutrients

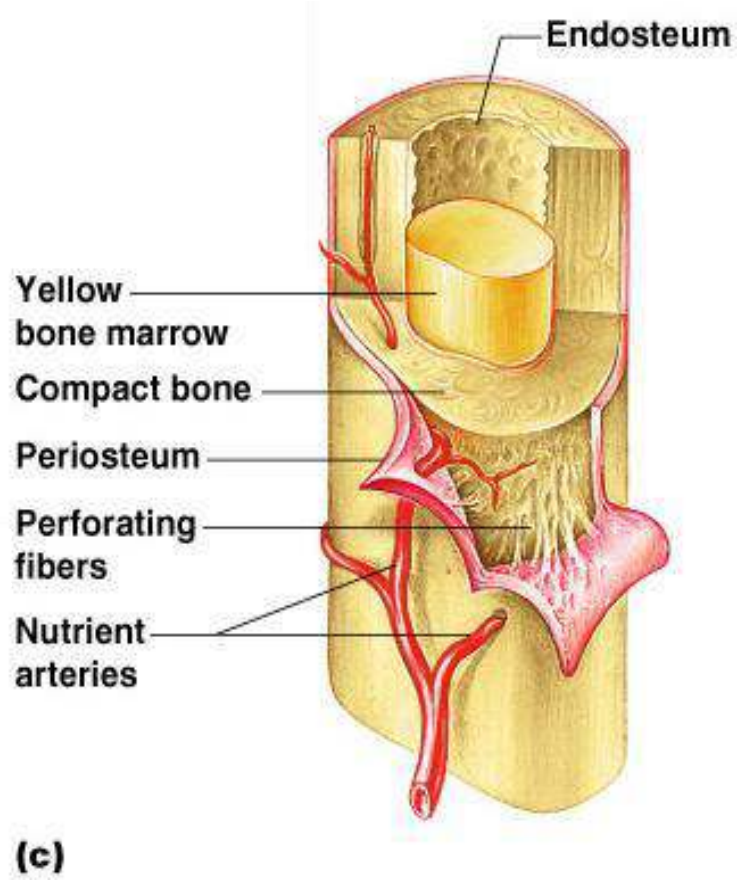

Structures of a Long Bone

- Articular cartilage
  - Covers the external surface of the epiphyses
  - Made of hyaline cartilage
  - Decreases friction at joint surfaces

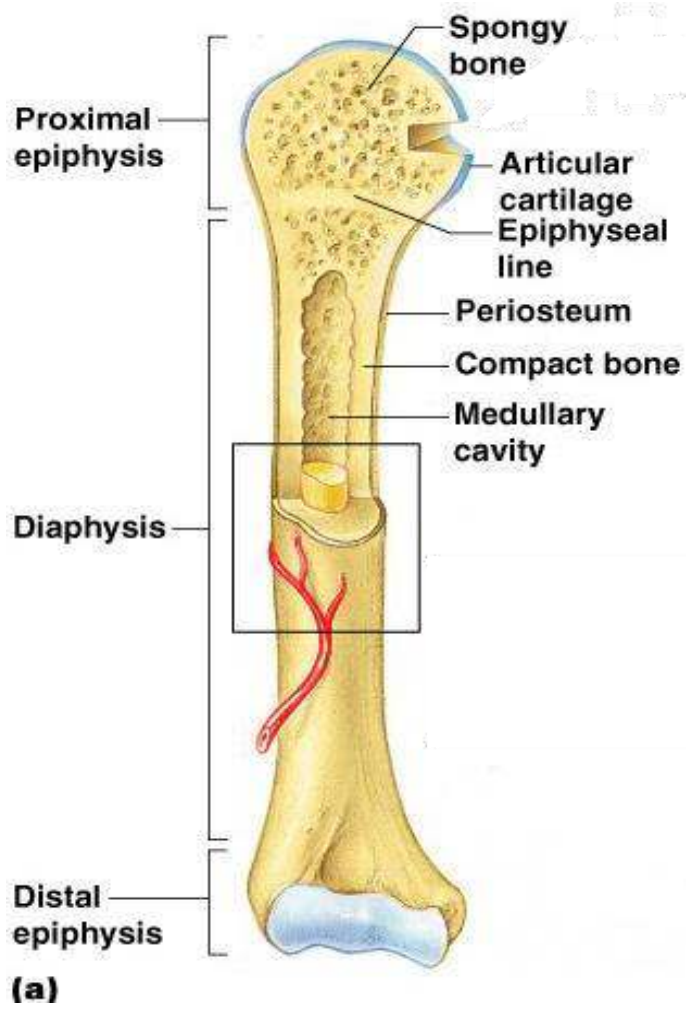

Structures of a Long Bone

- Medullary cavity
  - Cavity of the shaft
  - Contains yellow marrow (mostly fat) in adults
  - Contains red marrow (for blood cell formation) in infants

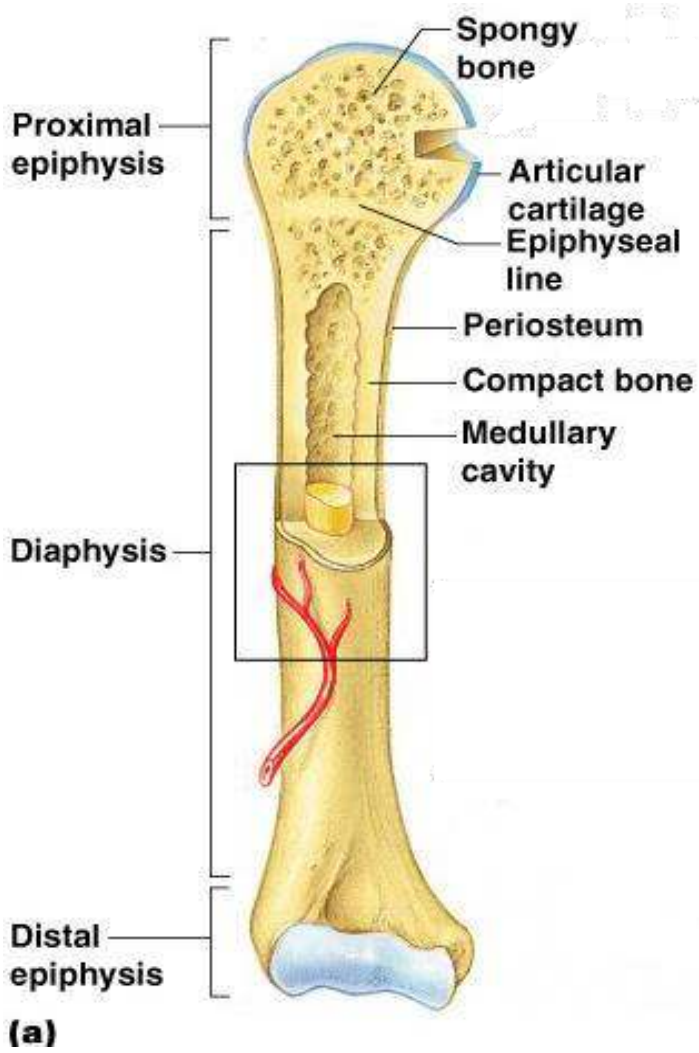

Supporting Connective Tissue: I. Bone (osseous tissue)

- ❖ Bone (osseous tissue)
  - Function
    - Support
    - Protection
    - Stores calcium and other minerals
    - stores fat
    - Forms blood cells (hematopoiesis)
  - ❖ Types of bone:
    - 1- Compact bone
    - 2- Spongy bone.

I. compact bone

Microscopic Anatomy of compact bone:

- **Osteon (Haversian System)**
  - A unit of bone
- **Central (Haversian) canal**
  - Opening in the center of an osteon
  - Carries blood vessels nerves
- **Perforating (Volkman's) canal**
  - Canal perpendicular to the central canal
  - Carries blood vessels and nerves

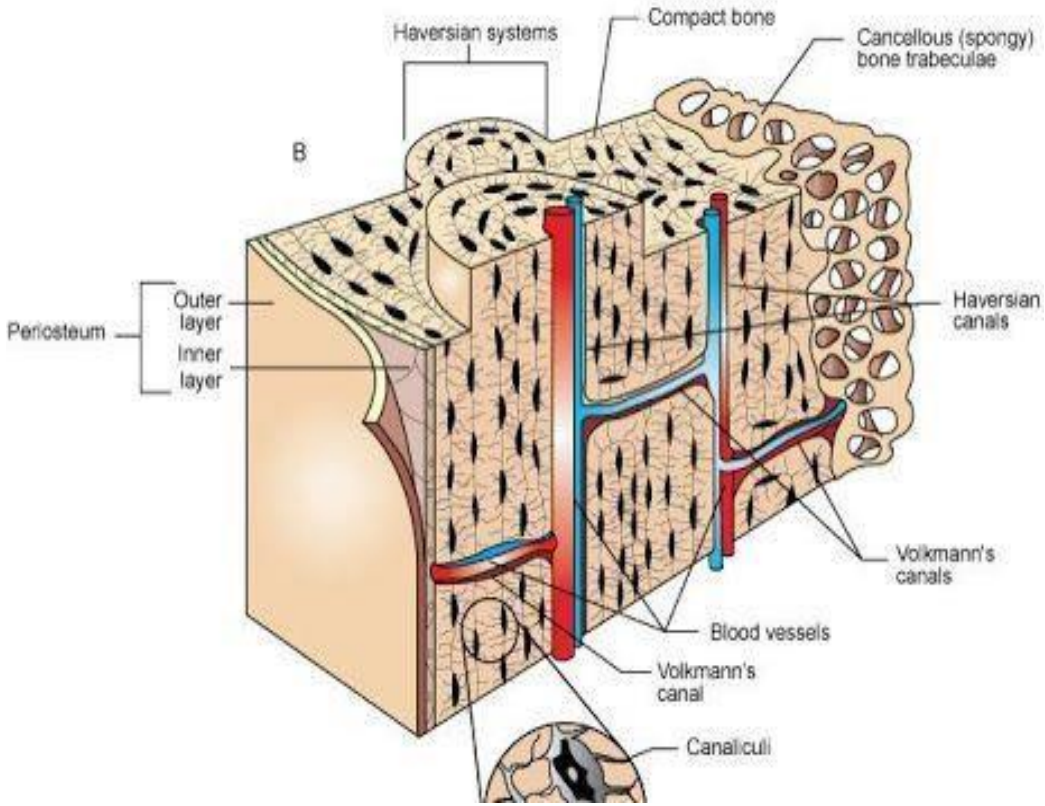

Microscopic Anatomy of compact bone

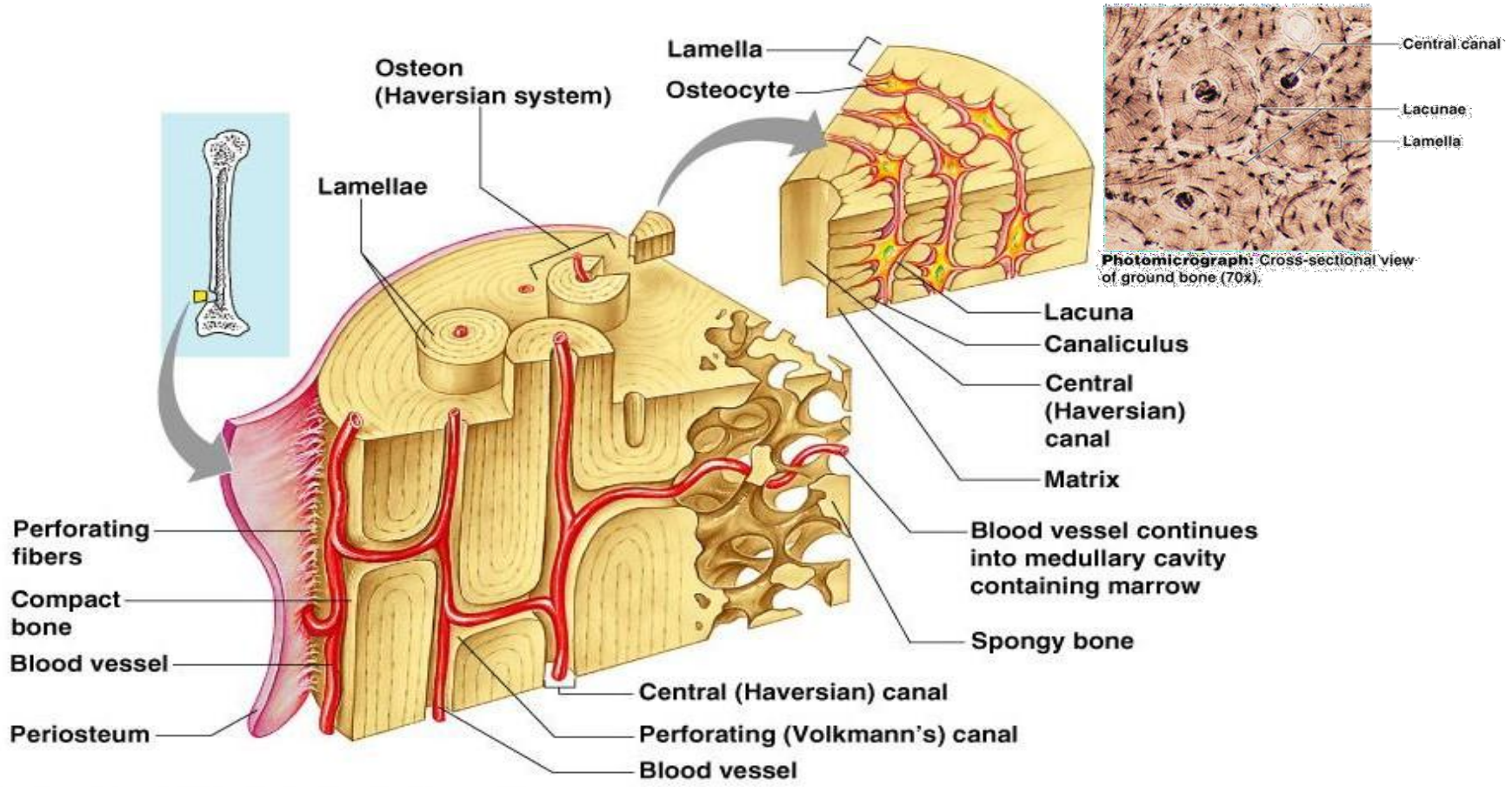

Microscopic Anatomy of compact bone

- **Lacunae**
  - Cavities containing bone cells (osteocytes)
  - Arranged in concentric rings
- **Lamellae**
  - Rings around the central canal
  - Sites of lacunae
- **Canaliculi**
  - Tiny canals
  - Radiate from the central canal to lacunae
  - Form a transport system

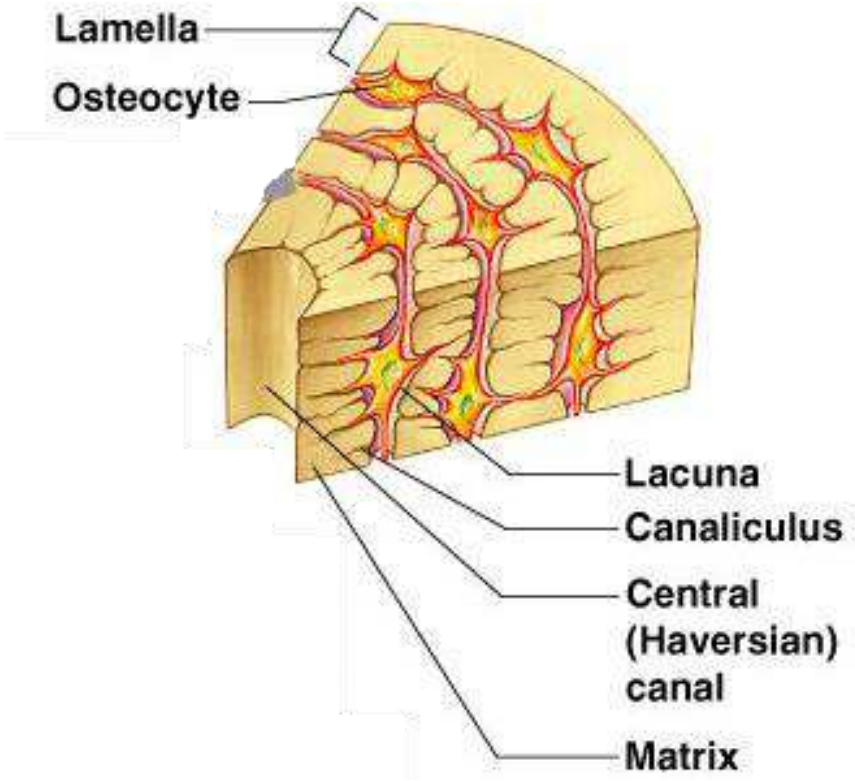

Types of Bone Cells

- **Osteocytes**
  - Mature bone cells
- **Osteoblasts**
  - Bone-forming cells
- **Osteoclasts**
  - Bone-destroying cells
  - Break down bone matrix for remodeling and release of calcium
- Bone remodeling is a process controlled by both osteoblasts and osteoclasts

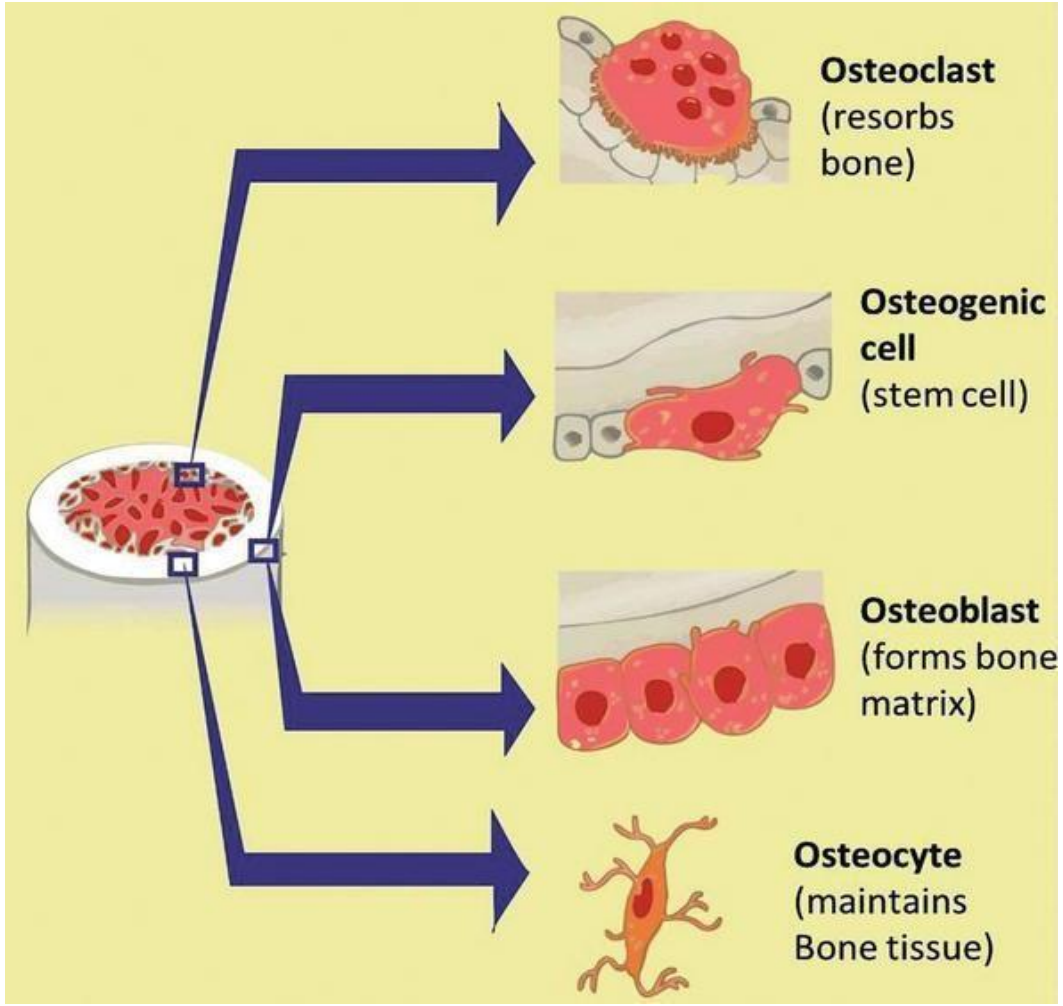

2. Spongy bone (cancellous)

- **Spongy bone (cancellous):**
- forms the sides of long bones
- Thin plates of collagen fibers (trabeculae)

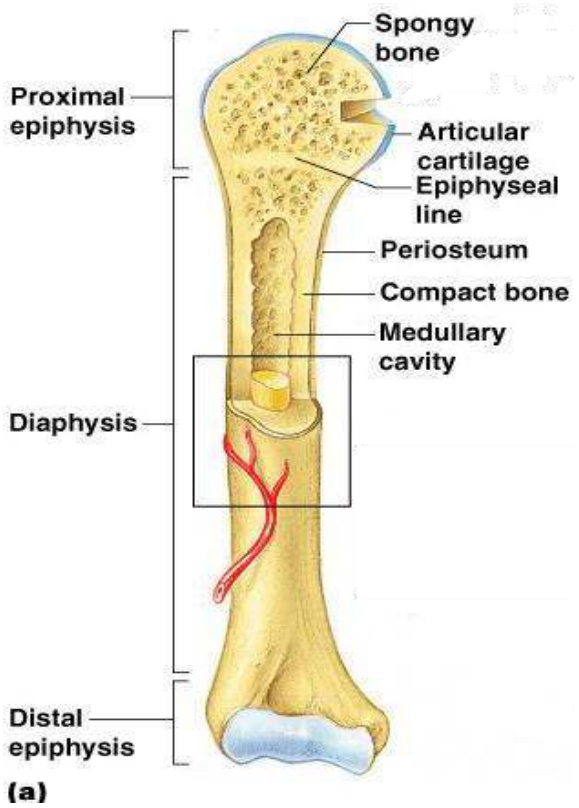

Supporting Connective Tissue: Cartilage

- Cartilage
  - Structure
    - Chondroblasts: produce the matrix
    - Chondrocytes: mature cartilage cells
    - Lacks direct blood supply, nerve fibers
    - lymphatic vessels; supplied by diffusion

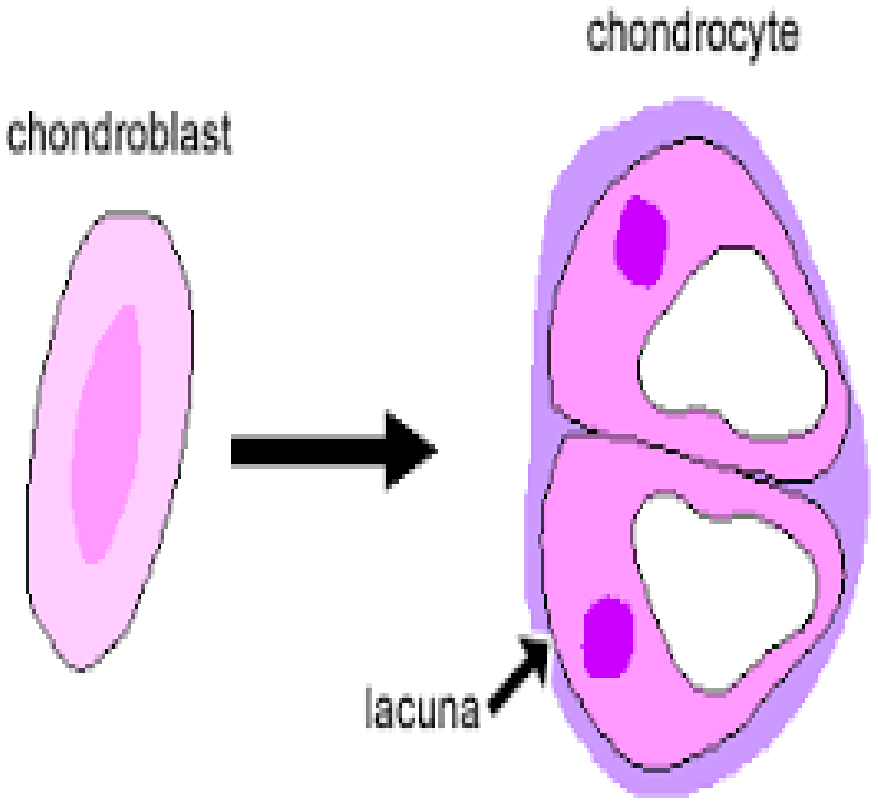

- Types:
    1) Hyaline cartilage
    2) Elastic cartilage
    3) Fibrocartilage

Cartilage

1. **Hyaline cartilage** (Most common cartilage)

- Structure
  - collagen and elastic fibers
  - Rubbery matrix
- Function
  a. Bone Development (growth of long bones)
  b. Support (able to tolerate weight)

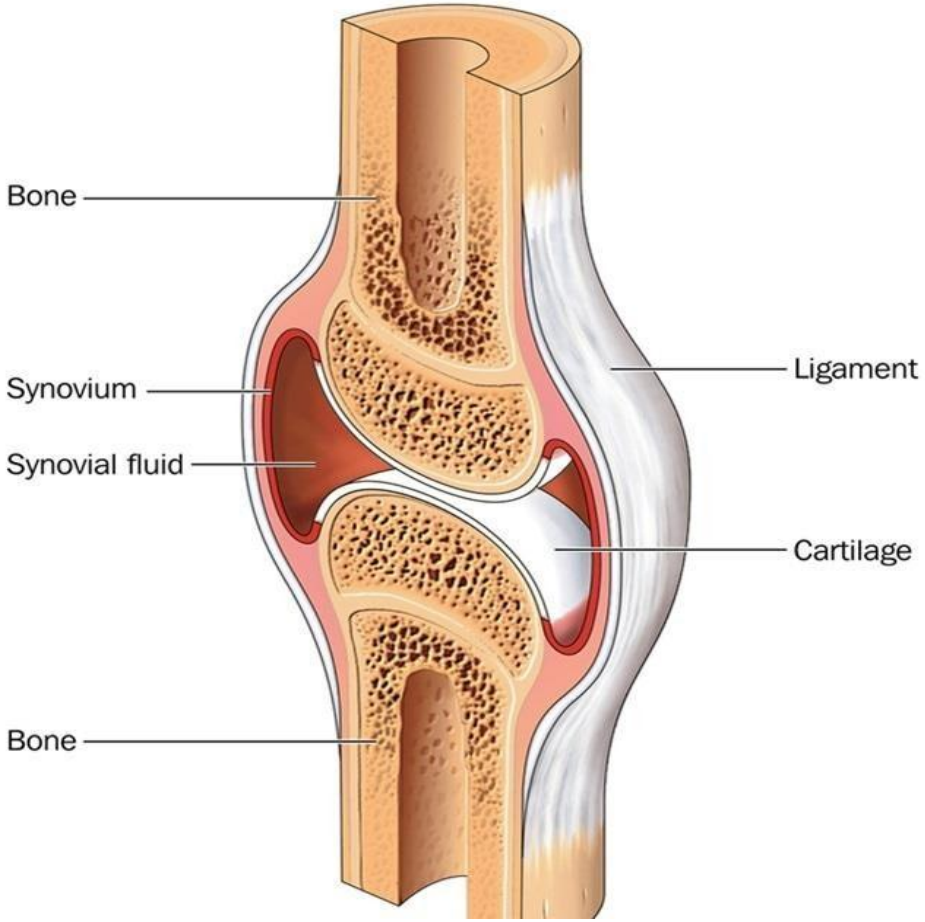

Cartilage

- Location
  - Tracheal and bronchial cartilage
  - Nasal septum
  - Forms supporting structure of larynx (voicebox)
  - Attaches ribs to breastbone (costal cartilage)
  - Covers ends of long bones (joint cavities)
  - Composes most of the fetal/ embryonic skeleton

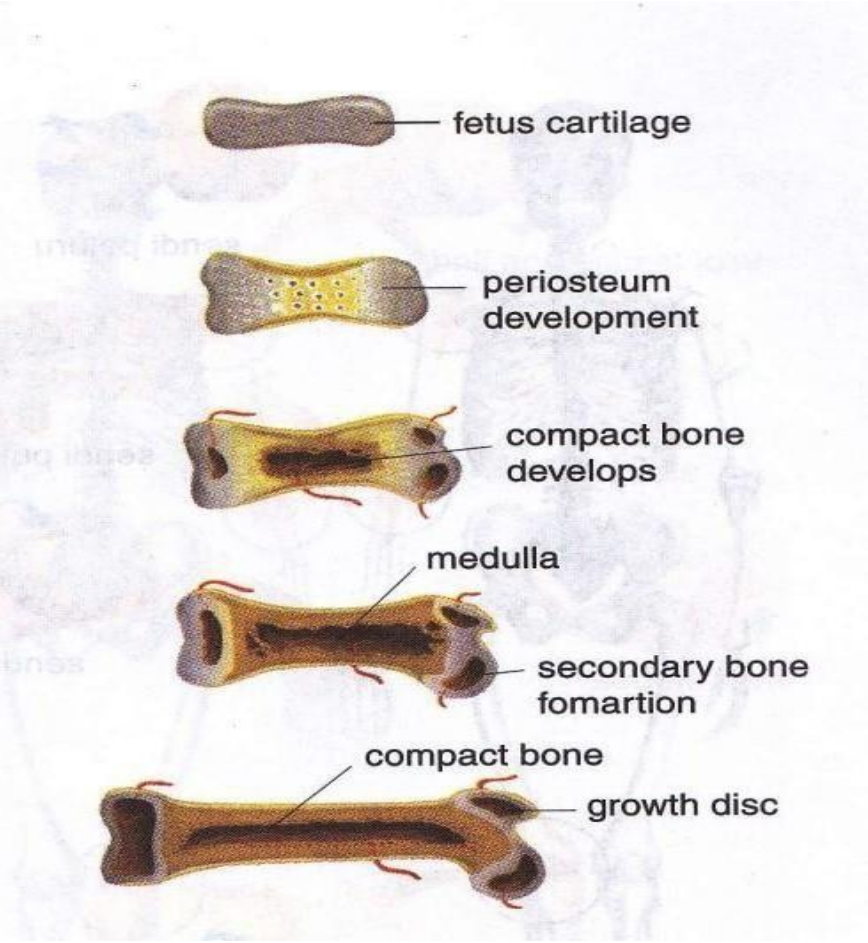

Cartilage

2. Elastic cartilage

- Structure
  - Dark in color
  - Contains both elastic and collagen fibers but more Elastic fibers
- Function

  Provides elasticity and flexibility
- Location
  - Entrance of larynx (Epiglottis)
  - External ear (ear pinna)

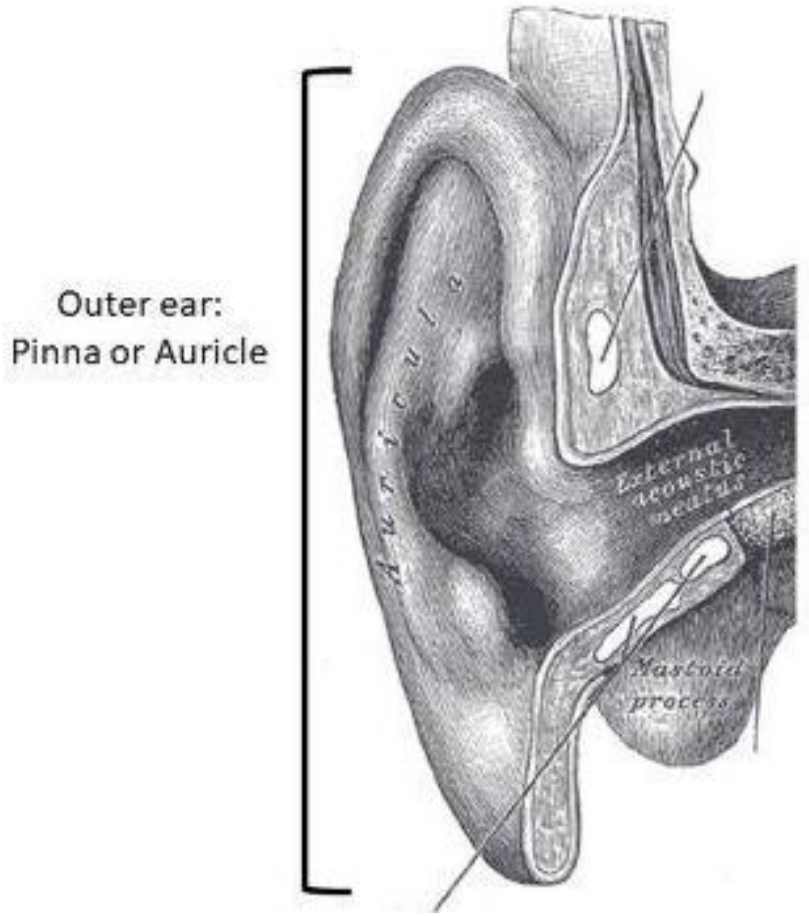

Cartilage

3. **<u>Fibrocartilage</u>**
    - Structure
        - mainly collagen fibers
        - very little matrix
        - No perichondrium (no capsule)
        - Highly compressible (tough)
    - Function
        - Shock absorber
    - Location
        - Intervertebral disks
        - Cushions the knee joint
        - Pubic symphysis



The Axial Skeleton

Divided into four parts:

- Skull
- Bony thorax
- Vertebral column
- Hyoid bone

The Axial Skeleton

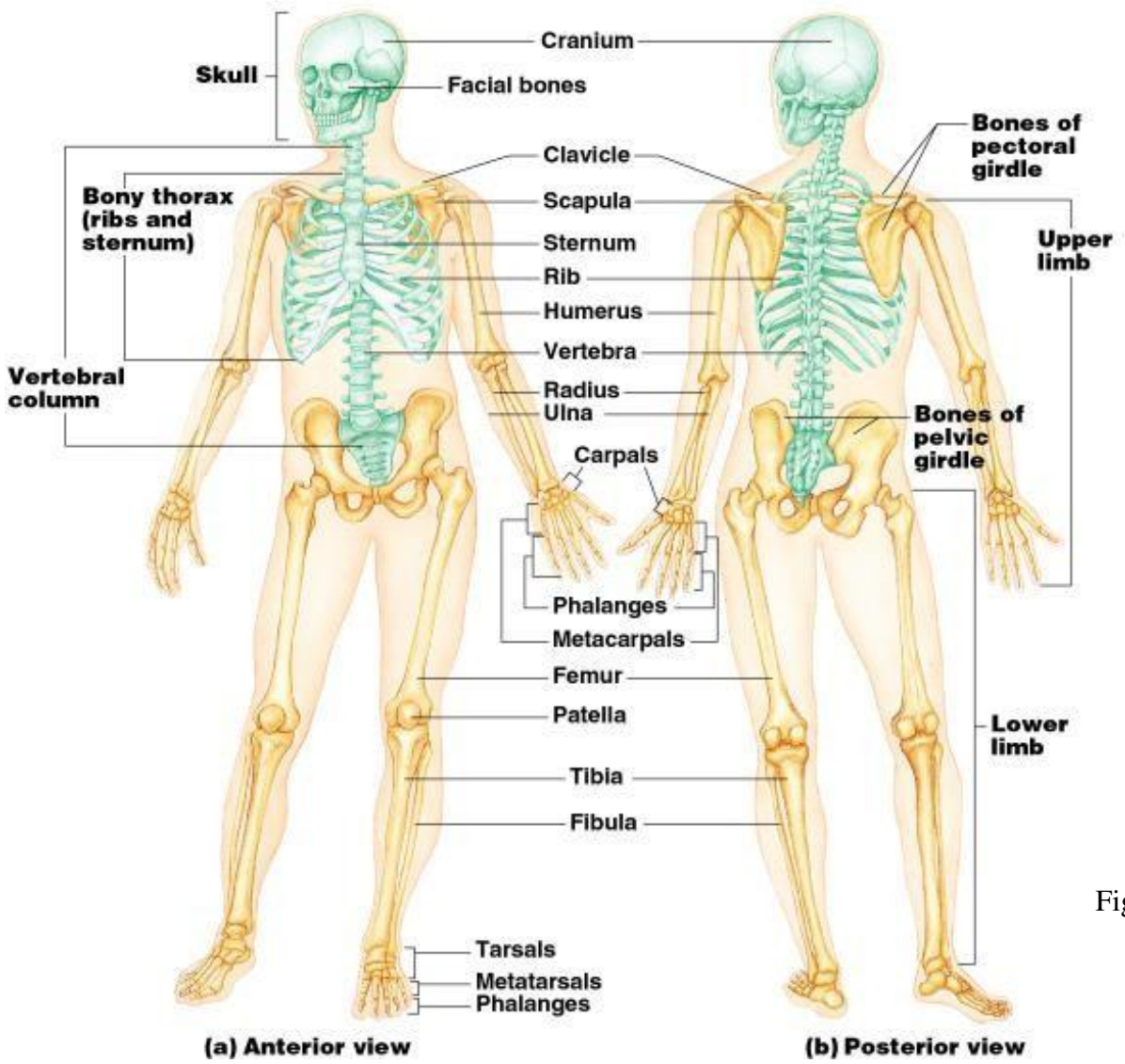

Figure 5.6

Bones of the Skull

Skull (divided into Two sets of bones: Cranial and Facial bones). Bones are joined by sutures

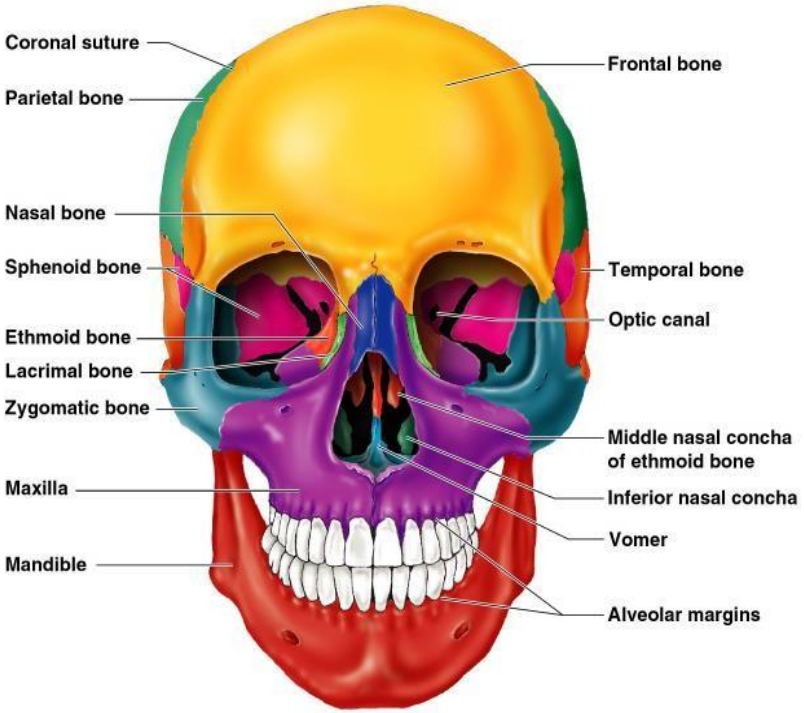

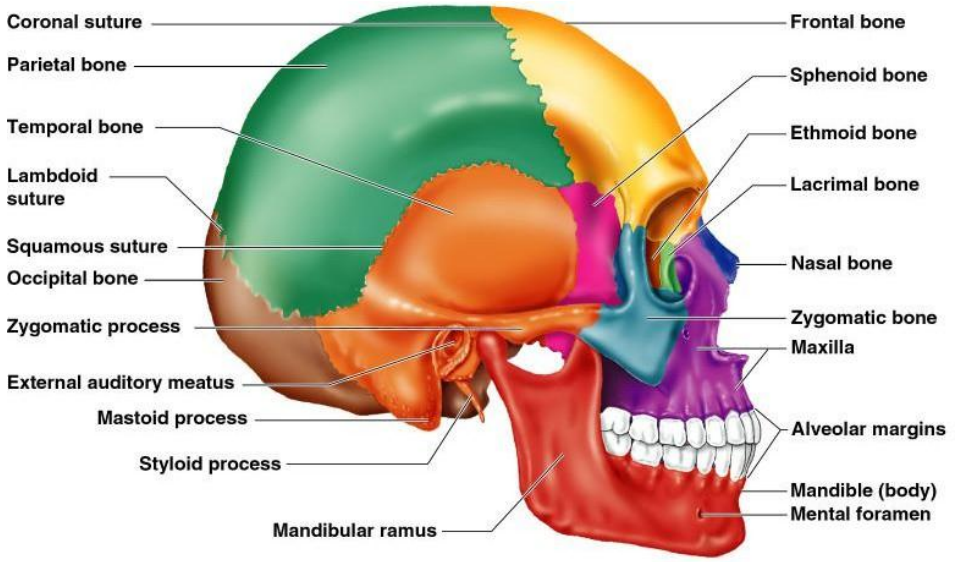

The Bony Thorax

- Forms a rib cage to protect major organs (like heart, lungs)
- 12 pairs of ribs
- 12 thoracic vertebrae
- Sternum

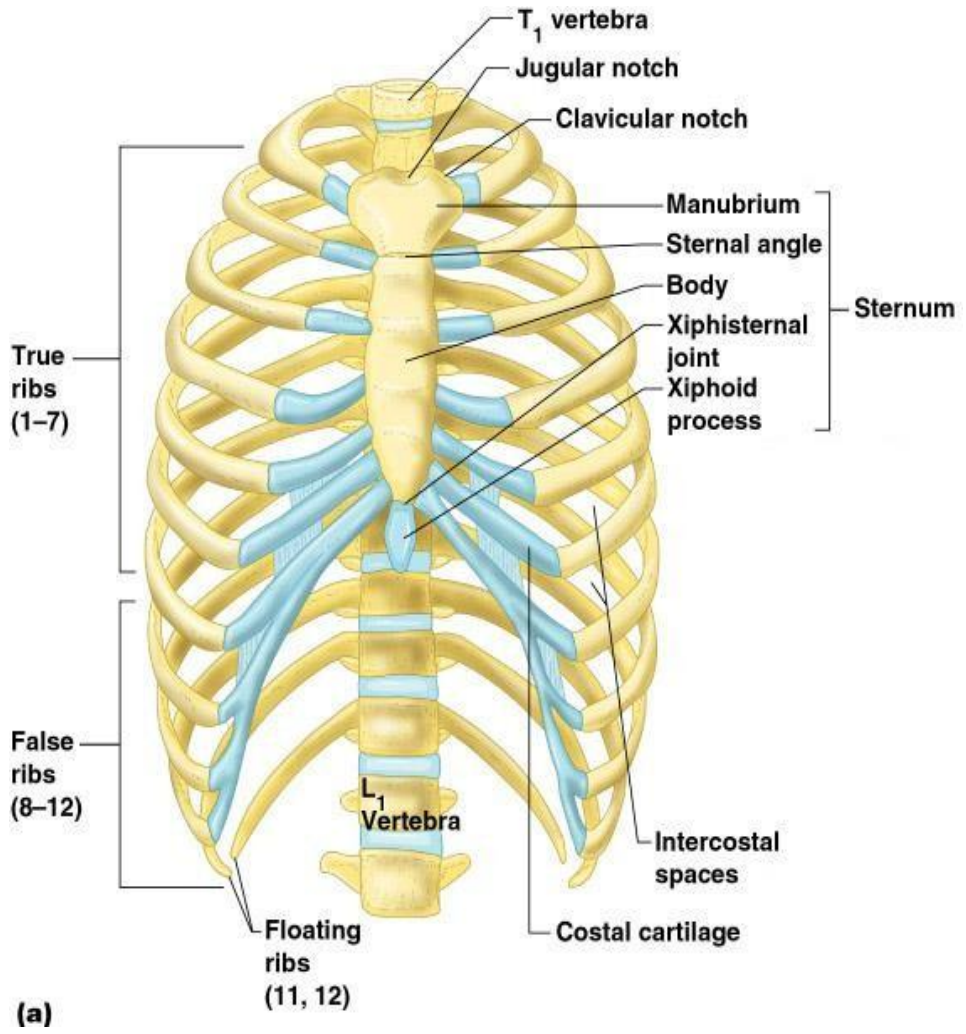

The Vertebral Column

- 33 vertebrae
- 24 individual vertebrae
- 9 fused vertebrae
- Irregular bones
- Vertebrae separated by intervertebral discs (fibrocartilage)
- Each vertebrae is given a name according to its location: cervical, thoracic, lumbar, sacral (sacrum), coccygeal (coccyx).

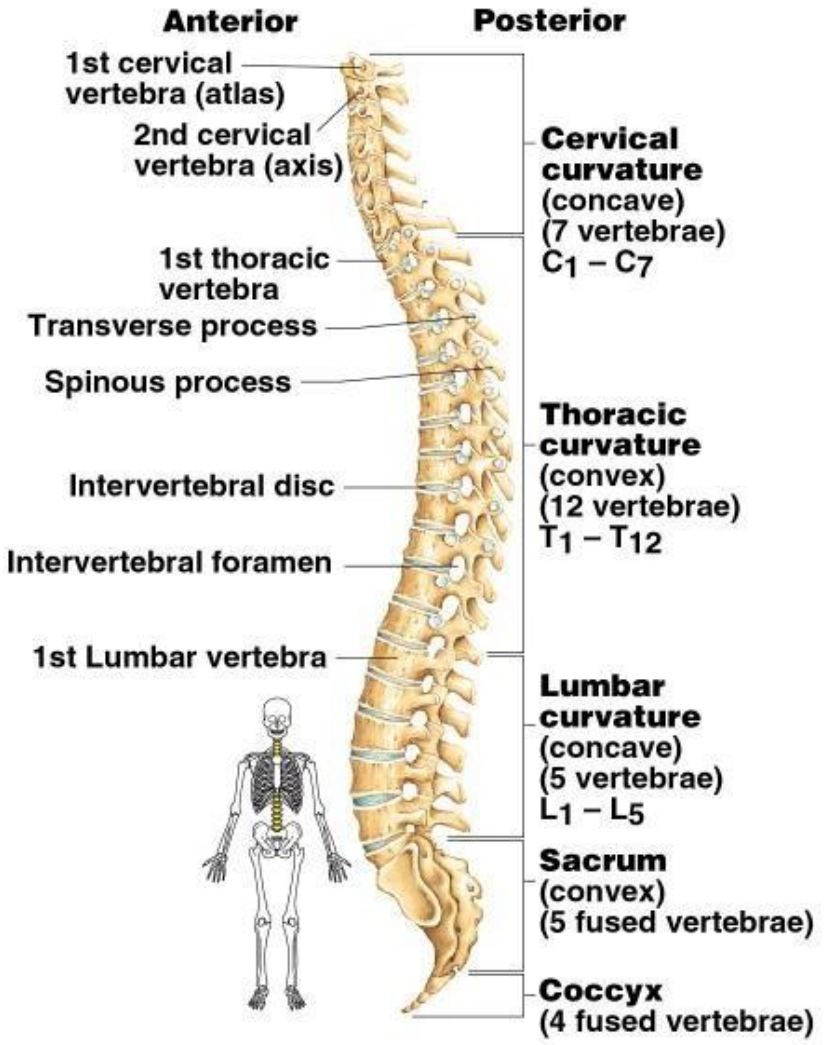

The Hyoid Bone

- C-shaped bone
- The only bone that does not articulate with another bone
- Serves as a moveable base for the tongue
- The hyoid bone also helps to keep the larynx (voice box) open at all times

