Practical (1)
By
Muneer jawad MS.c RT

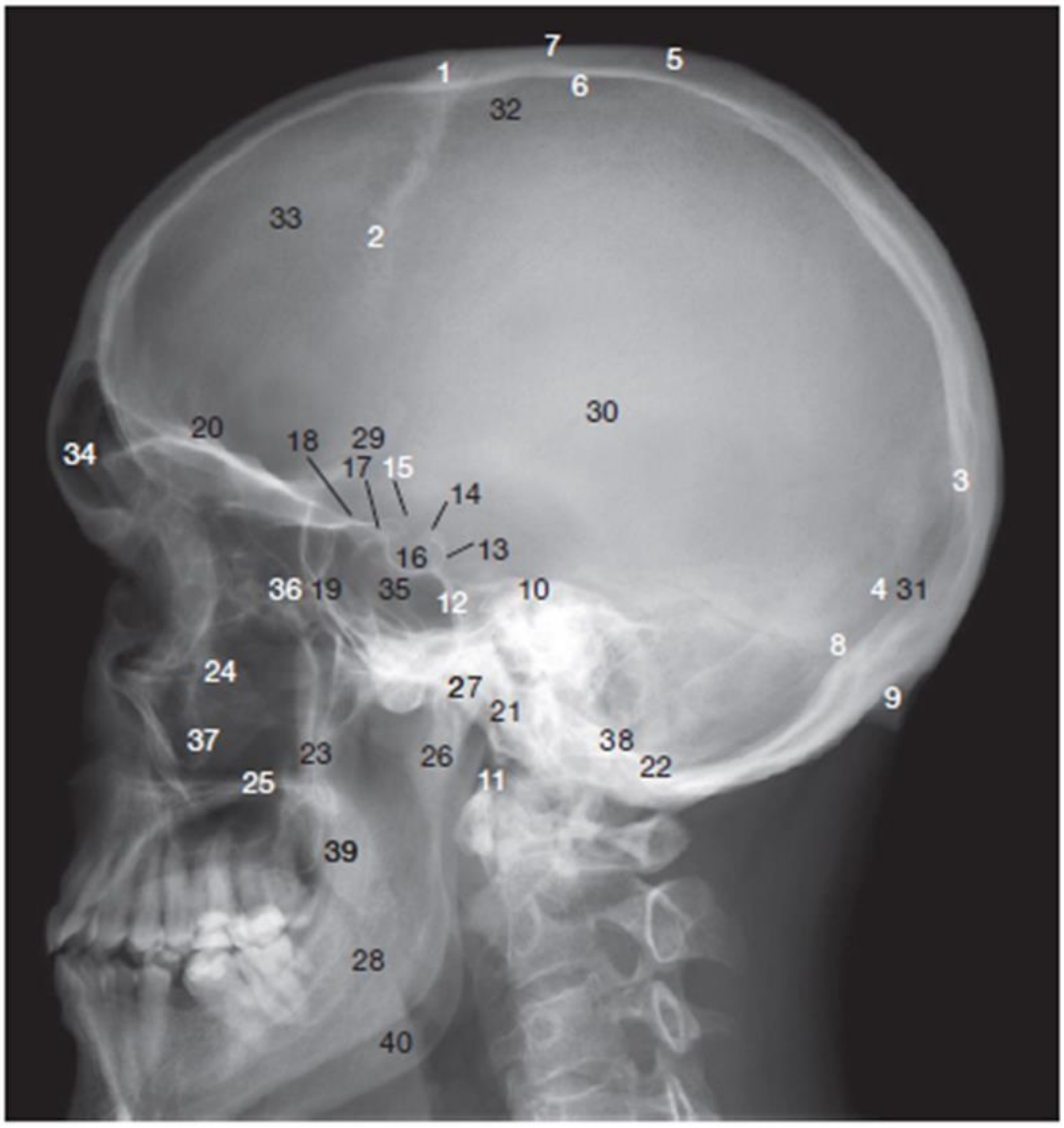


## Lateral Skull X-ray

1. Bregma
2. Coronal suture
3. Lambda
4. Lambdoid suture
5. Vertex
11. Styloid process
12. Clivus
13. Dorsum sellae

14. Posterior clinoid process
15. Anterior clinoid process
16. Pitutary fossa (sella turcica)
17. Tuberculum sellae

19. Greater wings of sphenoid

23. Posterior wall of maxillary
24. Floor of the orbit

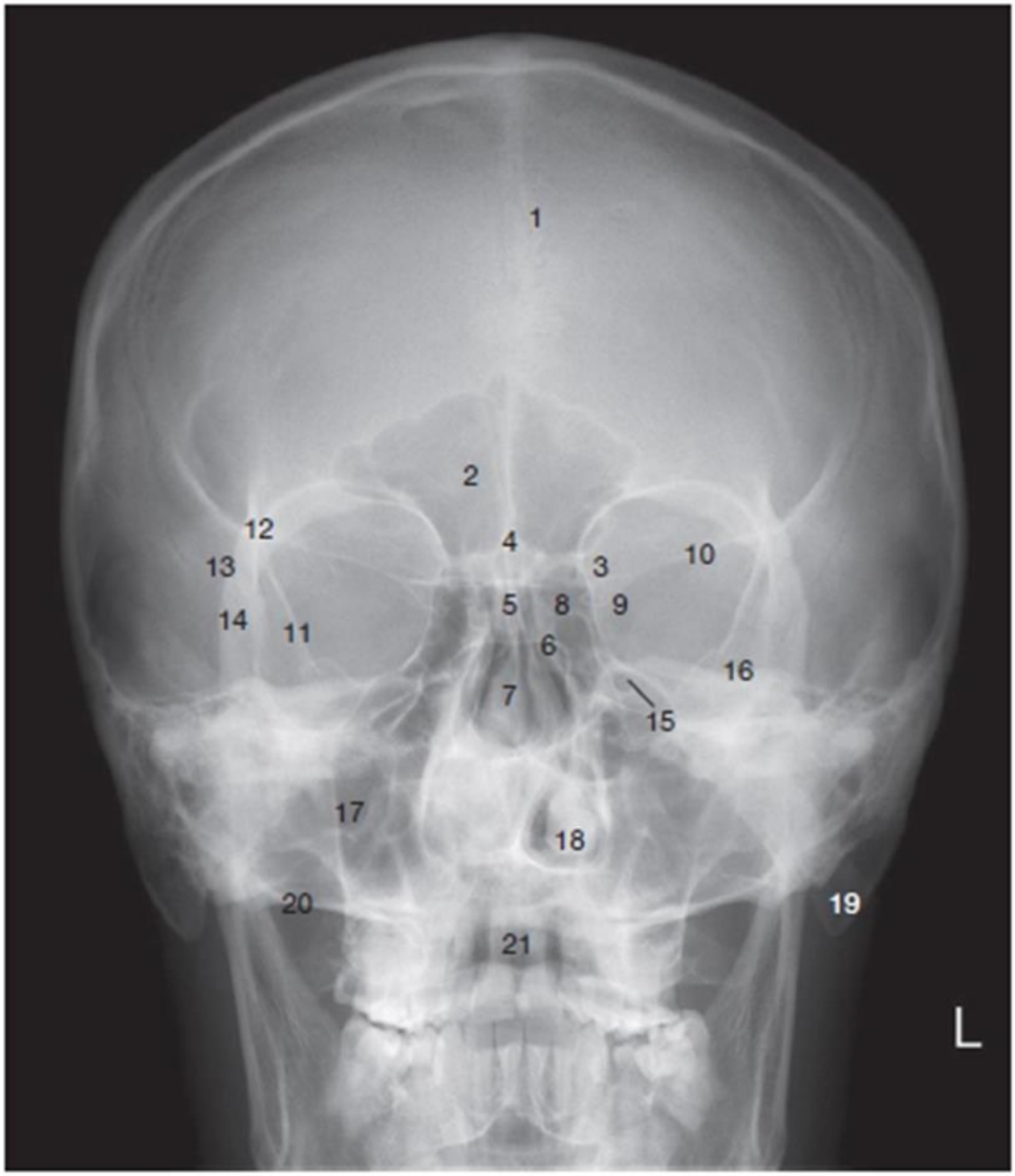


## OF20 Skull Radiograph

1. Sagittal suture
4. Crista gallia
5. Perpendicular plate of ethmoid
6. Floor of pituitary fossa
7. Nasal septum
10. Lesser wing of sphenoid
12. Zygomatic process of frontal bone
13. Zygomaticofrontal suture
14. Frontal process of zygomatic bone
20. Occepetal bone

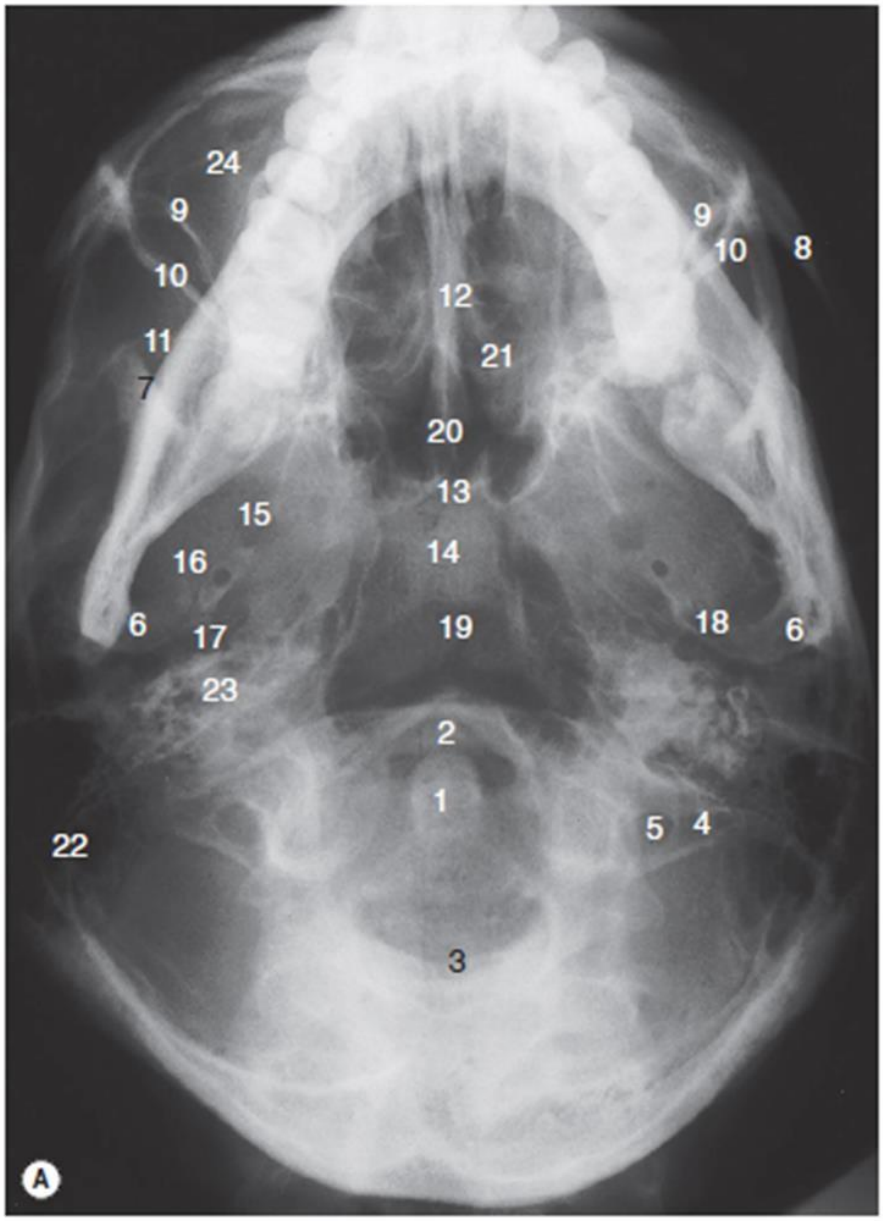


## SMV Skull Radiograph

3. Posterior limit of foramen magnum
8. Zygomatic arch
10. Lateral boundary of the orbit
11. Lesser wing of sphenoid
12. Nasal septum
14. Clivus

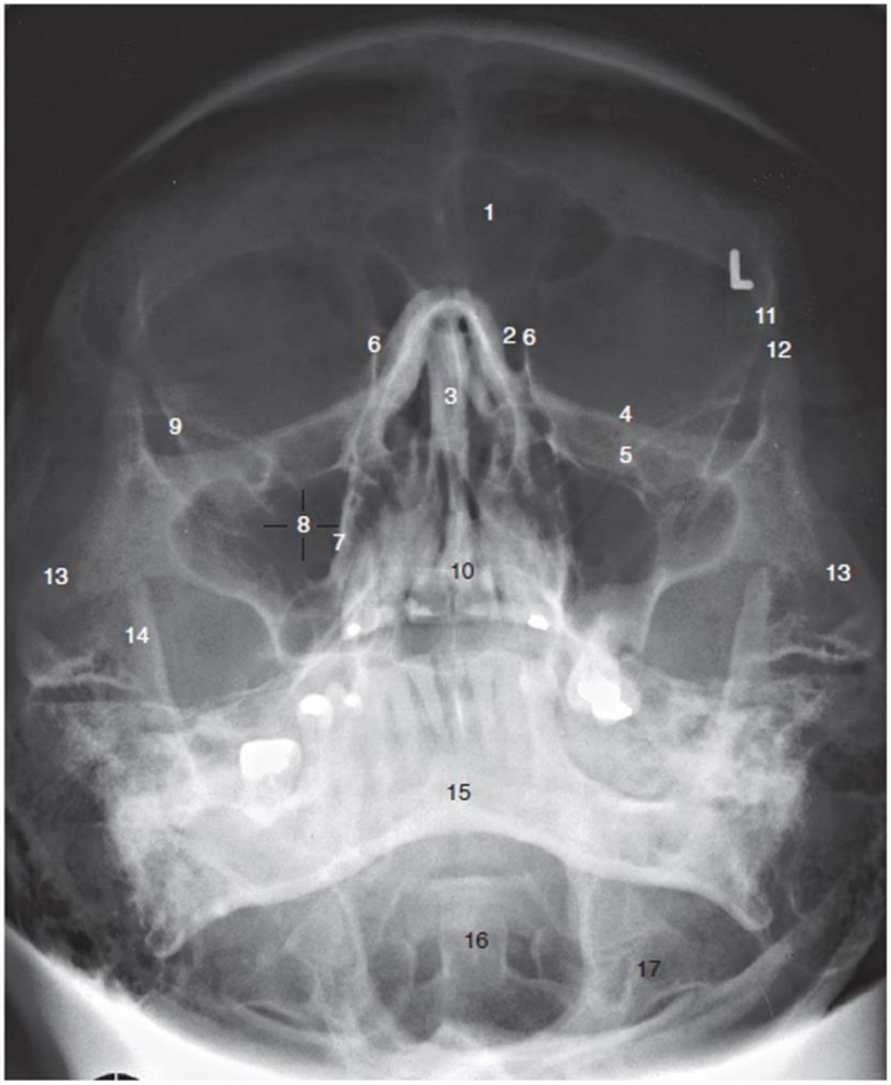


## OM Skull Radiograph

3. Nasal septum
4. Inferior orbital rim
6. Medial wall of the orbit
11. Zygomatic process of frontal bone
12. Zygomaticofrontal suture
13. Zygomatic arch

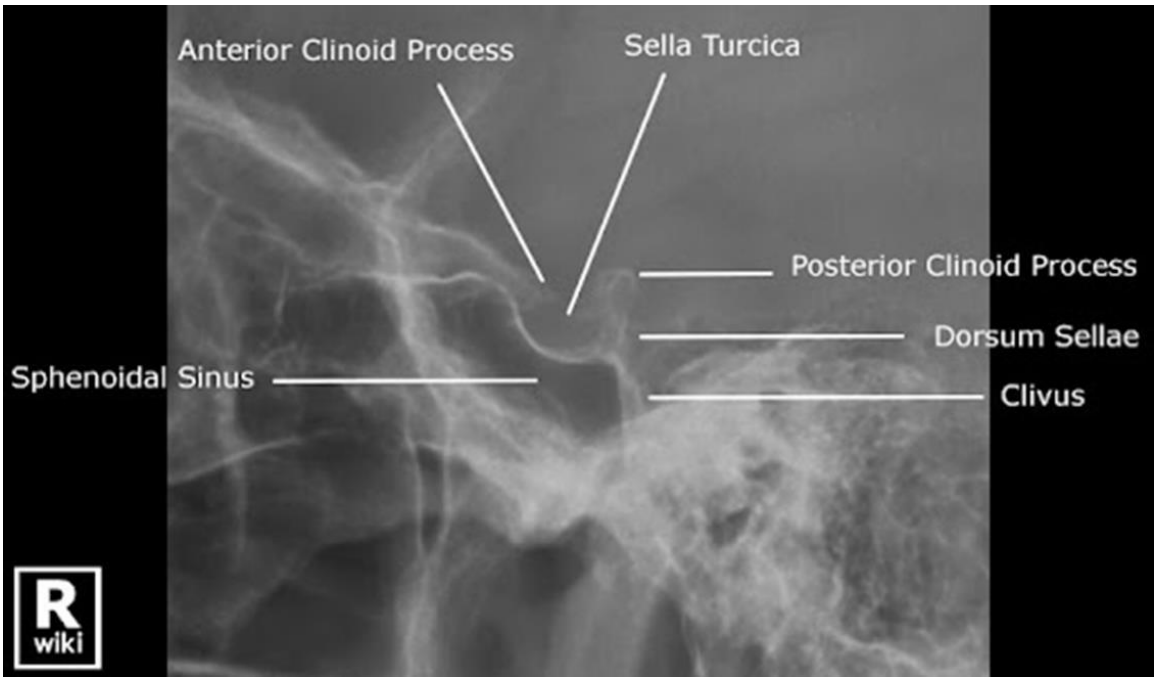


**Sella Turcica**