Positron Emission Tomography/ PET-CT

Positron emission tomography, also called ***PET imaging*** or a ***PET scan***, is a type of ***nuclear medicine imaging***, of ***dual-modality imaging*** that utilizes the advantages of both ***positron emission tomography*** (PET) and ***computed tomography (CT)***.

Nuclear medicine uses small amounts of ***radioactive material*** called ***radiotracers***, to ***diagnose, evaluate, and treat various diseases***. *Radiotracers* are ***molecules linked to, or "labeled" with, a small amount of radioactive material***. They accumulate in ***tumors or regions of inflammation***. They can also ***bind to specific proteins in the body***. The most common radiotracer is 2-[F-18]fluoro-2-deoxy-D-glucose (FDG), a molecule ***similar to glucose***. Fluorine-18 is an ***unstable radioisotope*** and has a ***half-life of approximately 110 minutes***.

Cancer cells are more metabolically active and may absorb glucose at a higher rate. It accumulates in the area under examination. A special ***camera*** detects ***gamma ray emissions from the radiotracer***. The camera and a computer produce pictures and supply ***molecular information***. CT imaging uses special X-ray equipment to produce multiple images of the inside of the body. A radiologist views and interprets these images on a computer monitor. CT imaging provides excellent ***anatomic information***.

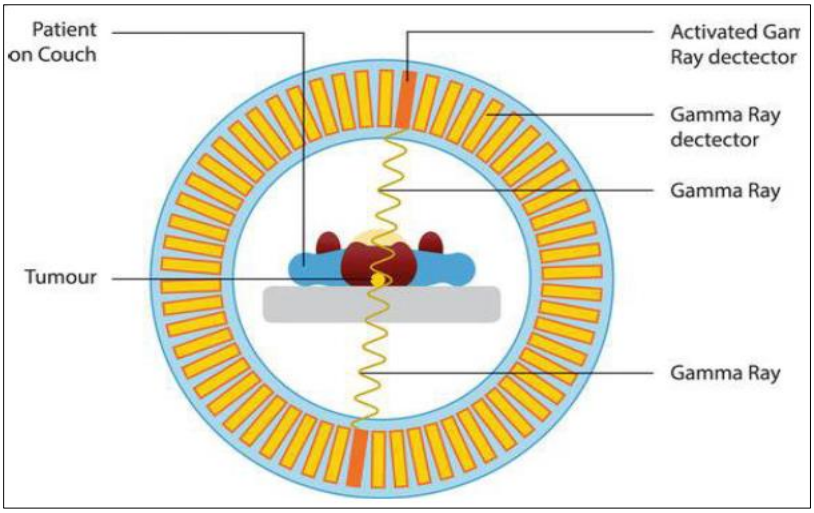

Figure1: the principle of PET-CT

The common uses of PET-CT

- Detect cancer and/or make a diagnosis.
- Determine whether a cancer has spread in the body.
- Staging of cancer which potentially can be treated radically.
- Establish baseline staging before commencing treatment.
- Determine if a cancer has returned after treatment.
- Evaluate prognosis.
- Assess tissue metabolism and viability.
- Map normal human brain and heart function.
- Assessing response to therapy.
- Evaluation of suspected disease recurrence, relapse and/or residual disease.

The Procedure of PET-CT

Ordinary X-ray exams pass X-rays through the body to create an image. The ***radioactive materials*** (F-18 fluorodeoxyglucose) ***injected the bloodstream intravenously, or may swallow it or inhale it as a gas***.

The material ***accumulates in the area*** under examination (tumor cells, that have a high metabolic rate), where it ***gives off gamma rays***. Special cameras ***detect this energy*** and, ***with the help of a computer, create pictures*** that detail how the organs and tissues ***look and function***.

Unlike other imaging techniques, ***nuclear medicine focuses on processes within the body***. These include ***rates of metabolism*** or levels of ***various other chemical activities***. Areas of ***greater intensity are called "hot spots***." These may show ***large concentrations*** of the radiotracer and where there is a ***high level of chemical or metabolic activity***. ***Less intense areas, or "cold spots,***" indicate a ***smaller concentration*** of radiotracer and ***less activity***.

The radioactive materials detection

The ***positron-emitting*** isotope administered to the patient undergoes ***β+ decay in the body***, with a ***proton being converted to a neutron***, a ***positron*** (the antiparticle of the electron, sometimes referred to as a ***β+ particle***), and ***a neutrino***. The ***positron travels a short distance and annihilates with an electron.*** The annihilation reaction ***results in the formation of two high energy photons*** which travel in diametrically ***opposite directions***. Each photon has an energy ***of 511 keV***. Two ***detectors at opposite*** ends facing each other detect these two photons traveling in ***opposite directions***, and the radioactivity is localized somewhere along a line between the two detectors. This is referred to as the ***line of response***, fig.(2).

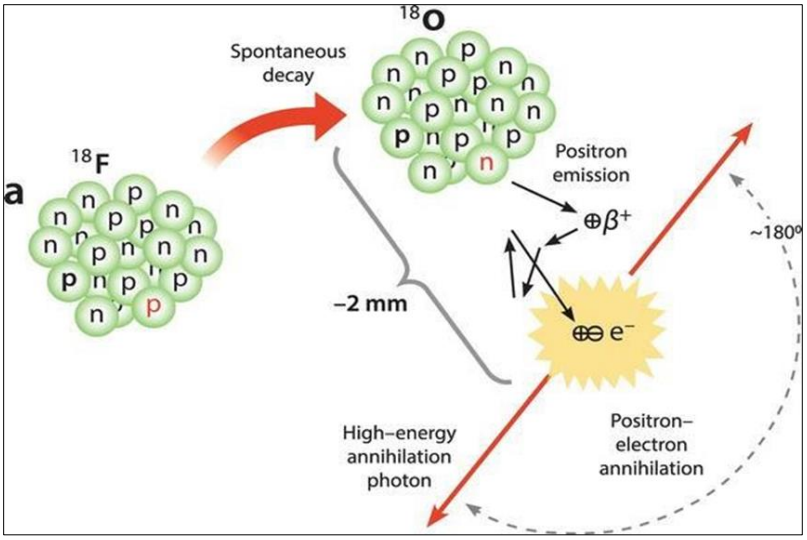

Figure 2. Beta decay causing the positron electron annihilation at 180 degree.

PET-scanner

These scanners are made up of the various ***many small detectors*** which are usually placed in ***adjacent rings around the patient***. The clinical PET system was having a ***ring diameter of 70–100 cm with the extent of 10–25 cm and made up to 25,000 detectors***. The single PET detector is ***made up of the very high-density scintillator crystal*** which is capable of ***converting the photons striking on the detector into light***. The crystals used

in the construction of PET scanner detectors are called ***scintillators***. Photons interact in the crystal, resulting in the ***emission of light***, which is collected by an array of ***photomultiplier tubes (PMT)***, where the light will be converted into an ***amplified electric signal*** (Figure 3).

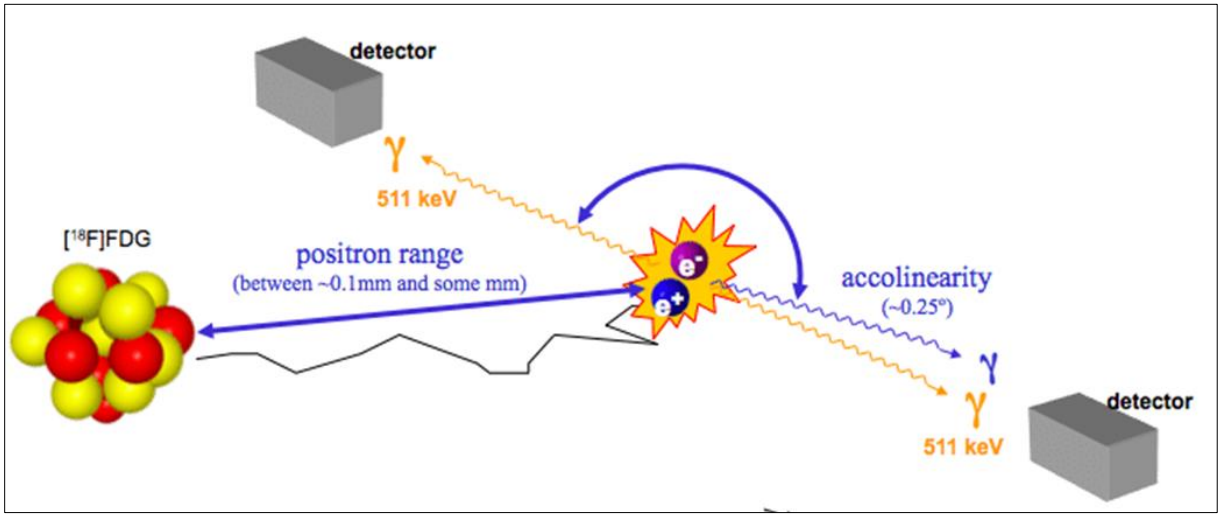

Figure 3: the principle of PET-CT

Single photon emission computed tomography (SPECT)

SPECT is ***a three-dimensional nuclear medicine imaging technique*** combining the information gained from ***scintigraphy with that of computed tomography***. This allows the ***distribution of the radionuclide to be displayed in a three-dimensional manner offering better detail, contrast and spatial information than planar nuclear imaging alone***. It is used to help diagnose ***seizures, strokes, stress fractures, infections, and tumors in the spine***. Shows how blood flows into and within tissues and organs.

Design of SPECT

SPECT machines combine an ***array of gamma cameras*** (ranging from ***one to four cameras***) which ***rotate around the patient on a gantry***. SPECT may be also ***combined with a separate CT machine in a form of*** *hybrid imaging*; single photon emission computed tomography-computerized tomography (SPECT-CT) mainly for the purposes of ***attenuation correction and anatomical localization***.

Principle of SPECT

Gamma cameras rotate around the patient providing spatial information on the distribution of the radionuclide within tissues. The use of ***multiple gamma cameras increases detector efficiency and spatial resolution***. The projection data obtained from the cameras are then ***reconstructed into three-dimensional images usually in axial slices***. When SPECT-CT is used, ***attenuation correction and higher resolution anatomical localization can be achieved.***

SPECT vs PET

Single photon emission computed tomography (SPECT) and positron emission tomography (PET) are ***nuclear medicine imaging techniques*** which provide ***metabolic and functional information unlike CT and MRI***.

They have been ***combined with CT and MRI*** to provide detailed ***anatomical and metabolic information***.

Positron emission tomography (PET):

- uses positron emitting radioisotope (tracer)
  - F-18 fluorodeoxyglucose (FDG)
- gives better contrast and spatial resolution (cf. SPECT)
- has a ring of multiple detectors

Single-photon emission computed tomography (SPECT):

- uses gamma emitting radioisotope (tracer):
  - technetium-99m
  - iodine-123
  - iodine-131
- gives poorer contrast and spatial resolution (cf. PET)
- usually one large crystal based detector

Advanced Technical CT Applications

CT Angiography

CT angiography is defined as ***CT imaging of blood vessels opacified by contrast media***. During contrast injection, the entire area of ***interest is scanned with spiral/helical CT*** and images are recorded when vessels are ***fully opacified to show arterial or venous phases of enhancement***.

CT angiography uses ***3D imaging principles to display images*** of the vasculature through ***intravenous injection of contrast media*** compared with those of intra- arterial angiograms. ***Four essential elements*** are ***patient preparation***; ***selection of acquisition parameters*** (total spiral/helical scan time, slice thickness, table speed) to optimize the imaging process; ***contrast media injection***; and ***postprocessing techniques and visualization tools*** such as algorithms to display 3D images, multiplanar reconstruction, maximum intensity projection.

Cardiac CT Imaging

To image the ***beating heart with the goal of reducing motion artifacts*** and a ***loss of both spatial and contrast resolution***, fast CT scanners such as the ***EBCT scanner*** were introduced to ***overcome these problems and produce good diagnostic images of the heart***. Alternatively, the patient's ***electrocardiogram (ECG)*** is used to provide ***prospective imaging***, ***after it is recorded at the same time with the scanning with stop and go scanners***. Subsequently, ***retrospective imaging*** has been developed where the ***ECG is correlated with image reconstruction in spiral/helical CT scanning***.

The recent technical developments in ***MSCT scanners and the introduction of the DSCT scanner*** open up a whole new avenue for successful imaging of the heart with ***excellent image quality based on meeting several technical requirements***. These include ***low-contrast resolution to visualize small differences in tissue contrast***, ***high-contrast***

resolution (spatial resolution) to visualize small structures in the anatomy scanned, to image ***fast-moving objects to reduce motion artifacts***. These have all been made possible by ***fast data acquisition and dedicated reconstruction algorithms***, such as the ***segmented (multiple) algorithms that "allow for merging synchronized transmission data from successive heart cycles***.

So, cardiac CT is routinely performed to gain knowledge about ***cardiac or coronary anatomy, to detect or diagnose coronary artery disease (CAD), to evaluate patency of coronary artery bypass grafts or implanted coronary stents***.

Artifacts

Several artifacts can potentially occur and include:

- motion artifact
  - cardiac motion
  - respiratory motion
  - gross patient motion
- partial volume averaging
- beam hardening
- metal or streak artifact
- slab or banding artifacts
- poor contrast enhancement
- artifacts from overlapping structures

CT Fluoroscopy

CT fluoroscopy, or ***continuous imaging***, depends on ***spiral/helical data acquisition methods, high-speed processing, and a fast image-processing algorithm for image reconstruction***.

In ***conventional CT, the time lag between data acquisition and image reconstruction makes realtime display of images impossible***. CT fluoroscopy allows for the ***reconstruction and display of images in real time with variable frame rates***.

CT fluoroscopy is based on three advances in CT technology:

1) Fast, continuous scanning made possible by ***spiral/helical*** scanning principles.
2) Fast image reconstruction made possible by special hardware performing quick calculations and a new image ***reconstruction algorithm***.
3) Continuous image display by use of ***cine mode*** at frame rates of ***two to eight images per second***.

Other support tools were developed to facilitate interventional procedures in CT fluoroscopy. One such tool, the ***Fluoro Assisted Computed Tomography System***, uses a unique ***flat-panel amorphous silicon digital detector coupled with an X-ray tube by a C-arm, which is a part of the CT gantry***.