Diseases of the Respiratory System: A Comprehensive Overview of Lung Diseases and Chest Trauma

The human respiratory system is a marvel of biological engineering, responsible for the complex exchange of oxygen and carbon dioxide vital for sustaining life. However, it is susceptible to a multitude of diseases that can disrupt its normal function.

I. Respiratory Diseases

The spectrum of respiratory diseases is vast and includes conditions that affect the upper and lower respiratory tracts, as well as the lung tissues themselves. Here, we will research into some of the most prevalent respiratory diseases:

Asthma:

a. A chronic condition characterized by the inflammation and narrowing of the airways.

b. Common symptoms include wheezing, coughing, chest tightness, and shortness of breath.

c. Triggers can include allergens, respiratory infections, and irritants.

d. Managed with medications that help open the airways and reduce inflammation.

Chronic Obstructive Pulmonary Disease (COPD):

a. An umbrella term encompassing chronic bronchitis and emphysema.

b. Primarily caused by smoking, long-term exposure to irritants, and genetic factors.

c. Symptoms include chronic cough, excess mucus production, and difficulty breathing.

d. Treatment focuses on symptom management, smoking cessation, and oxygen therapy in severe cases.

Pneumonia:

a. An infection that inflames the air sacs in one or both lungs.

b. Can be caused by bacteria, viruses, or fungi.

c. Symptoms include high fever, cough with mucus, and difficulty breathing.

d. Treatment varies based on the cause and may involve antibiotics, antiviral drugs, or antifungal medications.

Interstitial Lung Disease (ILD):

a. A group of disorders characterized by scarring (fibrosis) of the lungs' interstitium (the tissue surrounding the air sacs).

b. Results in decreased lung function and symptoms like dry cough and shortness of breath.

c. Causes include exposure to environmental toxins and certain medications.

d. Treatment options depend on the specific type of ILD and may include medications and oxygen therapy.

Obstructive Sleep Apnea (OSA):

a. A sleep disorder in which the upper airway becomes partially or completely blocked during sleep.

b. Common symptoms include loud snoring and daytime fatigue.

c. Treatment may involve lifestyle changes, such as weight loss, and the use of a continuous positive airway pressure (CPAP) device during sleep.

Tuberculosis (TB):

a. A bacterial infection caused by Mycobacterium tuberculosis.

b. Primarily affects the lungs but can affect other parts of the body.

c. Symptoms include a persistent cough, chest pain, and coughing up blood.

d. Requires a long course of antibiotics for treatment.

Cystic Fibrosis (CF):

a. A genetic disorder that affects the respiratory, digestive, and reproductive systems.

b. Results in the production of thick, sticky mucus, leading to recurrent lung infections and breathing difficulties.

c. Treatment involves airway clearance techniques, medications, and lung transplantation in severe cases.

Idiopathic Pulmonary Fibrosis (IPF):

a. A specific type of interstitial lung disease with no known cause.

b. Leads to progressive scarring of the lung tissue.

c. Symptoms include shortness of breath and a persistent dry cough.

d. No cure, but treatments can help manage symptoms and slow disease progression.

Pulmonary Hypertension:

a. High blood pressure in the pulmonary arteries, which carry blood from the heart to the lungs.

b. Causes strain on the heart and can lead to heart failure.

c. Symptoms include shortness of breath, fatigue, and chest pain.

d. Treatment includes medications to lower blood pressure in the lungs and improve heart function.

Sarcoidosis:

a. An inflammatory disease that can affect multiple organs, including the lungs.

b. Results in the formation of granulomas (clumps of inflammatory cells) in affected tissues.

c. Symptoms may include cough, shortness of breath, and fatigue.

d. Treatment varies and may include anti-inflammatory medications.

Pulmonary Embolism:

a. A blood clot in the pulmonary artery, which can block blood flow to the lungs.

b. Symptoms include sudden onset of chest pain, difficulty breathing, and a rapid heart rate.

c. Immediate medical attention is critical, and treatment often involves blood-thinning medications.

Bronchiectasis:

a. A chronic condition characterized by the widening and thickening of the airways.

b. Typically caused by recurrent infections or other conditions like cystic fibrosis.

c. Symptoms include a chronic cough with large amounts of mucus.

d. Treatment focuses on clearing mucus, managing infections, and bronchodilators.

Allergic Rhinitis:

a. Also known as hay fever, it's an allergic reaction to airborne allergens.

b. Symptoms include sneezing, runny or stuffy nose, and itchy or watery eyes.

c. Treatment includes allergen avoidance, antihistamines, and nasal corticosteroids.

Occupational Lung Diseases:

a. Result from exposure to harmful substances at the workplace.

b. Examples include asbestosis, silicosis, and byssinosis.

c. Prevention involves minimizing exposure to occupational hazards, and treatment may include supportive care.

Respiratory Distress Syndrome (RDS):

a. Common in premature infants and caused by underdeveloped lungs.

b. Symptoms include rapid and shallow breathing, grunting, and bluish skin.

c. Treatment involves providing oxygen and surfactant therapy to help the baby breathe.

Bronchiolitis:

a. A common respiratory infection in infants and young children, often caused by respiratory syncytial virus (RSV).

b. Symptoms include wheezing, rapid breathing, and cough.

c. Supportive care, such as hydration and oxygen therapy, is the main treatment.

Lung Abscess:

a. A pus-filled cavity in the lung, usually caused by a bacterial infection.

b. Symptoms include fever, productive cough, and chest pain.

c. Treatment involves antibiotics and drainage of the abscess in some cases.

Pleural Effusion:

a. Accumulation of excess fluid in the pleural space, the space between the lungs and the chest wall.

b. Can result from infections, heart failure, or malignancies.

c. Treatment may include draining the fluid and addressing the underlying cause.

Sudden Infant Death Syndrome (SIDS):

a. SIDS is the unexplained sudden death of an otherwise healthy infant, often during sleep.

b. While not a disease, it's a significant concern in infant care, and preventive measures include placing infants on their backs to sleep and creating a safe sleep environment.

II. Lung Masses

Lung masses, also known as pulmonary nodules, refer to abnormal growths within the lung tissue. These masses can be either benign (non-cancerous) or malignant (cancerous). Here's more information on lung masses:

Benign Lung Masses:

i. Benign lung masses are non-cancerous growths that can include hamartomas, granulomas, or benign tumors.

ii. They are often discovered incidentally during chest imaging for other reasons and may not cause symptoms.

iii. In most cases, benign masses do not require treatment unless they become large enough to cause symptoms or other complications.

Malignant Lung Masses (Lung Cancer):

i. Lung cancer is a major category of malignant lung masses, characterized by the uncontrolled growth of abnormal cells in the lungs.

ii. Common risk factors include smoking, exposure to carcinogens, and genetic factors.

iii. Symptoms may include a persistent cough, chest pain, shortness of breath, and unexplained weight loss.

iv. Treatment for lung cancer depends on the type and stage and may include surgery, chemotherapy, radiation therapy, targeted therapy, immunotherapy, or a combination of these treatments.

Lung Mass Evaluation:

i. Lung masses are often detected through imaging tests such as X-rays, CT scans, or PET scans.

ii. Further evaluation may involve biopsy procedures, such as bronchoscopy, needle biopsy, or surgical resection, to determine whether a mass is benign or malignant.

Management and Prognosis:

i. The management of lung masses is highly dependent on their nature and the patient's overall health.

ii. Early detection and intervention are essential for better outcomes in cases of malignant lung masses. Prognosis varies, with early-stage lung cancers having a better prognosis than advanced-stage cancers.

III. Chest Trauma

Chest trauma encompasses injuries to the chest wall, ribs, and the organs within the chest cavity, such as the heart, lungs, and major blood vessels. Here's more information on chest trauma:

Rib Fractures:

i. Rib fractures can occur due to blunt trauma, such as car accidents or falls.

ii. Symptoms include severe pain during breathing and movement, and sometimes a palpable lump at the fracture site.

iii. Treatment involves pain management, rest, and, in some cases, bracing to minimize discomfort during recovery.

Pneumothorax:

i. Pneumothorax is a condition in which air leaks into the space between the lung and the chest wall, causing the lung to collapse partially or completely.

ii. Symptoms include sudden sharp chest pain, difficulty breathing, and cyanosis (bluish skin).

iii. Treatment ranges from observation for small pneumothoraces to chest tube insertion for larger or more severe cases to remove air and re-expand the lung.

Lung Contusions:

i. Lung contusions often result from a severe blow to the chest and can damage lung tissue.

ii. Symptoms include chest pain, difficulty breathing, and coughing up blood-tinged sputum.

iii. Treatment is supportive and may involve oxygen therapy and pain management.

Flail Chest:

i. A flail chest occurs when a segment of the ribcage breaks, causing a portion of the chest wall to move independently from the rest of the chest.

ii. This condition can lead to impaired ventilation and can be life-threatening if not managed promptly.

iii. Treatment may involve mechanical ventilation and stabilization of the chest wall.

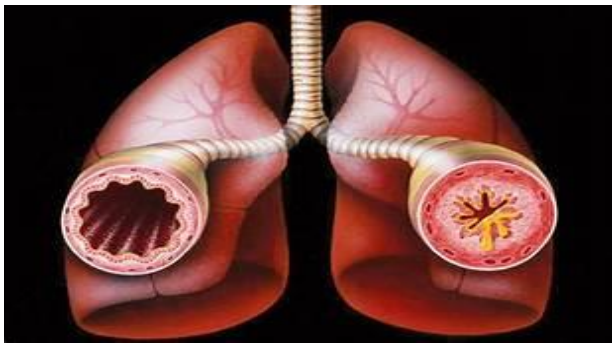



Hyperinflation in acute asthma. Chest radiograph of a young woman who presented to intensive care unit (ICU) with severe asthma showing hyperinflation

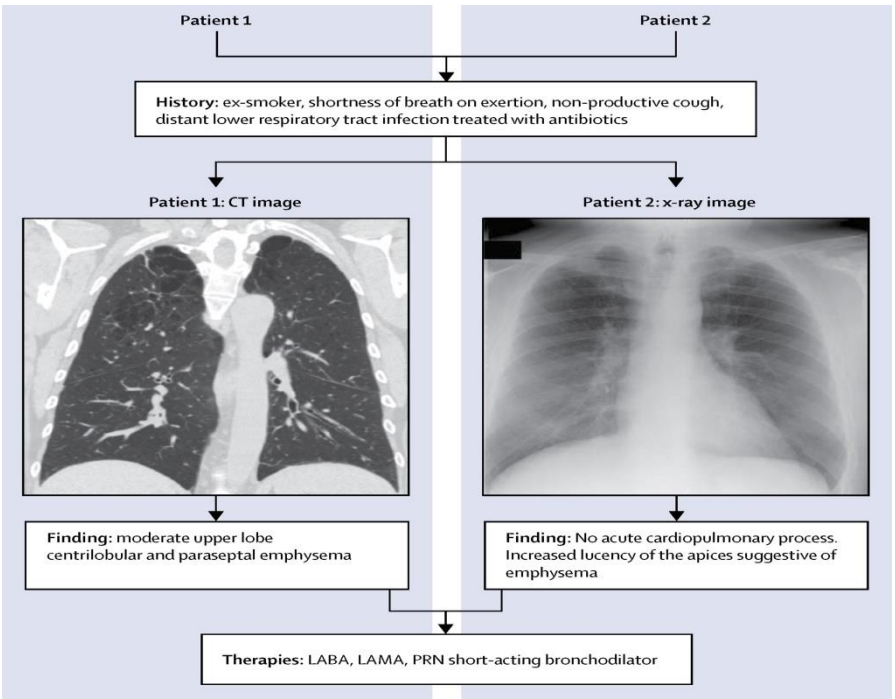

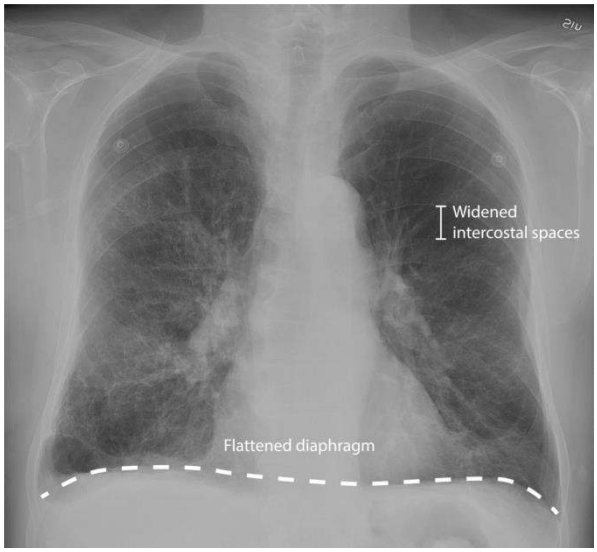

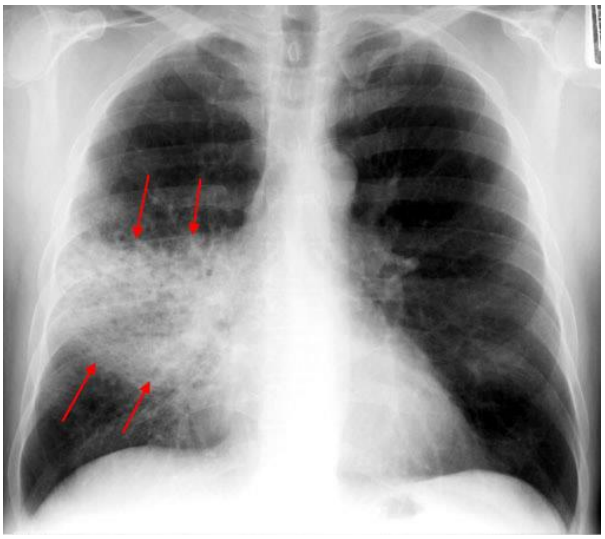

Pneumonia



Chest radiograph (left) and representative axial computed tomography (CT) image (right). These illustrate a left lower lobe retrocardiac opacity with interstitial markings on chest radiograph and a small infiltrate on axial CT images with mild bronchiolitis.



Obstructive Sleep Apnea (OSA)



A right upper lobe cavitary lesion on a chest x-ray of a patient with tuberculosis.



Idiopathic Pulmonary Fibrosis (IPF)

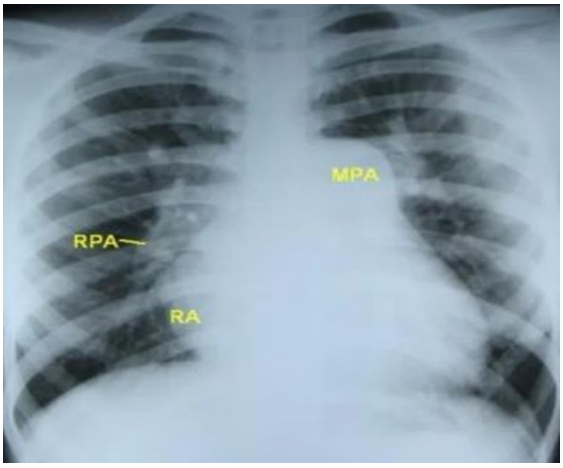

The striking feature in this chest X-ray is the remarkably prominent main pulmonary artery segment (MPA), which appears to be aneurysmally dilated.



Varicose and cystic bronchiectasis with mucus plugging in upper lobes.

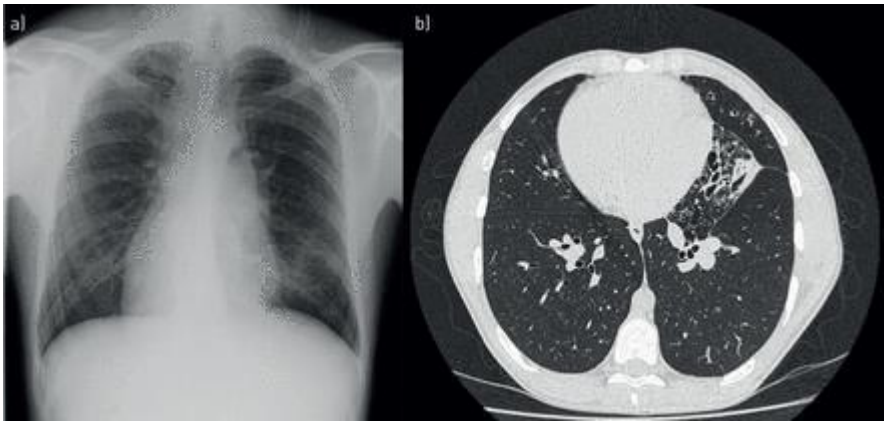

a) Chest radiograph showing dextrocardia. b) High-resolution computed tomography showing cylindrical bronchiectasis in the lingula.

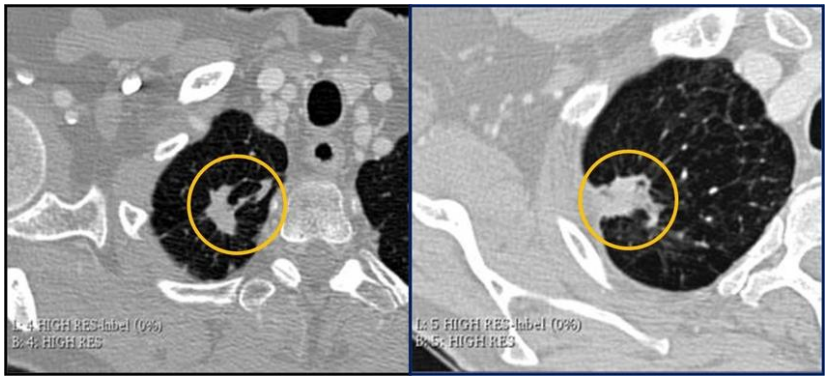

Benign (left) and malignant (right) nodules of the lung in CT images.

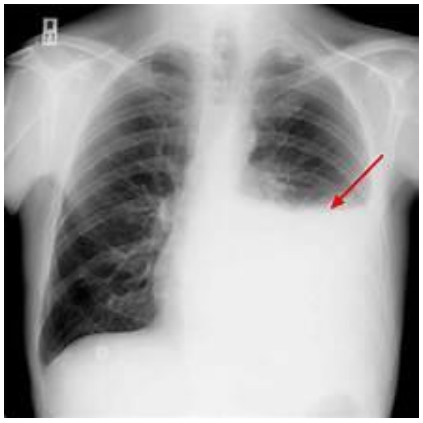

Pleural Effusion:



Lung Abscess:

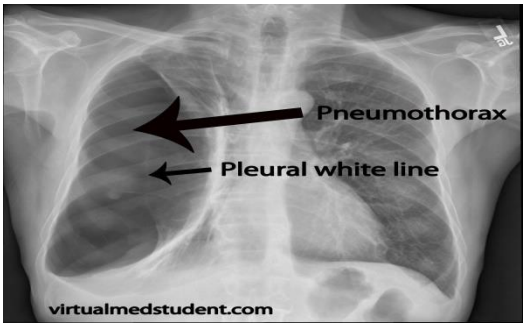

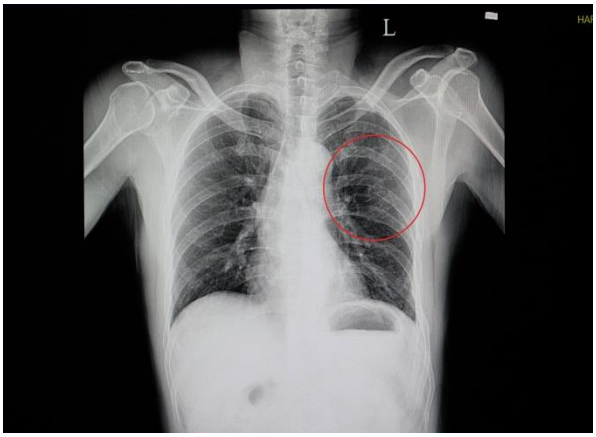

Ribs fracture

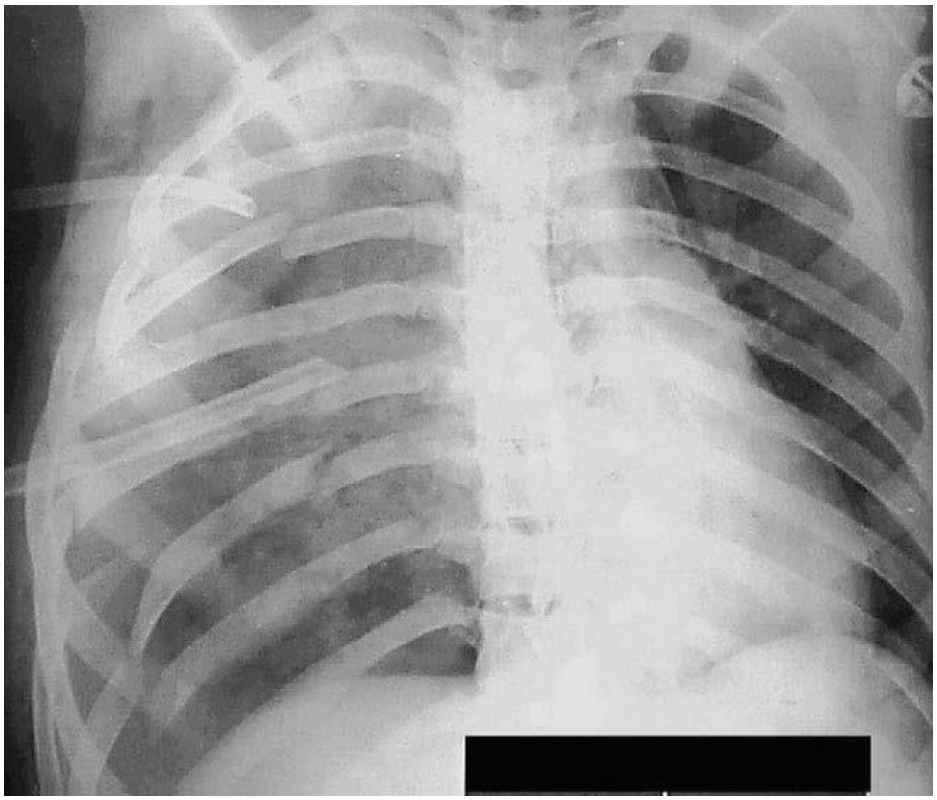

Flail chest