ECG

Electrocardiogram or Electrocardiograph

What to expect from ECG?

Clinical diagnosis depends mainly on a patient history and clinical examination. the ECG can provide evidence to support a diagnosis and in some cases it is crucial for patient management.

The electricity of the heart:

The heart is consist of two atrium and two ventricles. although the heart has four chambers anatomically but from the electrical point of view it can be thought of having only two ,because the two atrium contract together and then the two ventricles contract together.

The contraction of heart associated with electrical changes called depolarization and these electrical changes can be detected by electrodes attached to the surface of the body.

The electrical activity of heart started from special area of the right atrium called sinoatrial node (SA node). Then electrical activity spread through the atrial muscle fibers and reach to special area in ventricle called (AV node).thereafter the electrical activity travels very rapidly through conduction tissue called the bundle of His which then divided into right and left bundle within ventricle.

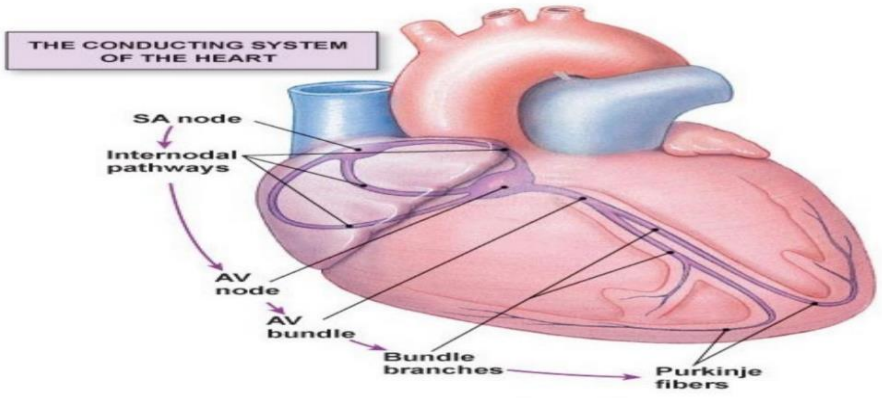

Conduction System Structures and Functions	
Structure	**Function and Location**
Sinoatrial (SA) node	Dominant pacemaker of the heart, located in upper portion of right atrium. Intrinsic rate 60–100 bpm.
Internodal pathways	Direct electrical impulses between SA and AV nodes.
Atrioventricular (AV) node	Part of AV junctional tissue. Slows conduction, creating a slight delay before impulses reach ventricles. Intrinsic rate 40–60 bpm.
Bundle of His	Transmits impulses to bundle branches. Located below AV node.
Left bundle branch	Conducts impulses that lead to left ventricle.
Right bundle branch	Conducts impulses that lead to right ventricle.
Purkinje system	Network of fibers that spreads impulses rapidly throughout ventricular walls. Located at terminals of bundle branches. Intrinsic rate 20–40 bpm.

Electrophysiology	
Action	**Effect**
Depolarization	The electrical charge of a cell is altered by a shift of electrolytes on either side of the cell membrane. This change stimulates muscle fiber to contract.
Repolarization	Chemical pumps re-establish an internal negative charge as the cells return to their resting state.

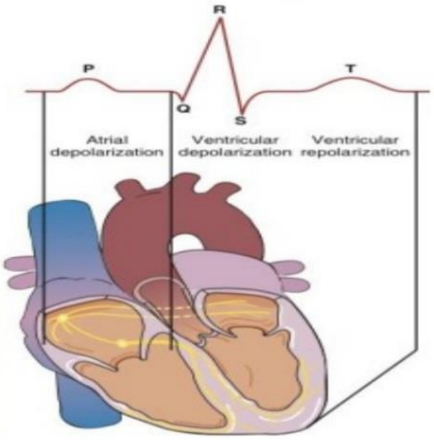

Depolarization and repolarization of the heart.

♥ **Clinical Tip:** Mechanical and electrical functions of the heart are influenced by proper electrolyte balance. Important components of this balance are sodium, calcium, potassium, and magnesium.

The rhythm of the heart:

Rhythm mean the part of the heart which is controlling the electrical activity.

The normal heart rhythm with electrical activation beginning in the SA node and called sinus rhythm

In some cases of heart disease the electrical activity begin in area other than SA node.

The shape of ECG:

The contraction of the atria is associated with the ECG wave called (p wave) and it is small because muscle mass of the atrium is small.

The ventricular mass is large and so the ventricular contraction result in a complex wave (QRS complex).

The (T wave) of the ECG is associated with return of the ventricular muscle to its resting electrical state.So we have multiple waves in ECG are:

P wave ……atrial contraction

QRS complex ….ventricular contraction

T wave ….ventricular relaxation.

Q wave …is pathological wave occur only in some disease.

And we had 2 interval between the above waves are:

PR interval ….. between the p wave and QRS

ST interval …..between S wave and T wave.

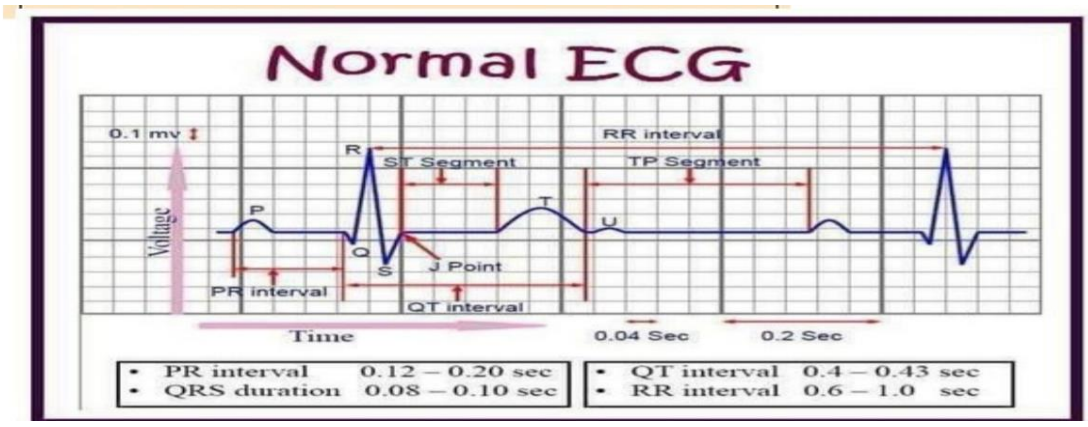

ECG machine record changes in electrical activity by drawing a trace on a moving paper strip. All ECG machine run at standard rate and use paper with standard sized squares

The ECG paper consist of large squares and each large square contain 5 small squares

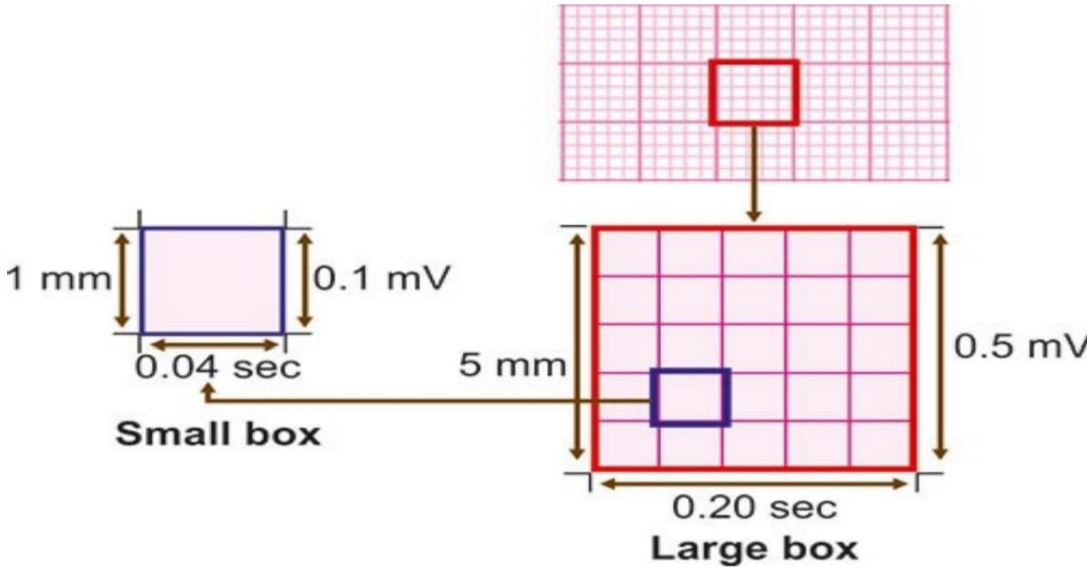

The horizontal axis represent time and the vertical axis represent voltage.

The device speed is 25 mm/sec

A small box is 1mm * 1mm and represent 0.1 m V * 0.04 SECOND.

A large box is 5mm * 5mm and represent 0.5 m V *0.20 SECONDS