الجامعة التقنية الوسطى
كلية التقنيات الصحية والطبية/ بغداد

قسم: تقنيات الاشعة المادة: التصوير بالرنين المغناطيسي
المرحلة: الرابعة

العنوان: **Title: MRI of the orbits and Sella turcica.**

اسم المحاضر: **Name of the instructor:**

م. حيدر عبد القادر طاهر

lecturer. Haydar Abdul Kader Taher

الفئة المستهدفة: **Target population:**

طلبه المرحلة الرابعة في قسم تقنيات الاشعة

المقدمة: Introduction:

MRI technologist need to learn about orbits MRI for several reasons:

Performing specialized exams: Orbits MRI is a specialized imaging technique that focuses on the structures of the eye sockets and surrounding areas. MRI technologist need to learn the specific protocols and techniques for performing orbits MRI exams

Understanding anatomy and pathology: Orbits MRI can help visualize structures such as the eyeballs, optic nerves, and extraocular muscles. By learning about orbits MRI, technologist can better understand the anatomy and pathology of the eye and surrounding structures

Patient positioning and safety: Orbits MRI requires specific patient positioning to ensure optimal image quality and patient comfort. MRI technologist need to learn how to position patients for orbits MRI exams and ensure their safety during the procedure

Interpreting MRI results: MRI technologist need to be able to interpret orbits MRI results accurately and communicate these results effectively to physicians and other healthcare professionals. Understanding the specific features and findings of orbits MRI can help technologist in this process

Collaboration with radiologists and ophthalmologists: Orbits MRI is often performed in collaboration with radiologists and ophthalmologists to evaluate and diagnose various eye and orbital conditions. By understanding orbits MRI, technologist can effectively contribute to the multidisciplinary team and provide valuable insights during the imaging process

Scientific Content:

Common indications

•• Proptosis

•• Visual disturbance

•• Evaluation of orbital or ocular mass lesions

Equipment

•• Small surface coil for globe and orbit

•• Quadrature head coil or multi-coil array coil for orbital apex, chiasm and intracranial optic pathways

•• Immobilization straps and foam pads

•• Earplugs/headphones

Patient positioning

The patient lies supine on the examination couch. Both orbits are usually examined at the same time. If surface coils are used, these are placed over each orbit but

should not touch the patient. Special holders are often provided by the manufacturers to enable the coils to be placed anteriorly over the eyes. Ensure that the receiving side of the coils faces the orbits, that is, towards the table. The patient assumes a fixed gaze, straight ahead, with the eyes open. This enables the patient to focus and keeps the eyes still, thereby reducing motion artefact. Any eye make-up is removed prior to the examination as this causes image artefact and patient discomfort, especially if it contains metal.

The patient is positioned so that the longitudinal alignment light lies in the midline, and the horizontal alignment light passes through the orbits.

If surface coils are used, this corresponds to the center of the coils. Straps and foam pads are used for immobilization.

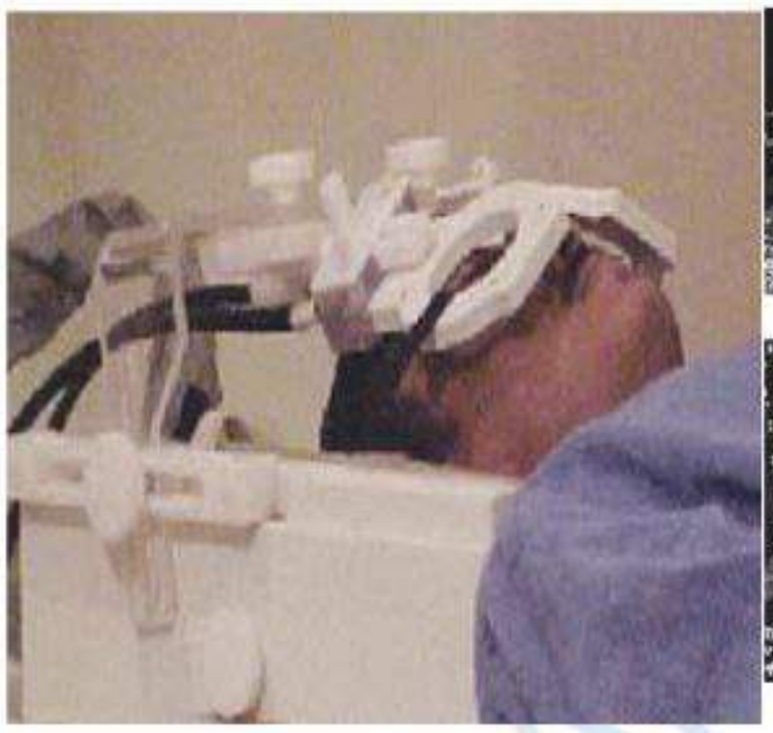



Sagittal image of the orbit and optic nerve showing the correct placement of axial oblique slices parallel to the optic nerve

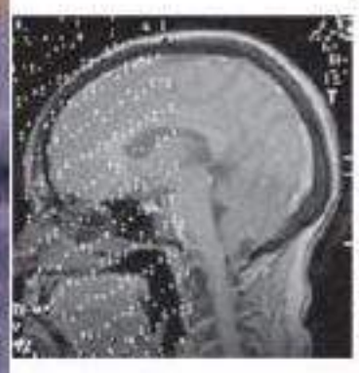

Sagittal image showing correct placement of coronal slices

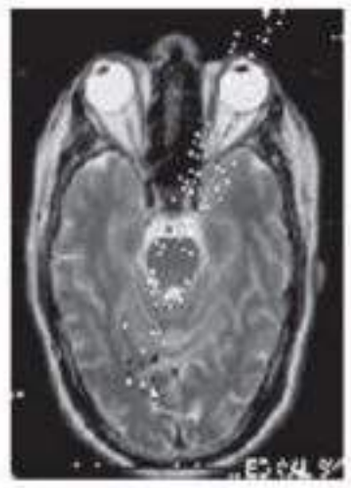

Axial oblique image of the orbits clearly demonstrating the lens of eye, the globe, the optic nerves and the optic chiasma

Main sequences of orbit MRI sequences:

1-T1-Weighted Axial Imaging:

Parameters:

Slice thickness: 3-5 mm

Use: Provides detailed anatomical information of the orbital structures, including the eye, extraocular muscles, and optic nerves. Useful for detecting tumors, inflammation, and trauma.

2- T2-Weighted Axial Imaging:

Parameters:

Slice thickness: 3-5 mm

Use: Highlights soft tissues and helps identify conditions such as edema, inflammation, and lesions in the orbital region.

3-T1-Weighted Post-Contrast Imaging:

Parameters:

Slice thickness: 3-5 mm

Contrast agent: Gadolinium-based contrast agent

Use: Enhances visualization of lesions, vascular structures, and inflammatory changes in the orbits. Valuable for detecting and characterizing tumors and evaluating vascular abnormalities.

4-Fat-Suppressed Imaging:

Parameters:

Slice thickness: 3-5 mm

Use: Differentiates between fat and non-fat components in the orbits, aiding in the assessment of lesions, especially when evaluating lesions like dermoid cysts or lipomas.

5-Diffusion-Weighted Imaging (DWI):

Parameters:

Slice thickness: 3-5 mm

b-values: Typically, 0 and 1000 sec/mm²

Use: Assesses tissue cellularity and may help distinguish between different orbital lesions, including tumors and inflammatory conditions.

6-<u>Dynamic Contrast-Enhanced Imaging</u>:

Parameters:

Slice thickness: 3-5 mm

Temporal resolution: 2-5 seconds

Contrast agent: Gadolinium-based contrast agent

Use: Evaluates perfusion and blood flow in the orbits, helping to differentiate between benign and malignant lesions and assessing vascular conditions.

7-<u>Fat-Saturation Sequences</u>:

Parameters:

Utilizes fat saturation techniques

Use: Helps in evaluating fat-containing lesions within the orbits, such as lipomas, and provides better contrast between fat and non-fat tissues.

8-<u>Orbital MRI Angiography</u> (MRA):

Parameters:

Utilizes time-of-flight or contrast-enhanced MRA techniques

Use: Visualizes the blood vessels within the orbits, assisting in the detection of vascular lesions, aneurysms, or other vascular abnormalities.

These MRI sequences and parameters are tailored for assessing the orbits and surrounding structures, helping diagnose a range of conditions, including tumors, inflammatory diseases, vascular abnormalities, and trauma. The choice of sequences may depend on the specific clinical indications and the suspected

pathology. Consultation with a radiologist or ophthalmologist is important for determining the appropriate orbit MRI protocol.

References: المصادر:

Handbook of MRI Technique Catherine Senior 5TH EDITION 2022
Step by step MRI Jaganmohan Reddy v parsed

Mriquestions.com

Essential of body MRI 2018

الجامعة التقنية الوسطى

كلية التقنيات الصحية والطبية/ بغداد

قسم: تقنيات الاشعة المادة: التصوير بالرنين المغناطيسي
المرحلة: الرابعة

Title: MRI of the cervical spinal cord. **العنوان:**

Name of the instructor: **اسم المحاضر:**

م. حيدر عبد القادر طاهر

lecturer. Haydar Abdul Kader Taher