pathology. Consultation with a radiologist or ophthalmologist is important for determining the appropriate orbit MRI protocol.

References: المصادر:

Handbook of MRI Technique Catherine Senior 5TH EDITION 2022
Step by step MRI Jaganmohan Reddy v parsed

Mriquestions.com

Essential of body MRI 2018

الجامعة التقنية الوسطى

كلية التقنيات الصحية والطبية/ بغداد

قسم: تقنيات الاشعة المادة: التصوير بالرنين المغناطيسي
المرحلة: الرابعة

Title: MRI of the cervical spinal cord. **العنوان:**

Name of the instructor: **اسم المحاضر:**

م. حيدر عبد القادر طاهر

lecturer. Haydar Abdul Kader Taher

Target population: الفئة المستهدفة:

طلبه المرحلة الرابعة في قسم تقنيات الاشعة

Introduction: المقدمة:

learning about cervical spine MRI is essential for MRI technologist to perform MRI exams effectively, interpret MRI results accurately, ensure patient safety, understand anatomy and pathology, and collaborate with other healthcare professionals. MRI technologist can acquire this knowledge through specialized training programs, continuing education courses, and on-the-job experience.

Scientific Content: المحتوى العلمي:

Common indications

- Cervical myelopathy
- Cervical radiculopathy
- Cervical cord compression or trauma
- Assessment of extent of spinal infection or tumour
- Diagnosis of Chiari malformation and cervical syrinx. (Total extent of syrinx must be determined. Whole spine imaging may be necessary.)
- MS plaques within the cord

Equipment

- Posterior cervical neck coil/volume neck coil/multi-coil array spinal coil
- Immobilization pads and straps
- Pe gating leads if required
- Earplugs/headphones

YAHYA ABDUL KA

Patient positioning

The patient lies supine on the examination couch with the neck coil placed under or around the cervical region. Coils are often moulded to fit the back of the head and neck so that the patient is automatically centred to the coil. If a flat coil is used, placing supporting pads under the shoulders flattens the curve of the cervical spine so that it is in closer proximity to the coil. The coil should extend from the base of the skull to the sternoclavicular joints in order to include the whole of the cervical spine.

The patient is positioned so that the longitudinal alignment light lies in the midline, and the horizontal alignment light passes through the level of the hyoid bone (this can usually be felt above the thyroid cartilage/Adam's apple). The patient's head is immobilized with foam pads and retention straps. Pe gating leads are attached if required.



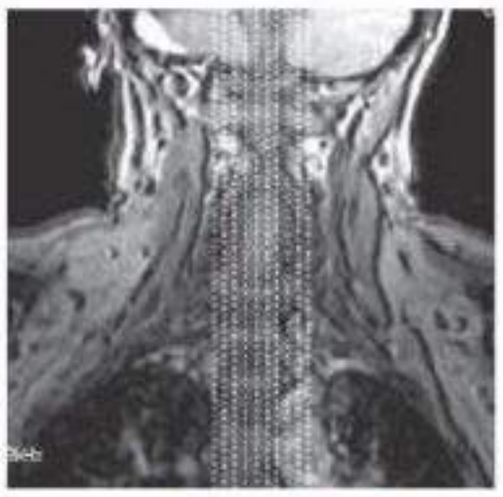

Coronal localizer for sagittal slices



Sagittal C-spine showing axial-oblique slice positions parallel to each disc spaces

Main sequences of cervical spine MRI

1-Sagittal T1-Weighted Imaging:

Parameters:

Slice thickness: 3-5 mm

Use: Provides an anatomical overview of the cervical spine, including the vertebral bodies and intervertebral discs. Useful for assessing degenerative changes and spinal alignment.

2-Sagittal T2-Weighted Imaging:

Parameters:

Slice thickness: 3-5 mm

Use: Highlights soft tissues, including the spinal cord and surrounding structures. Helps in identifying disc herniations, spinal stenosis, and ligamentous injuries.

2-Axial T1-Weighted Imaging:

Parameters:

Slice thickness: 3-5 mm

Use: Provides detailed cross-sectional images of the cervical spine, useful for assessing the spinal cord and nerve roots.

3-Axial T2-Weighted Imaging:

Parameters:

Slice thickness: 3-5 mm

Use: Visualizes the spinal cord and nerve roots in axial sections, aiding in the detection of pathology such as disc herniations and spinal cord compression.

3-Sagittal Short Tau Inversion Recovery (STIR) Imaging:

Parameters:

Slice thickness: 3-5 mm

Use: Suppresses fat signal and enhances the visibility of edema and inflammatory changes, making it valuable for detecting bone marrow disorders and infection.

4-Diffusion-Weighted Imaging (DWI):

Parameters:

Slice thickness: 3-5 mm

b-values: Typically 0 and 1000 sec/mm²

Use: Evaluates tissue diffusion characteristics, which can help in identifying acute conditions such as infections, abscesses, or acute ischemia.

5-Gradient Echo (GRE) Sequences:

Parameters:

Slice thickness: 3-5 mm

Use: Sensitive to blood products and hemorrhage, making it useful for detecting vascular abnormalities or hemosiderin deposits.

6-3D T1-Weighted Imaging with Fat Saturation:

Parameters:

High-resolution isotropic imaging

TR and TE similar to T1-weighted sequences

Use: Provides excellent anatomical detail and helps in evaluating vascular structures and postoperative changes in the cervical spine.

These MRI sequences are tailored to assess the cervical spine and surrounding structures, allowing for the diagnosis and evaluation of various conditions, including disc herniations, spinal cord compression, infections, trauma, and degenerative changes. The selection of sequences may vary based on clinical indications and the suspected pathology, and consultation with a radiologist or spine specialist is essential for determining the appropriate cervical spine MRI protocol

YDAR ABDUL KA

References: المصادر:

Handbook of MRI Technique Catherine Senior 5TH EDITION 2022
Step by step MRI Jaganmohan Reddy v parsed

Mriquestions.com

Essential of body MRI 2018

الجامعة التقنية الوسطى

كلية التقنيات الصحية والطبية/ بغداد

قسم: تقنيات الاشعة المادة: التصوير بالرنين المغناطيسي
المرحلة: الرابعة

Title: MRI of the thoracic and lumbar spine. **العنوان:**

Name of the instructor: **اسم المحاضر:**

م. حيدر عبد القادر طاهر

lecturer. Haydar Abdul Kader Taher

Target population: **الفئة المستهدفة:**

طلبه المرحلة الرابعة في قسم تقنيات الاشعة

Introduction: المقدمة:

Dorsal and lumbar spine MRI is an important imaging technique that MRI technologist need to learn about for several reasons:

- It is a common MRI procedure. Dorsal and lumbar spine MRIs are among the most common MRI procedures performed. This is because the lower back is a common site of pain and injury.
- It is a complex procedure. Dorsal and lumbar spine MRI can be a complex procedure, as it requires the patient to be positioned in a specific way and the MRI technician to be able to identify and image a variety of anatomical structures.
- It is important for diagnosing a variety of conditions. Dorsal and lumbar spine MRI can be used to diagnose a variety of conditions, including disc herniations, spinal stenosis, spinal cord injuries, and tumors.
- It is important for monitoring the course of treatment. Dorsal and lumbar spine MRI can be used to monitor the course of treatment for a variety of conditions, such as disc herniations and spinal stenosis.

Scientific Content: المحتوى العلمي:

Thoracic Spine

Common indications

- Thoracic disc disease
- Thoracic cord compression
- Visualization of a MS plaque in the thoracic cord
- Thoracic cord tumour
- To visualize the inferior extent of cervical syrinx

Equipment

- Posterior spinal coil/multi-coil array spinal coil
- Pe gating leads if required
- Earplugs/headphones

Patient positioning

The patient lies supine on the examination couch with the spinal coil extending from the top of the shoulders to the lower costal margin to ensure total coverage of the thoracic spine and conus. The patient is positioned so that the longitudinal alignment light lies in the midline, and the horizontal alignment light passes through the centre of the coil, which correspondsapproximately to the level of the fourth thoracic vertebra. Pe gating leads are attached if required.

Lumbar spine

Common indications

- Disc prolapse with cord or nerve root compression
- Spinal dysraphism (to assess cord termination, syrinx, diastematomyelia)
- Discitis
- Evaluation of the conus in patients with appropriate symptoms
- Failed back syndrome
- Arachnoiditis

Equipment

- Posterior spinal coil/multi-coil array spinal coil
- Foam pads to elevate the knees
- Earplugs/headphones

Patient positioning

The patient lies supine on the examination couch with their knees elevated over a foam pad, for comfort and to flatten the lumbar curve so that the spine lies nearer to the coil. The coil should extend from the xiphisternum to the bottom of the sacrum for adequate coverage of the lumbar region. The patient is positioned so that the longitudinal alignment light lies in the midline, and the horizontal alignment light passes just below the lower costal margin, which corresponds to the third lumbar vertebra. Depending on the particular coil configuration, the patient may be placed either head first or feet first. If the patient is anxious or claustrophobic, when/if possible, the feet-first position may be better tolerated.





Coronal localizer for sagittal slices



Sagittal image of the lumbar spine showing axial oblique slice prescription



Sagittal localizer for coronal slices



ɔronal localizer for sagittal slices



Sagittal image of the dorsal spine showing axial oblique slice positions parallel to each disk space

Main MRI sequences of thoracic and lumbar spine:

Thoracic Spine Sequences:

1. **Sagittal T1-Weighted Imaging**:
    - Parameters:
        - Slice thickness: 3-5 mm
    - Use: Provides an anatomical overview of the thoracic spine, including vertebral bodies and intervertebral discs. Useful for assessing degenerative changes and spinal alignment.

2. **Sagittal T2-Weighted Imaging**:
    - Parameters:
        - Slice thickness: 3-5 mm
    - Use: Highlights soft tissues, spinal cord, and surrounding structures. Helps identify disc herniations, spinal stenosis, and ligamentous injuries.

3. **Axial T1-Weighted Imaging**:
    - Parameters:
        - Slice thickness: 3-5 mm
    - Use: Provides cross-sectional images of the thoracic spine, aiding in the assessment of the spinal cord and nerve roots.

4. **Axial T2-Weighted Imaging**:
    - Parameters:
        - Slice thickness: 3-5 mm
    - Use: Visualizes the spinal cord and nerve roots in axial sections, helping to detect pathology such as disc herniations and spinal cord compression.

5. **Sagittal Short Tau Inversion Recovery (STIR) Imaging**:
    - Parameters:
        - Slice thickness: 3-5 mm
    - Use: Suppresses fat signal and enhances the visibility of edema and inflammatory changes, useful for detecting bone marrow disorders and infection.

Lumbar Spine Sequences:

1. **Sagittal T1-Weighted Imaging**:
    - Parameters (similar to thoracic spine):
    - Use: Provides an anatomical overview of the lumbar spine, including vertebral bodies and intervertebral discs. Useful for assessing degenerative changes and spinal alignment.

2. **Sagittal T2-Weighted Imaging**:
    - Parameters (similar to thoracic spine):
    - Use: Highlights soft tissues, spinal cord, and surrounding structures. Helps identify disc herniations, spinal stenosis, and ligamentous injuries.

3. **Axial T1-Weighted Imaging**:
    - Parameters (similar to thoracic spine):
    - Use: Provides cross-sectional images of the lumbar spine, aiding in the assessment of the spinal cord and nerve roots.
    -

4. **Axial T2-Weighted Imaging**:
    - Parameters (similar to thoracic spine):
    - Use: Visualizes the spinal cord and nerve roots in axial sections, helping to detect pathology such as disc herniations and spinal cord compression.

5. **<u>Sagittal Gradient Echo (GRE) Imaging</u>**:
    - Parameters:
        - Slice thickness: 3-5 mm
    - Use: Sensitive to blood products and hemorrhage, making it useful for detecting vascular abnormalities or hemosiderin deposits.

6. **<u>3D T1-Weighted Imaging with Fat Saturation</u>**:
    - Parameters:
        - High-resolution isotropic imaging
        - TR and TE similar to T1-weighted sequences
    - Use: Provides excellent anatomical detail and helps in evaluating vascular structures and postoperative changes in the lumbar spine.

These MRI sequences are tailored to assess the thoracic and lumbar spine and surrounding structures, allowing for the diagnosis and evaluation of various conditions, including disc herniations, spinal stenosis, infections, tumors, and degenerative changes. The selection of sequences may vary based on clinical indications and the suspected pathology, and consultation with a radiologist or spine specialist is essential for determining the appropriate MRI protocol.

<u>References</u>:

<u>المصادر</u>:

Handbook of MRI Technique Catherine Senior 5TH EDITION 2022
Step by step MRI Jaganmohan Reddy v parsed

Mriquestions.com

Essential of body MRI 2018