الجامعة التقنية الوسطى

كلية التقنيات الصحية والطبية/ بغداد

قسم: تقنيات الاشعة المادة: التصوير بالرنين المغناطيسي

المرحلة: الرابعة

Title: MRI of the shoulder joint. **العنوان:**

Name of the instructor: **اسم المحاضر:**

م. حيدر عبد القادر طاهر

lecturer. Haydar Abdul Kader Taher

Target population: **الفئة المستهدفة:**

طلبه المرحلة الرابعة في قسم تقنيات الاشعة

Introduction: المقدمة:

MRI of the shoulder is an important imaging technique that MRI technicians need to learn for several reasons:

1. **Detailed imaging of shoulder structures: MRI of the shoulder provides detailed images of structures within the shoulder joint, including bones, tendons, muscles, and vessels, from any angle**

. This allows for a comprehensive evaluation of the shoulder and its surrounding tissues.

2. **Diagnosing and evaluating various conditions: MRI is an excellent choice for examining the shoulder joint and can be used to diagnose or evaluate degenerative joint disorders, fractures, rotator cuff tears, injuries to the biceps tendon, damage to the glenoid labrum, and more**

It can also help in the assessment of post-surgical progress.

3. **Differentiating between normal and abnormal findings: MRI can help differentiate between normal and abnormal shoulder structures, aiding in the diagnosis of various conditions such as rotator cuff tendinitis, frozen shoulder, tumors, labral tears, and cysts**
4. **Guiding treatment decisions: The information obtained from a shoulder MRI can help surgeons decide if surgery is needed and assist in planning the appropriate treatment for the patient**
5. **No radiation exposure: MRI uses no radiation, making it a safe imaging option for patients**

HAYDAR ABDULKADER

Pretest: الاختبار القبلي:

How to use the MRI shoulder as guidelines treatment dictions

Scientific Content: المحتوى العلمي:

Common indications

•• Evaluation of shoulder pain
•• Diagnosis of impingement syndrome
•• Suspected rotator cuff tear
•• Evaluation of recurrent dislocation (instability, subluxation, dislocation)
•• Hill–Sachs lesion, Bankart lesion, labrum lesion
•• Frozen shoulder syndrome

Equipment

•• Dedicated shoulder coil or flexible surface coil
•• Immobilization pads and straps
•• Earplugs/headphones

HAYDAR ABDUL KADER

Patient positioning

The patient lies supine with the arms resting comfortably by the side. Slide the patient across the table to bring the shoulder under examination as close as possible to the centre of the bore. Relax the shoulder to remove any upward 'hunching'. The arm to be examined is strapped to the patient, with the thumb up (neutral position) and padded so that the humerus is horizontal. Place the coil to cover the humeral head and the anatomy superior and medial to it. If a surface or flexible coil is used, care must be taken to ensure that the flat surface of the coil is parallel to the Z axis when it is placed over the humeral head (Figure 1.1). Centre the FOV on the middle of the glenohumeral joint. Patient and coil immobilization are essential for a good result. If possible, instruct the patient to breathe abdominally rather than with the thorax and place sandbags on the upper chest. This reduces movement artefact. Instruct the patient not to move the hand during sequences. The patient is positioned so that the longitudinal alignment light and the horizontal alignment light pass through the shoulder joint.



Patient Position-Flex coil

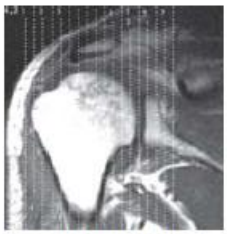

Coronal localizer for sagittal slices



Coronal localizer for axial slices

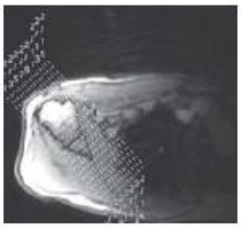

Axial localizer to obtain oblique coronal slices

Common Shoulder MRI Sequences:

1. T1-Weighted Imaging:
    - Parameters:
        - Slice thickness: 3-4 mm
        - TR (Repetition Time): 400-800 ms
        - TE (Echo Time): 10-20 ms
    - Use: Provides detailed anatomical information and helps visualize the structures within the shoulder joint, including bones, tendons, and ligaments. T1-weighted images are good for assessing anatomy.

HAYDAR ABDU KADER

2. T2-Weighted Imaging:
    - Parameters:
        - Slice thickness: 3-4 mm
        - TR: 2000-5000 ms
        - TE: 80-120 ms
    - Use: Highlights differences in tissue water content and is valuable for assessing soft tissues within the shoulder, including muscles, tendons, and ligaments. T2-weighted images are useful for detecting inflammation and pathology.

3. Proton Density (PD)-Weighted Imaging:
    - Parameters:
        - Slice thickness: 3-4 mm
        - TR: 1500-3000 ms
        - TE: 20-40 ms
    - Use: Provides a balance between T1 and T2 contrast and is often used to assess the shoulder's soft tissues, including tendons and ligaments.
4. Gradient Echo (GRE) Sequences:
    - Parameters:
        - Slice thickness: 3-4 mm
        - TR: 300-500 ms
        - TE: 10-20 ms
    - Use: Sensitive to blood products and hemorrhage, GRE sequences are useful for detecting vascular lesions or bleeding within the shoulder joint.

HAYDAR ABDUL KADER

The choice of MRI sequences and parameters may vary depending on the clinical indication and the specific shoulder condition being evaluated. Consultation with a radiologist or healthcare provider is essential to determine the most appropriate MRI protocol for your specific shoulder issue.

Posttest: :الاختبار البعدي

- **Explain the specific uses of the shoulder MRI**

References: :المصادر

Handbook of MRI Technique Catherine Senior 5TH EDITION 2022
Step by step MRI Jaganmohan Reddy v parsed

Radiopedia