الجامعة التقنية الوسطى

كلية التقنيات الصحية والطبية/ بغداد

قسم: تقنيات الاشعة المادة: التصوير بالرنين المغناطيسي

المرحلة: الرابعة

العنوان: **Title: MRI of the hip joint.**

اسم المحاضر: **Name of the instructor:**

م. حيدر عبد القادر طاهر

lecturer. Haydar Abdul Kader Taher

الفئة المستهدفة: **Target population:**

طلبه المرحلة الرابعة في قسم تقنيات الاشعة

المقدمة: Introduction:

MRI of the hip is an important imaging technique that MRI technicians need to learn for several reasons:

1. **Detailed imaging of hip structures: MRI of the hip provides detailed images of the hip joint, including bones, cartilage, labrum, tendons, and muscles, from multiple angles**

This allows for a comprehensive evaluation of the hip and its surrounding tissues.

2. **Diagnosing and evaluating various hip conditions: MRI is the modality of choice for investigating painful hip conditions due to its multiplanar capability and high contrast resolution**

It can help diagnose or evaluate conditions such as hip osteoarthritis, labral tears, femoroacetabular impingement, avascular necrosis, and hip joint infections

3. **Differentiating between normal and abnormal findings: MRI can help differentiate between normal and abnormal hip structures, aiding in the diagnosis of various conditions**

For example, in hip osteoarthritis, MRI can show joint narrowing, subchondral sclerosis (increased white/bright location surrounding the joint), and osteophyte formation

4. **Guiding treatment decisions: The information obtained from a hip MRI can help healthcare professionals, including surgeons and physical therapists, decide on the appropriate treatment for the patient**
5. **No radiation exposure: MRI uses no radiation, making it a safe imaging option for patients**

HAYDAR ABDULKADER

Pretest: الاختبار القبلي:

Who the MRI examination would give us comprehensive evaluation of the hip and its surrounding tissues?

Scientific Content: المحتوى العلمي:

Common indications

•• Evaluation of unexplained unilateral or bilateral hip pain
•• Suspected occult fracture
•• Muscle tears
•• Labral tears, chondral damage or other joint soft tissue pathology
Note: Bilateral and unilateral examinations of the hips are described in this section. The causes of generalized hip pain include AVN, metastatic deposits and occult fractures, which may affect both hips. Specific unilateral joint pathologies such as suspected labral tears or chondral damage require high-resolution imaging of the hip in question. However, due to the prevalence of AVN in patients presenting with hip pain, it is advisable to include a bilateral sequence in unilateral hip protocols.

Equipment
Bilateral hip imaging
•• Body phased array/multi-coil array/general-purpose flexible coil/ body coil
•• Immobilization pads and straps
•• 20° wedge sponges
•• Earplugs/headphones
Single hip imaging
•• Small/large flexible coil/multi-coil array/pelvis phased array/small Helmholtz pair
•• Immobilization pads and straps
•• 20° wedge sponges
•• Earplugs/headphones

Patient positioning
The patient lies supine on the examination couch with their legs straight and both feet parallel to each other. This ensures that the angle of both femoral necks is the same, although they do not necessarily have to be internally rotated as in radiography of the hips. The legs are immobilized with the use of pads and straps wrapped around both feet. This enables the patient to maintain the position in a relaxed fashion.
The patient is positioned so that the longitudinal alignment light lies in the midline, and the horizontal alignment light passes through the level of the femoral heads. They are localized by palpating the femoral pulse,

HAYDAR ABDUL KADER

which is typically found 3 cm inferiorly and laterally to the midpoint of the line joining the anterior superior iliac spine (ASIS) and the pubic symphysis. If only one hip is imaged, the FOV will be offset from isocentre and image quality may be affected.



Patient Position-Pelvic array coil

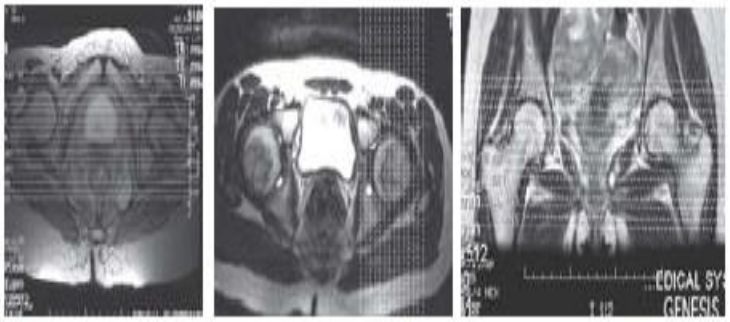

Axial localizer for coronal slices | Axial localizer for sagittal slices | Coronal localizer for axial slices

Common Hip MRI Sequences:

1. **T1-Weighted Imaging**:
   - Parameters:
     - Slice thickness: 3-4 mm
     - TR (Repetition Time): 400-800 ms
     - TE (Echo Time): 10-20 ms
   - Use: Provides detailed anatomical information of the hip joint, including bones, cartilage, and soft tissues. T1-weighted images are good for assessing the hip's anatomy.
2. **T2-Weighted Imaging**:
   - Parameters:
     - Slice thickness: 3-4 mm
     - TR: 2000-5000 ms
     - TE: 80-120 ms
   - Use: Highlights differences in tissue water content and is valuable for assessing soft tissues within and around the hip, including muscles, tendons, ligaments, and detecting inflammation.
3. **Proton Density (PD)-Weighted Imaging**:
   - Parameters:
     - Slice thickness: 3-4 mm
     - TR: 1500-3000 ms

    - TE: 20-40 ms
  - Use: Provides intermediate contrast between T1 and T2 and is useful for evaluating soft tissue structures in the hip, including the labrum, tendons, and ligaments.
4. **Short Tau Inversion Recovery (STIR)**:
  - Parameters:
    - Slice thickness: 3-4 mm
    - TR: 3000-5000 ms
    - TE: 40-60 ms
    - Inversion Time (TI): 150-200 ms
  - Use: Suppresses fat signal and enhances the visibility of fluid, which can be helpful in detecting edema, bone marrow abnormalities, and soft tissue lesions.

5.Vascular Assessment: In certain cases, MRI angiography may be performed to assess the blood vessels in the hip region, particularly if vascular abnormalities are suspected.

The choice of MRI sequences and parameters may vary depending on the clinical indication and the specific hip condition being evaluated. Consultation with a radiologist or healthcare provider is essential to determine the most appropriate MRI protocol for your specific hip issue.

HAYDAR ABDUL KADER

References: المصادر:

Handbook of MRI Technique Catherine Senior 5TH EDITION 2022
Step by step MRI Jaganmohan Reddy v parsed

Radiopedia