الجامعة التقنية الوسطى

كلية التقنيات الصحية والطبية/ بغداد

قسم: تقنيات الاشعة المادة: التصوير بالرنين المغناطيسي
المرحلة: الرابعة

العنوان: **Title: MRA and MRV.**

اسم المحاضر: **Name of the instructor:**

م. حيدر عبد القادر طاهر

lecturer. Haydar Abdul Kader Taher

الفئة المستهدفة: **Target population:**

طلبه المرحلة الرابعة في قسم تقنيات الاشعة

HAYDAR KADER

Introduction: المقدمة:

MRA and MRV stand for magnetic resonance angiography and magnetic resonance venography, respectively. Both are non-invasive imaging techniques that use a strong magnetic field and radio waves to produce detailed images of blood vessels.

MRA is used to visualize arteries, while MRV is used to visualize veins. Arteries carry oxygen-rich blood from the heart to the rest of the body, while veins carry oxygen-depleted blood back to the heart.

Pretest: الاختبار القبلي:

What are the advantages of the MRA in the brain.

YAYDAR ABDUL KADER

Scientific Content: المحتوى العلمي:

Common indications

- Evaluation of the carotid arteries especially at the bifurcation
- Intracranial vascular assessment of aneurysms and infarcts
- Arteriovenous malformation (AVM)
- Intracranial vessel occlusion including sagittal sinus thrombosis
- Circle of Willis (stroke or TIA)

Equipment

- Quadrature or phased array head coil (brain imaging)
- Anterior neck coil (neck imaging)
- Immobilization foam pads and straps
- Earplugs/headphones

Patient positioning

Brain imaging

The patient lies supine on the examination couch with their head within the head coil. The head is adjusted so that the inter-pupillary line is parallel to the couch and the head is straight. The longitudinal alignment light lies in the midline, and the horizontal alignment light passes through the nasion. Straps and foam pads are used to immobilize the patient as much as possible.





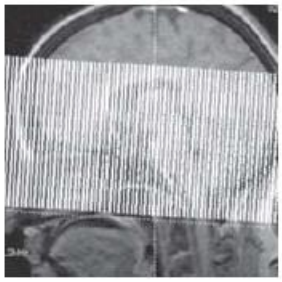

MRA 3D TOF single slab



MRV 2D TOF

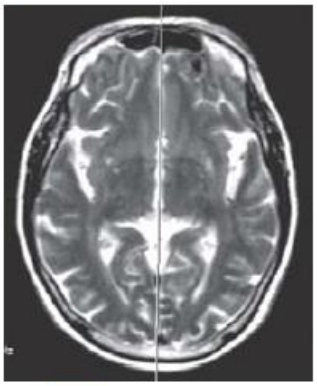

MRV 2D -PC (Sagittal)

Common Brain MRA Sequences:

1. **Time-of-Flight (TOF) MRA:**
    - **Parameters:**
        - **Slice thickness: 1-2 mm**

- **TR (Repetition Time): Short (typically <30 ms)**
- **TE (Echo Time): Short (typically <5 ms)**

- **Use: TOF MRA is commonly used for non-contrast imaging of the brain's arterial vasculature. It relies on the inflow of unsaturated blood into the imaging slice to create high signal intensity in arteries.**

2. **<u>Phase-Contrast (PC) MRA</u>:**
   - **Parameters:**
     - **Slice thickness: 1-2 mm**
     - **TR: Varies**
     - **TE: Varies**
   - **Use: PC MRA measures the velocity of blood flow and can be used to assess blood flow direction and velocity in both arteries and veins. It is often used for flow quantification and to assess conditions like arteriovenous malformations (AVMs).**
3. **<u>Contrast-Enhanced MRA (CE-MRA):</u>**
   - **Parameters:**
     - **Slice thickness: 1-2 mm**
     - **TR: Short to moderate (varies)**
     - **TE: Short (typically <5 ms)**
     - **Contrast agent: Gadolinium-based contrast agent**
   - **Use: CE-MRA uses contrast agents to enhance the visualization of blood vessels. It is useful for detailed imaging of the cerebral arteries, particularly smaller vessels and the venous system.**
4. **<u>3D MRA:</u>**
   - **Parameters:**
     - **Slice thickness: 0.6-1 mm (high spatial resolution)**
     - **TR: Short to moderate (varies)**

HAYDAR ABDULKADER

- **TE: Short (typically <5 ms)**

- **Use: 3D MRA acquires a volume of data, providing high-resolution images of the brain's vascular anatomy. It is especially useful for assessing complex vascular structures and anomalies.**

5. **Balanced Steady-State Free Precession (bSSFP) MRA:**

   - **Parameters:**
     - **Slice thickness: 1-2 mm**
     - **TR: Short (typically <5 ms)**
     - **TE: Short (typically <2 ms)**
   - **Use: bSSFP MRA offers high signal-to-noise ratio (SNR) and excellent blood-tissue contrast. It is often used for visualizing the circle of Willis and evaluating vascular pathology.**

HAYDAR ABDUL KADER

Common Brain MRV Sequences:

1. **Time-of-Flight (TOF) MRV:**

   - **Parameters:**
     - **Slice thickness: 1-2 mm**
     - **TR (Repetition Time): Short (typically <30 ms)**
     - **TE (Echo Time): Short (typically <5 ms)**
   - **Use: TOF MRV is often used for non-contrast imaging of the brain's venous vasculature. Similar to TOF MRA, it relies on the inflow of unsaturated blood into the imaging slice to create high signal intensity in veins.**

2. **Contrast-Enhanced MRV (CE-MRV):**

   - **Parameters:**
     - **Slice thickness: 1-2 mm**
     - **TR: Short to moderate (varies)**

- **TE: Short (typically <5 ms)**
- **Contrast agent: Gadolinium-based contrast agent**

- **Use: CE-MRV uses contrast agents to enhance the visualization of veins and dural sinuses in the brain. It provides detailed imaging of the venous system, including the superior sagittal sinus and transverse sinuses.**

3. **<u>3D MRV:</u>**
    - **Parameters:**
        - **Slice thickness: 0.6-1 mm (high spatial resolution)**
        - **TR: Short to moderate (varies)**
        - **TE: Short (typically <5 ms)**
    - **Use: 3D MRV acquires a volume of data, allowing high-resolution imaging of the brain's venous anatomy. It is useful for assessing venous structures and pathology, including dural venous sinuses and cerebral veins.**
4. **<u>Phase-Contrast (PC) MRV:</u>**
    - **Parameters:**
        - **Slice thickness: 1-2 mm**
        - **TR: Varies**
        - **TE: Varies**
    - **Use: PC MRV measures venous blood flow velocity and can be used to assess venous flow direction and detect abnormalities in venous flow patterns.**

HAYDAR ABDULKADER

Posttest: الاختبار البعدي:

Compare between the MRA and MRV in the brain?

References: المصادر: