RADIOLOGICAL ANATOMY

Normal anatomy of the skull

(cranial) bones

By

Muneer jawad MS.c RT

INTRODUCTION

- ***The skull is a bony structure that supports the face and forms a protective cavity for the brain. It is comprised of many bones, and joined by sutures (fibrous joints).***
- ***<u>The skull consists of :</u>***

1. **Cranium.**
2. **Facial bones.**
3. **Mandible.**

- **The Cranium: is the top part of the skull , it covers and protectthe brain , meninges and cerebral vasculature, it forms the main component of the skull roof .**
  - **Anatomically the cranium can be sub divided into roof and base:**

A. <u>The roof:</u> composed of frontal , occipital and two parietal bones (Calvarium).

B. <u>B.The base:</u> composed of 6 bones (frontal , sphenoid , ethmoid , occipital , parietal and temporal

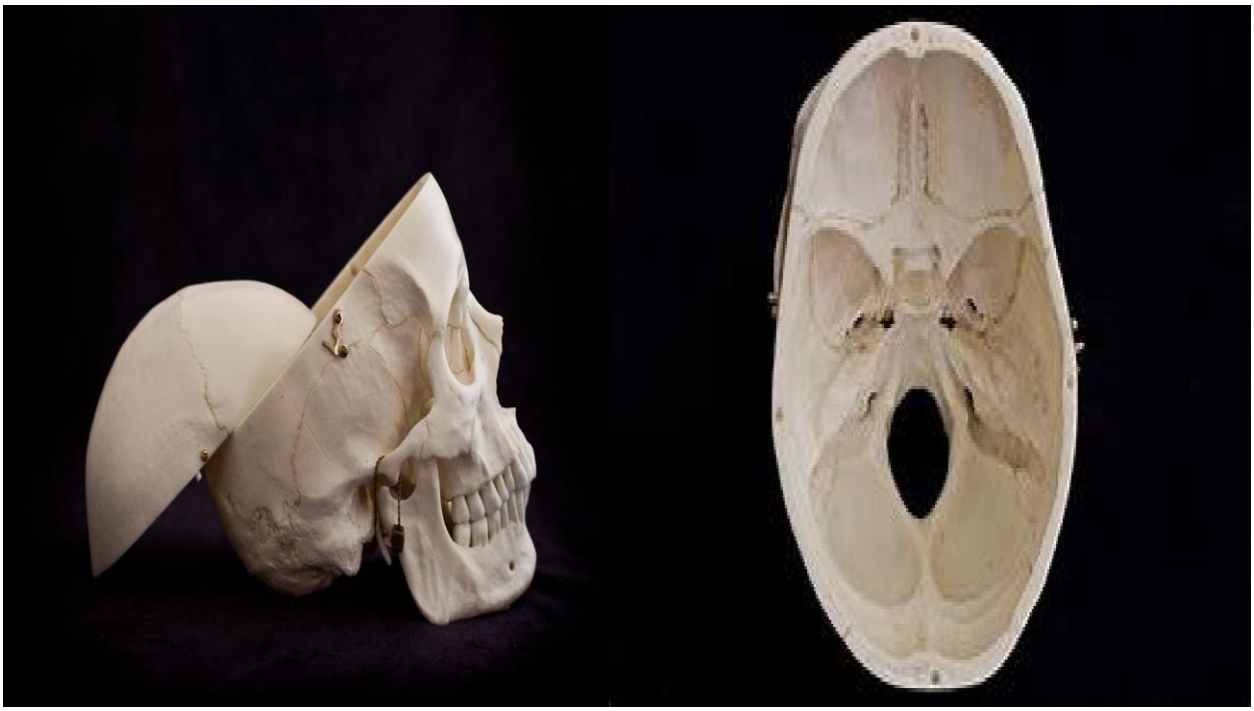

CRANIAL BONES

- ***<u>There are eight cranial bones, each with a unique shape:</u>***

1. **<u>Frontal bone.</u> This is the flat bone that makes up your forehead. It also forms the upper portion of your eye sockets.**
2. **<u>Parietal bones</u>. This a pair of flat bones located on either side of your head, behind the frontal bone.**

3.<u>Temporal bones</u>. This is a pair of irregular bones located under each of the parietal bones

4. **<u>Occipi</u>tal bone. This is a flat bone located in the very back of your skull. It has an opening that allows your spinal cord to connect to your brain called the foramen magnum through which the medulla oblongata connects to the spinal cord.**
5. **<u>Sphenoid bone</u>. This is an irregular bone that sits below the frontal bone. It spans the width of your skull and forms a large part of the base of your skull. *<u>(lesser wing anteriorly , greater wing posteriorly , body in the mid line within which lies the sella trucica)</u>* It articulate with all the other bones holding them together**

6. **<u>Ethmoid bone</u>. This is an irregular bone located in front of the sphenoid bone , medial to the orbits , It makes up part of your nasal cavity.**

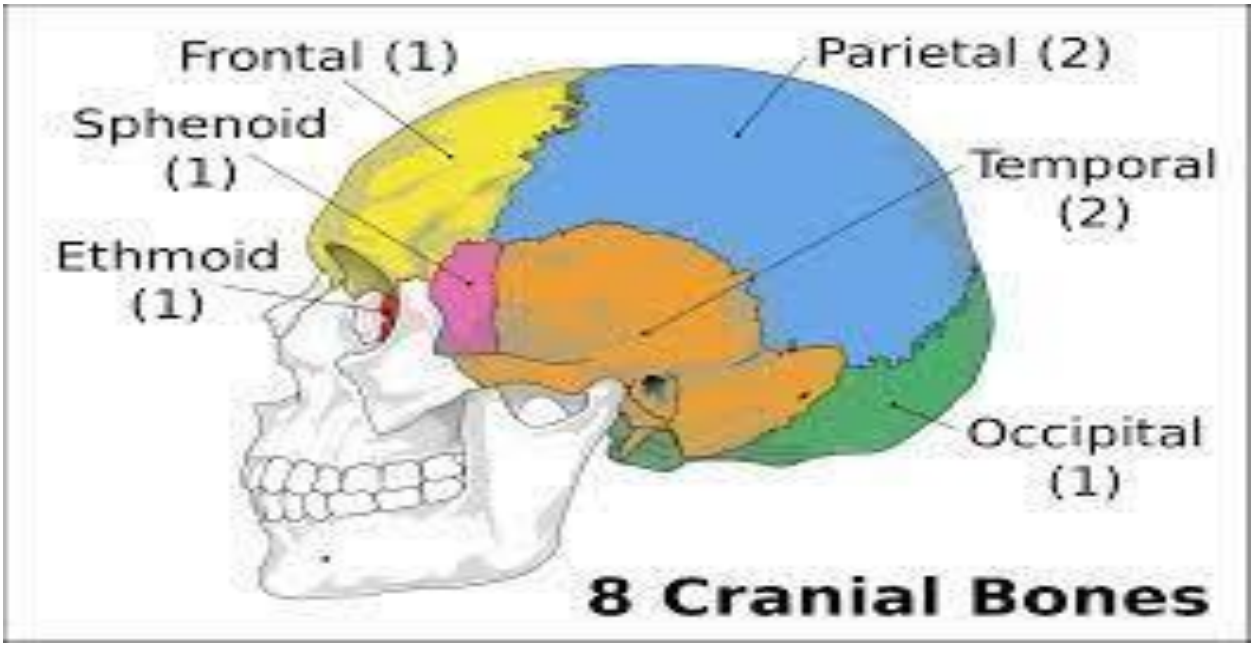

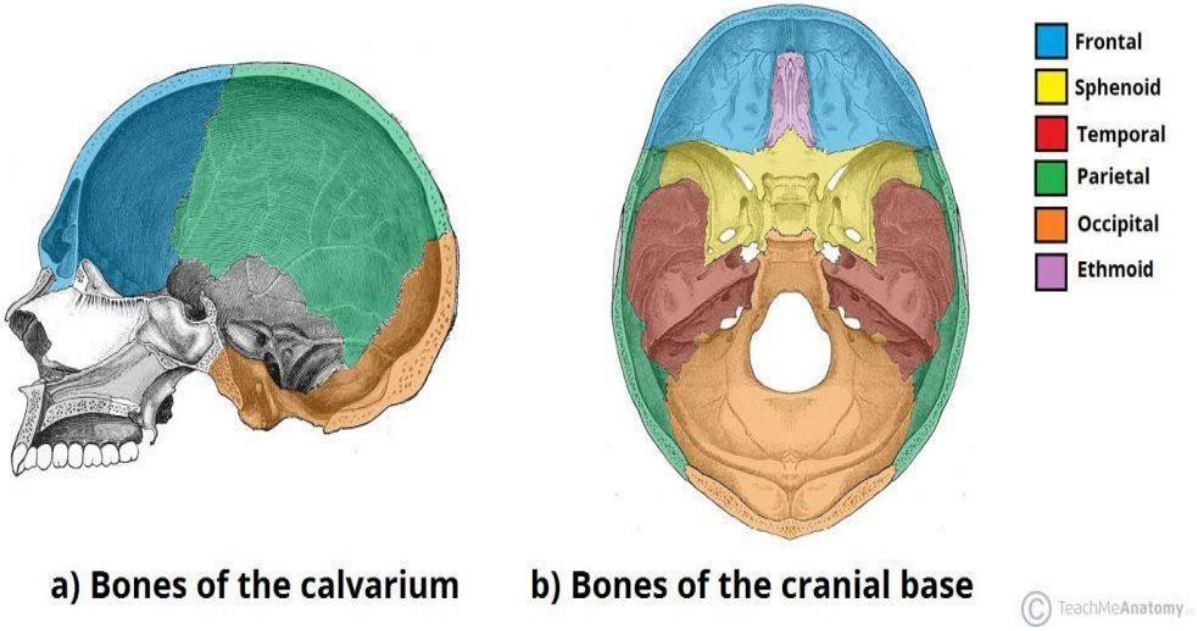

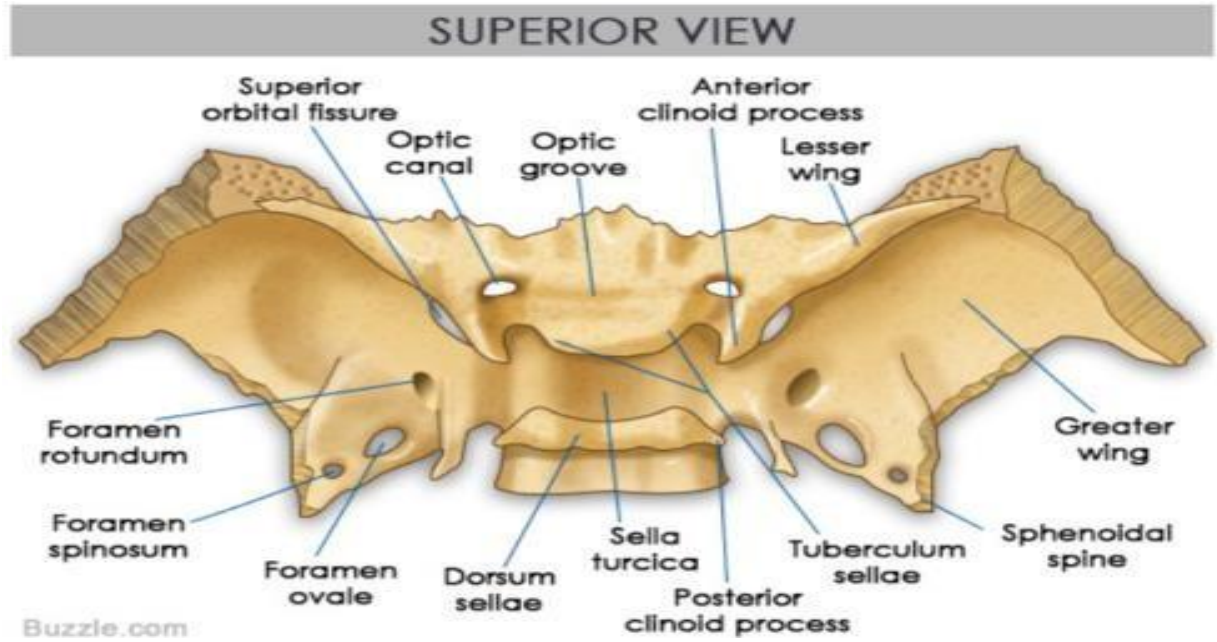

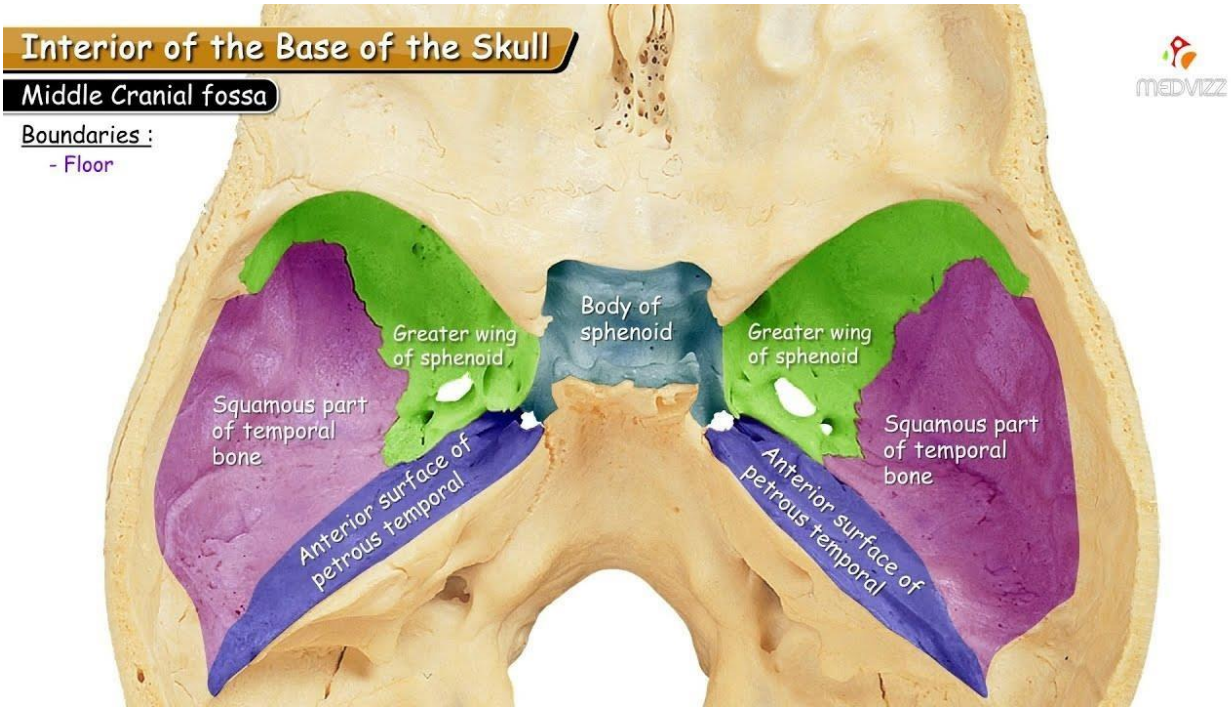

SELLA TURSICA

- **Mid line structure in the sphenoid bone which contains the pituitary gland.**
- **Size: length less than 15 mm , depth less than 12 mm**
- ***Contents : (pituitary gland , pituitary vessels , CSF , intra cavernous sinus***



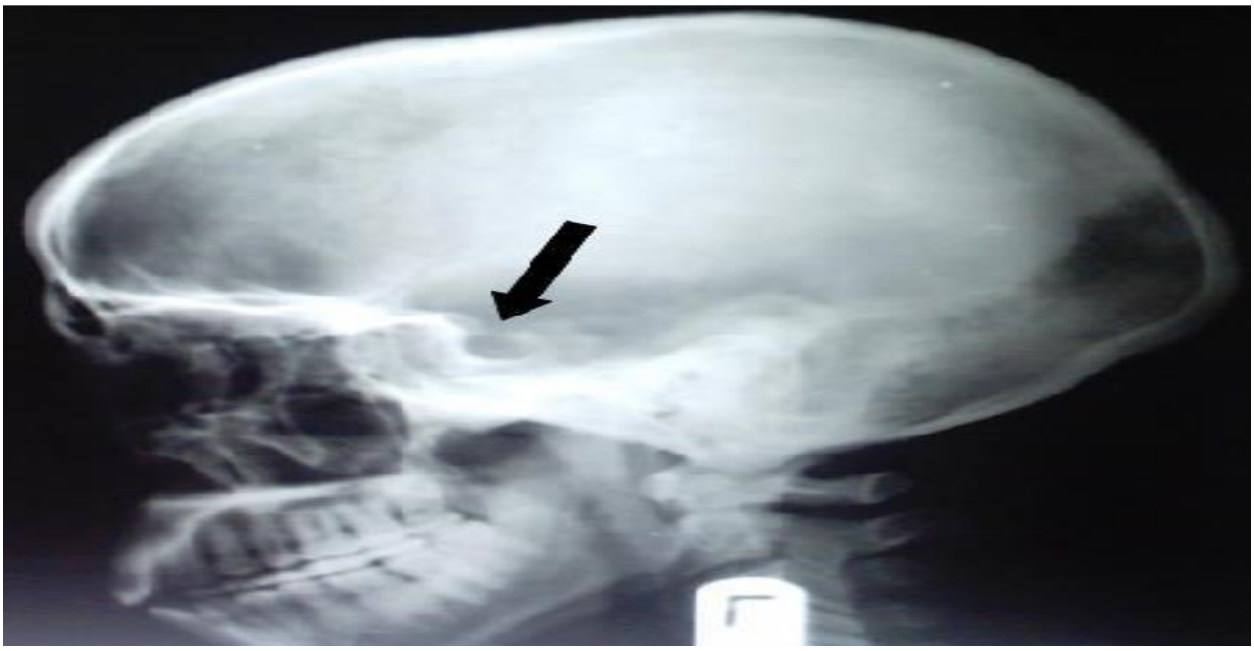

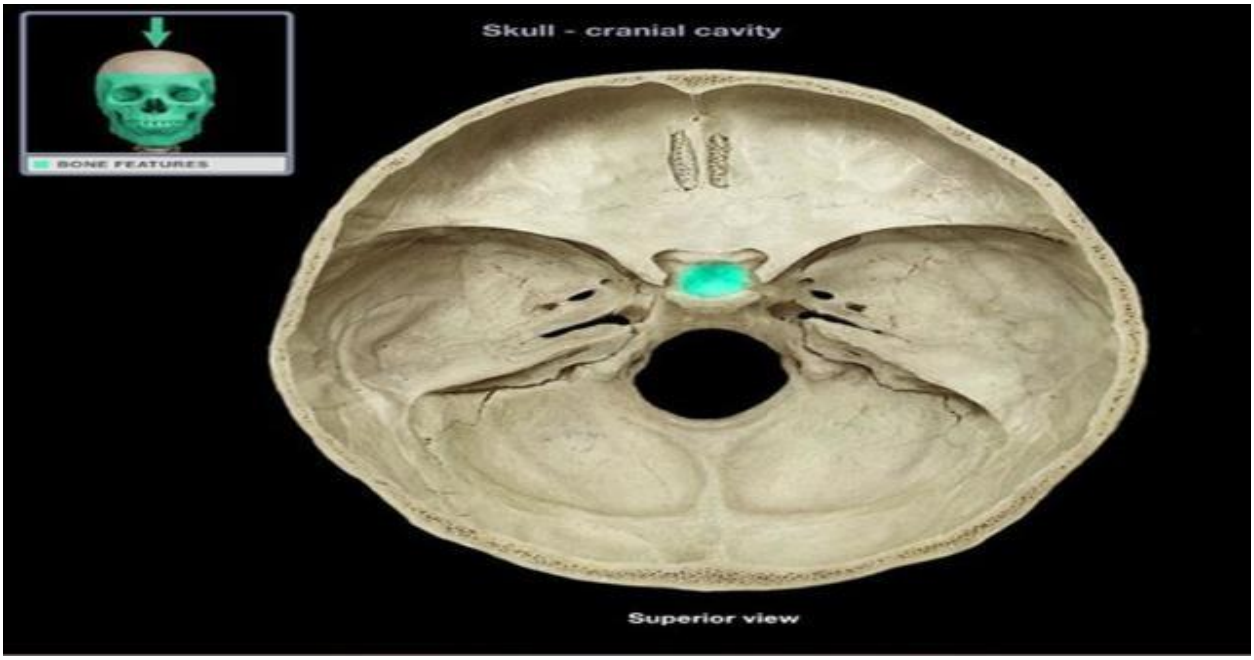

Cranial cavities

The brain is supported by the skull base and enclosed within the skull vault . within the cranial cavity is divided into the anterior , middle and posterior fossae.

- ***The anterior cranial fossa:*** contains the cerebral hemi spheres **(Frontal lobe),Consists** of three bones: the frontal bone, ethmoid bone and sphenoid bone.
- ***The middle cranial fossa:*** contains the cerebral hemisphere **(Temporal lobe),**consists of three bones – the sphenoid bone and the two temporal bones.
- ***The posterior cranial fossa:*** contains the Brain stem **(mid brain , pons , medulla and cerebellum)** , consists of three bones: the occipital bone and the two temporal bones.

Cranial Fossae

- Anterior
- Middle
- Posterior



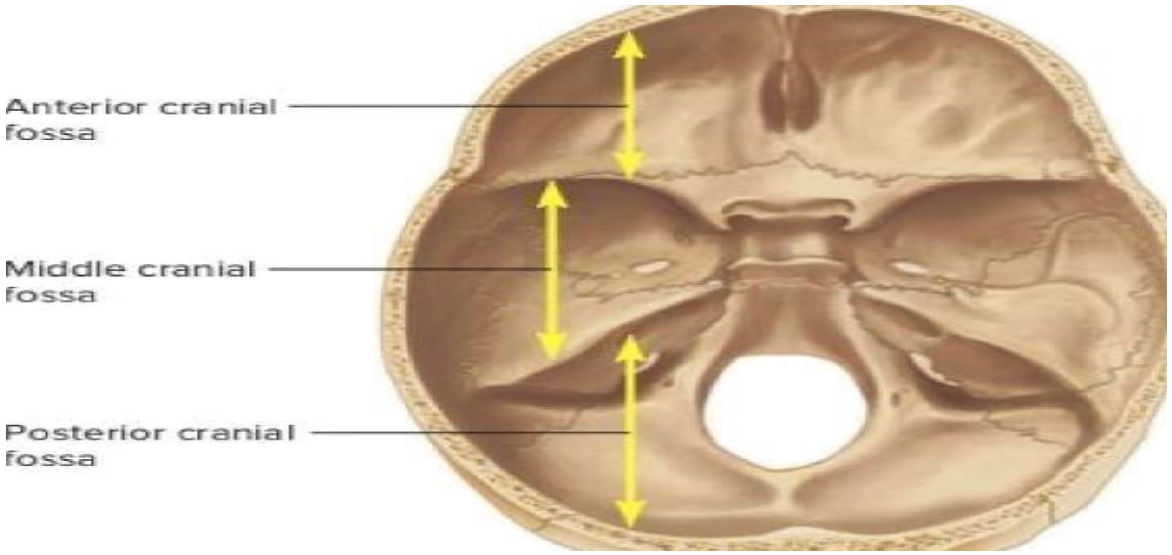

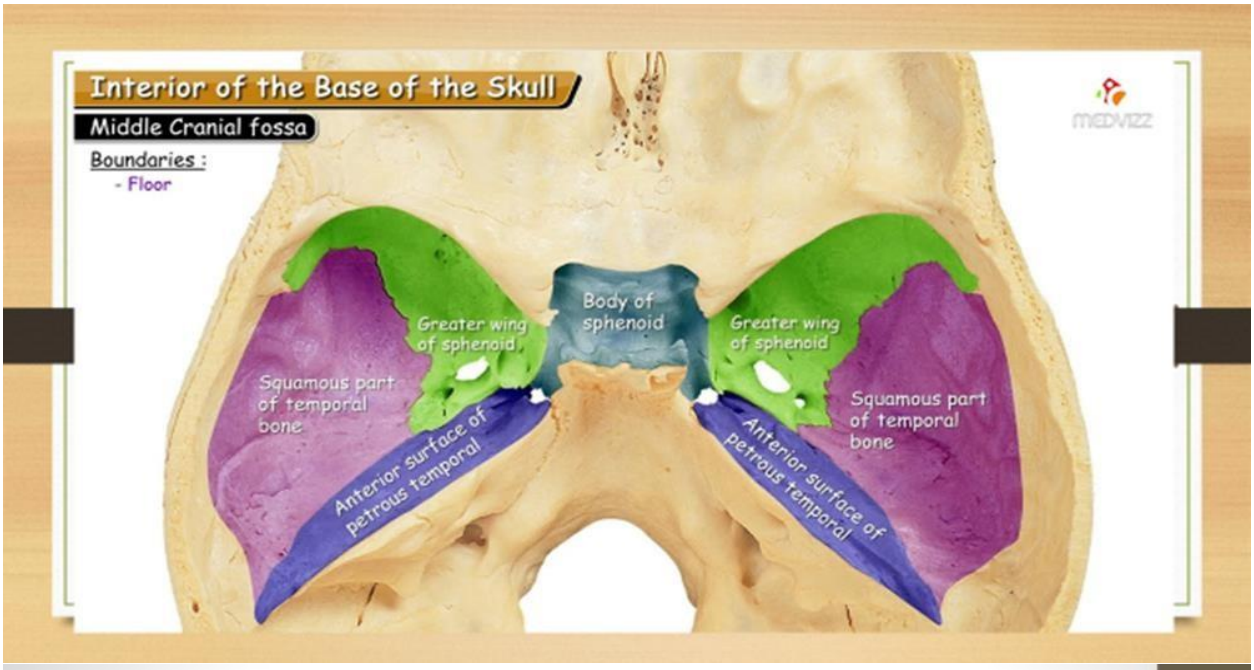
Interior of the Base of the Skull
Middle Cranial fossa
Boundaries :
- Floor
Greater wing of sphenoid
Body of sphenoid
Greater wing of sphenoid
Squamous part of temporal bone
Anterior surface of petrous temporal
Anterior surface of petrous temporal
Squamous part of temporal bone

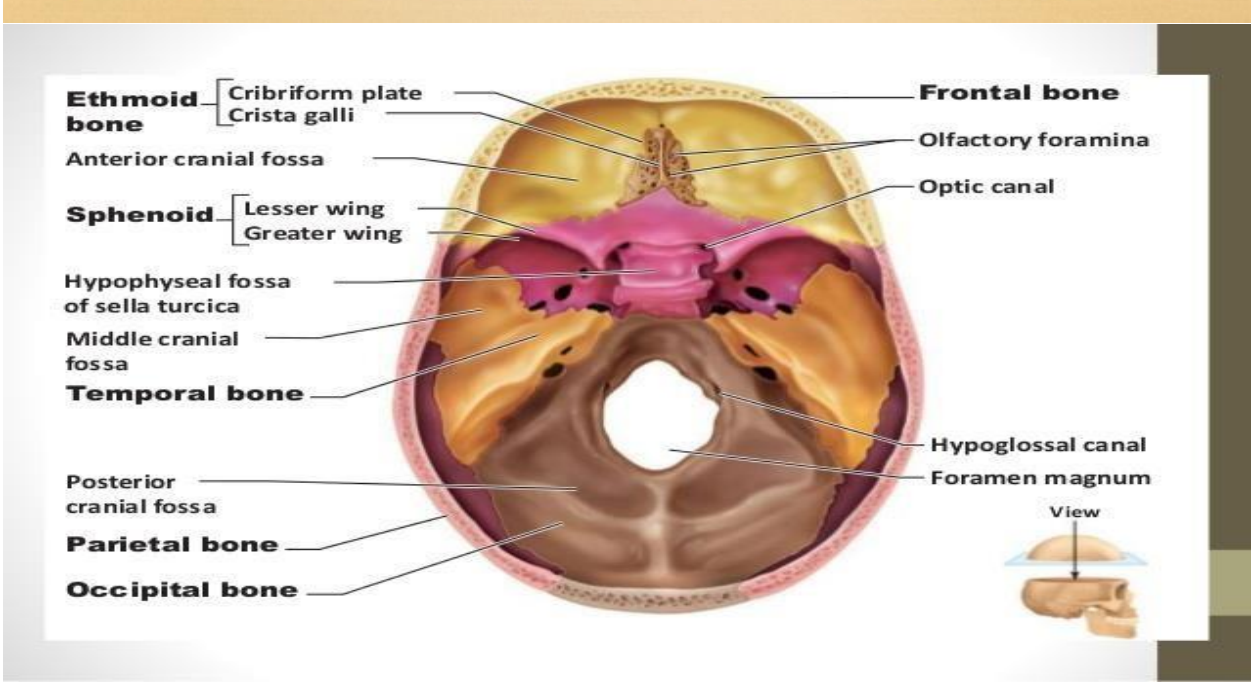
Ethmoid bone
Cribriform plate
Crista galli
Anterior cranial fossa
Sphenoid
Lesser wing
Greater wing
Hypophyseal fossa of sella turcica
Middle cranial fossa
Temporal bone
Posterior cranial fossa
Parietal bone
Occipital bone
Frontal bone
Olfactory foramina
Optic canal
Hypoglossal canal
Foramen magnum
View

SUTURES

- Sutures are type of fibrous joints that are specific to the skull , they are immovable and fuses completely by the age of 20.
- The importance of the sutures lay in the context of trauma as the represent the point of weakness in the skull
- The main sutures of the skull are:

1. ***Coronal suture*** :fuses the frontal bone with the two parietal bone.
2. ***Sagittal suture:*** fuses both parietal bones to each other .
3. ***Lambdoid suture:*** fuses the occipital bone to the two parietal bones.
4. ***Sequmous suture :*** unite the parietal and temporal bones on the lateral aspects of the skull

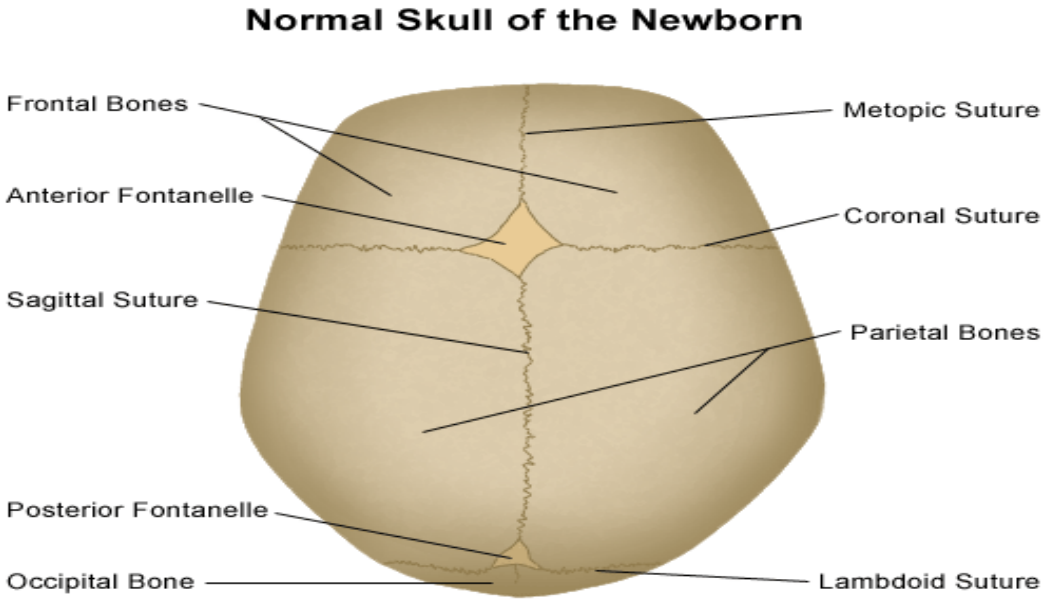

Note: The junction of coronal and sagittal sutures is known as the bregma

Note: The junction of lambdoid and sagittal sutures



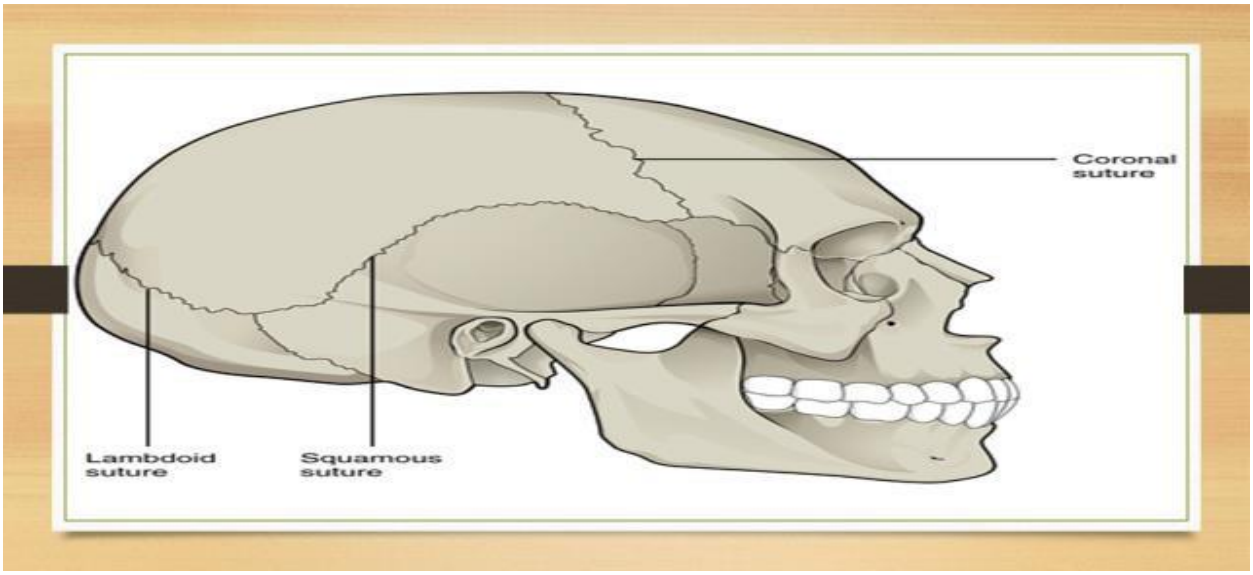

- The greater wing of sphenoid and the squamous part of the temporal bone form the side of the skull vault below the frontal and parietal bones , The sutures formed here are:

- 1.the spheno squamosal suture between the sphenoid and temporal bones;
- 2. the spheno frontal and spheno parietal sutures between greater wing of sphenoid and frontal and parietal bones
- ***3.The sphenofrontal, sphenoparietal and squamosal sutures form a continuous curved line.***