Radiological features of the skull base and vault

By

Muneer jawad lec4 -5 th

❖ **Plain films :** Several projections are required for a full assessment of the skull vault The standard projections are **lateral**, **OF20** (occipital frontal view with 20 ° caudal angulation), and **Towne ' s** projections (fronto-occipital projection with 45 ° caudal angulation) **The SMV** view is used to assess the skull base and demonstrates most of the foramina Views for facial bones and sinuses also include **OM (occipitomental)** and **OM30 (OM with 30 ° cranial angulation)** views.

❖ **Skull Cross-Sectional Imaging**

CT provides excellent visualization of the skull base and foramina. MRI with narrow section thickness slices is excellent for demonstration of the soft-tissue contents of the foramina, in particular the cranial nerves.

Radiological features of the orbit

❖ **Orbital Plain Films**

The orbits may be assessed on OF20 and OM projections.

❖ **orbital Computed Tomography**

The bony orbit and its soft-tissue contents are demonstrated very well by CT. MRI is more valuable for demonstration of the soft-tissue contents ofthe orbit than the bone.

Radiological features of the paranasal

❖ **Plain films of the nasal cavity and paranasal** sinuses The frontal sinuses are not visible until the age of 2 years and achieve adult proportions by the age of 14. Asymmetry is common, and one or both may fail to develop. Development of the ethmoids occurs at a rate similar to that of the frontal sinuses. Development of the sphenoid air sinus commences at 3 years of age and may extend into the greater wings of sphenoid or clinoid processes. The maxillary sinuses are the first to appear and are visible radiologically from a few weeks after birth and continue to develop throughout childhood. The tooth-bearing alveolar process does not begin to develop until the age of 6 years. Full development of the maxillary sinus is not achieved until there has been complete eruption of the permanent dentition in early adulthood.

❖ **Computed tomography and MRI of the nasal cavity and paranasal sinuses**

CT in either axial or coronal planes provides excellent visualization of the paranasal sinuses. Particular attention is paid to the region of the ostiomeatal complex, where the maxillary,

frontal and anterior ethmoidal sinuses drain, and the sphenoethmoid recess and superior meatus, on to which the sphenoid and posterior ethmoid sinuses drain. The sinuses should contain nothing but air MRI is good at demonstrating the sinuses, as the bony septa, which have no signal themselves, are lined by high-signal mucosa.

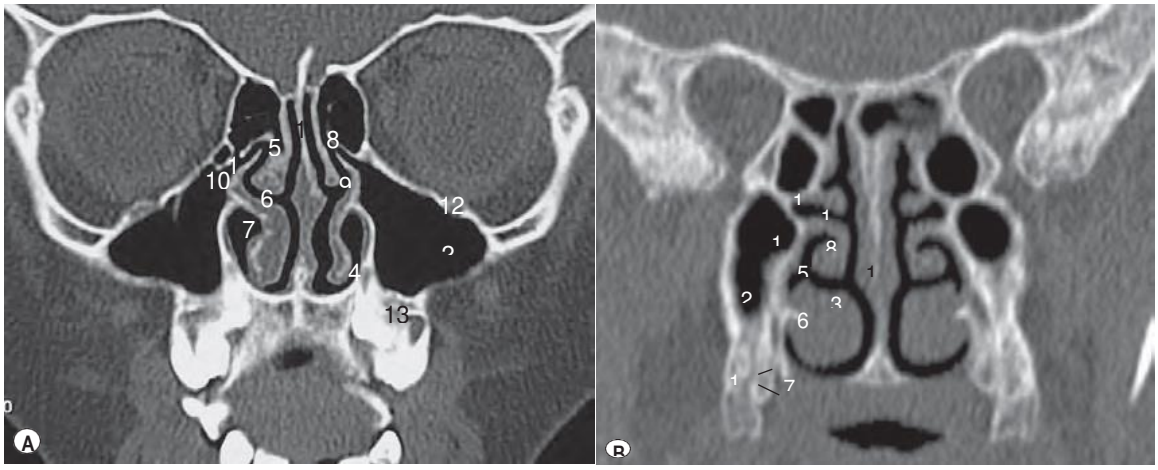

• Coronal CT scan of the sinuses: (A) coronal view at level of ostiomeatal complex and (B) posterior at level of sphenoethmoidal recess

1. Nasal septum
2. Maxillary sinus
3. Middle nasal turbinate
4. Inferior nasal turbinate
5. Superior meatus
6. Middle meatus
7. Inferior meatus
8. Ethmoid infundibulum
9. Uncinate process
   Maxillary ostium
10. Maxillary infundibulum
11. Infraorbital nerve
12. Alveolar process of maxilla
13. Ethmoid sinus
14. Sphenoid sinus
15. Sphenoethmoidal recess
16. Superior turbinate
17. Greater palatine canal

Radiological features of the mandible

The mandible: The mandible is composed of two halves united at the symphysis menti. Each half comprises a horizontal body and a vertical ramus joined at the angle of the mandible. The ramus has two superior projections, **the coronoid process anteriorly and the condylar process posteriorly** (or head of mandible), separated by the mandibular (or condylar) notch. **The coronoid process** gives attachment to the temporalis muscle, and the **condylar process** articulates with the base of the skull at the temporomandibular (TM) joint. The body of the mandible bears the alveolar border with its 16 tooth sockets The muscles of the floor of the mouth are attached to the inner surface of the mandible and the muscles of mastication are attached to its outer surface.

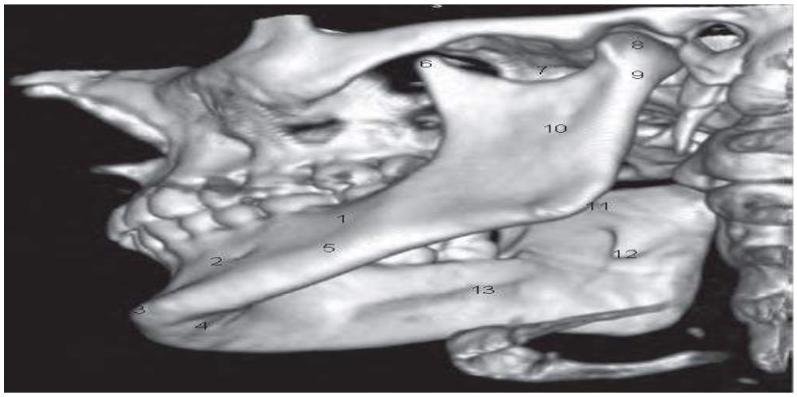

3D CT of mandible

1. Oblique line
2. Mental foramen
3. Mental protuberance
4. Mental tubercle
5. Body of mandible
6. Coronoid process
7. Mandibular notch
8. Condylar process
9. Neck
10. Ramus
11. Angle

12. Mandibular foramen Mylohyoid lin

The temporomandibular (TM) joint :This is a synovial joint between the condyle of the mandible and the temporal bone. The temporal articular surface consists of a fossa posteriorly, the temporomandibular fossa, and a prominence anteriorly, the articular tubercle. The head of the mandible sits in the fossa at rest and glides anteriorly on to the articular tubercle when fully open.

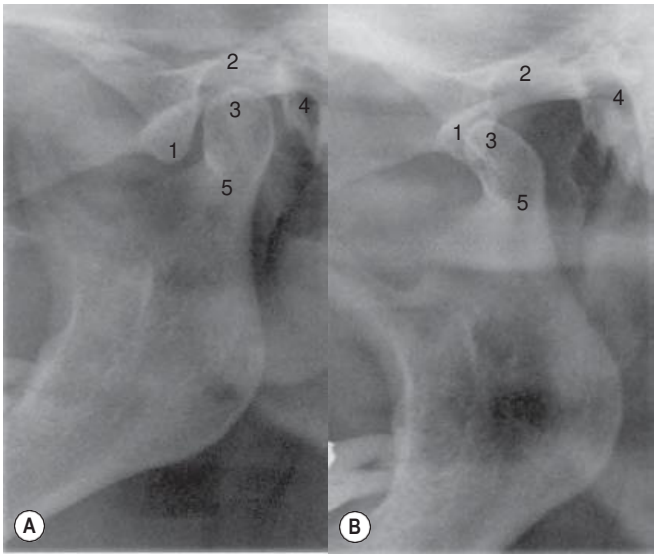

Radiographs of temporomandibular joints, (A) closed mouth and (B) open mouth views

1. Articular tubercle
2. Temporomandibular fossa
3. Head
4. External auditory meatus
5. Neck

The teeth – nomenclature and anatomy: There are 20 deciduous or milk teeth; in the adult these are replaced by 32 permanent teeth. The complement of teeth in each quadrant is as follows: • In the child: two incisors, one canine, two molars • In the adult: two incisors, one canine, two premolars, three molars. The teeth are referred to by their position in each of the four quadrants. The quadrant is designated by two arms of a cross, and the tooth by its position relative to the midline. The permanent teeth are referred to by number and the milk teeth by capital letter. Each tooth has three parts: 1) Crown which is the exposed intraoral part of the tooth, and this is covered by enamel. Enamel is the hardest and most radio-opaque substance in the body. 2)

The neck of the tooth is covered by the firm fibrous tissue of the gum, and this is covered by the mucous membrane of the mouth. 3) The root embedded in a separate socket. Both neck and root of the tooth is composed mostly of dentine, which is of a radiographic density similar to

compact bone. A radiolucent pulp cavity occupies the middle of the tooth and is continuous with the root canal, which transmits the nerves and vessels from the supporting bone. The root and neck of the tooth are surrounded by the periodontal membrane forms a radio-lucent line around them. A dense white line of bone surrounds this and is known as the lamina dura. This surrounds the root of each tooth and is continuous with the lamina dura of the adjacent teeth around the margin of the alveolar crest.

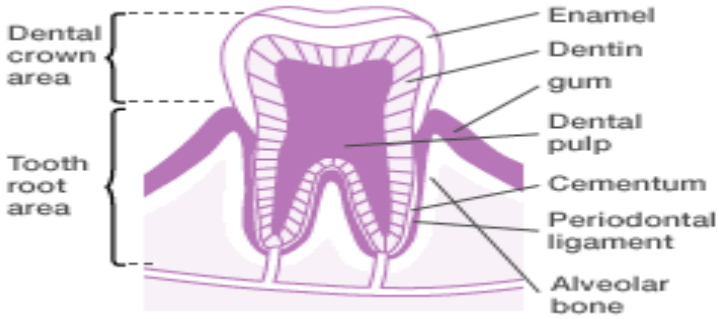

Plain films of the mandible and teeth: The mandible may be seen on the OF, OF20, OM, OM30 and lateral projections. Special oblique views may be required to show the rami if a fracture is suspected. There are also special views for the TM joints, and a full radiographic study of these includes images of both joints with the mouth open and closed. The teeth can be radiographed on small films, occlusal films, placed close up against them inside the mouth, which provide excellent detail.

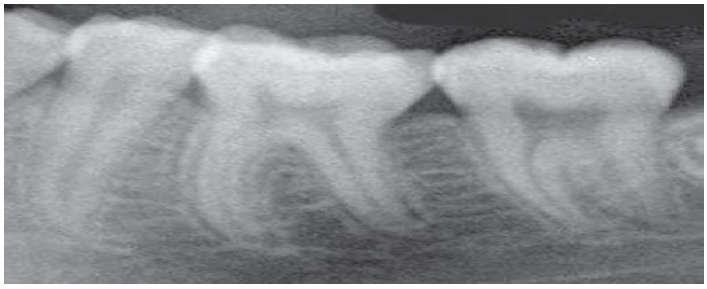

Cross-sectional imaging of the mandible and teeth High-resolution CT is used in the assessment of fractures of the mandible. MRI is excellent for the demonstration of the internal TM joint anatomy.

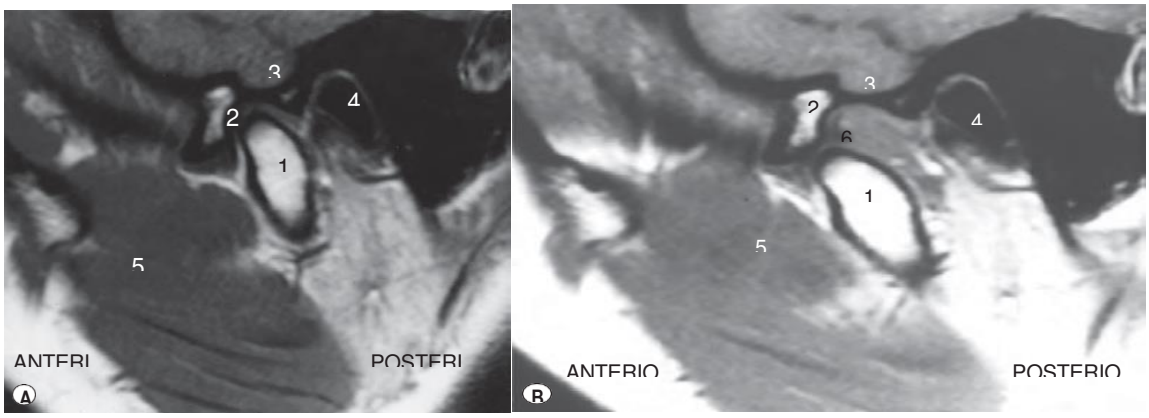

MRI of the TMJ; (A) closed mouth view; (B) open mouth view

1. Head of mandible
2. Articular tubercle
3. Temporal lobe
4. External auditory meatus
5. External auditory meatus
6. Lateral pterygoid muscle
7. Fibrocartilaginous disc

Dental pantomography The dental pantomogram gives a panoramic image of both dental arches, as well as the mandible, TM joints and lower maxilla. This study is obtained using special equipment that moves around the patient ' s face as the radiograph is being taken, mapping out the lower face and jaw in a straight line.

Dental pantomogram The third molars have been extracted

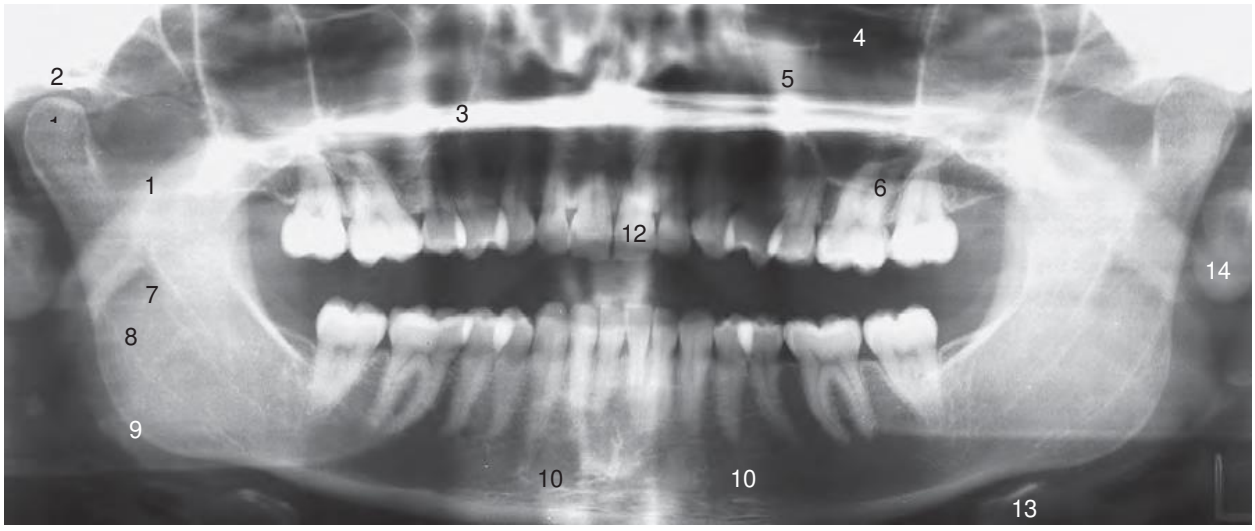

. Condylar process of mandible
. Temporomandibular fossa

4. Hard palate
4. Maxillary sinus
5. Medial wall of maxillary sinus
6. Floor of maxillary sinus
7. Condylar canal Ramus of mandible
8. Angle of mandible
9. Body of mandible
10. Mandibular notch
11. Upper left incisor
12. Hyoid bone (projected laterally)

Arthrography :Arthrography of the TM joint may also be performed where radio-opaque contrast is injected directly into the synovial spaces under radiographic control.

The skull base

The inner aspect of the skull base is made up of the following bones from anterior to posterior:
the orbital plates of the frontal bone, with the cribriform plate of the ethmoid bone and crista galli in the midline;
the sphenoid bone with its lesser wings anteriorly, the greater wings posteriorly, and body with the elevated sella turcica in the midline;
part of the squamous temporal bone and the petrous temporal bone; and
the occipital bone

Individual bones of the skull base

The **orbital plates of the frontal bones** are thin and irregular and separate the anterior cranial fossa from the orbital cavity The **cribriform plate** of the ethmoid bone is a thin, depressed bone separating the anterior cranial fossa from the nasal cavity It has a superior perpendicular projection, the crista galli, which is continuous below with the nasal septum on the frontal skull radiograph

The sphenoid bone consists of a body and greater and lesser wings, which curve laterally from the body and join at the sharply posteriorly angulated sphenoid ridge The body houses the sphenoid sinuses and is grooved laterally by the carotid sulcus, in which the cavernous sinus and carotid artery run The sphenoid body has a deep fossa superiorly (see Figs 1 7 and 2 14) known as the **sella turcica** or **pituitary fossa**, which houses the pituitary gland On the anterior part of the sella is a prominence known as the **tuberculum sellae**; anterior to this is a groove called the **sulcus chiasmaticus**, which leads to the optic canal on each side The optic chiasm lies over this sulcus Two bony projections on either side of the front of the sella are called the

anterior clinoid processes The posterior part of the sella is called the **dorsum sellae,** and this is continuous posteriorly with the **clivus** Two posterior projections of the dorsum sellae form the **posterior clinoid processes** The floor of the sella is formed by a thin bone known as the **lamina dura**, which may be eroded by raised intracranial pressure or tumours of the pituitary

The **temporal bone** consists of four parts:

- a flat **squamous** part, which forms part of the vault and part of the skull base;
- a pyramidal **petrous** part, which houses the middle and inner ears and forms part of the skull base;
- an aerated **mastoid** part; and
- an inferior projection known as the **styloid process**

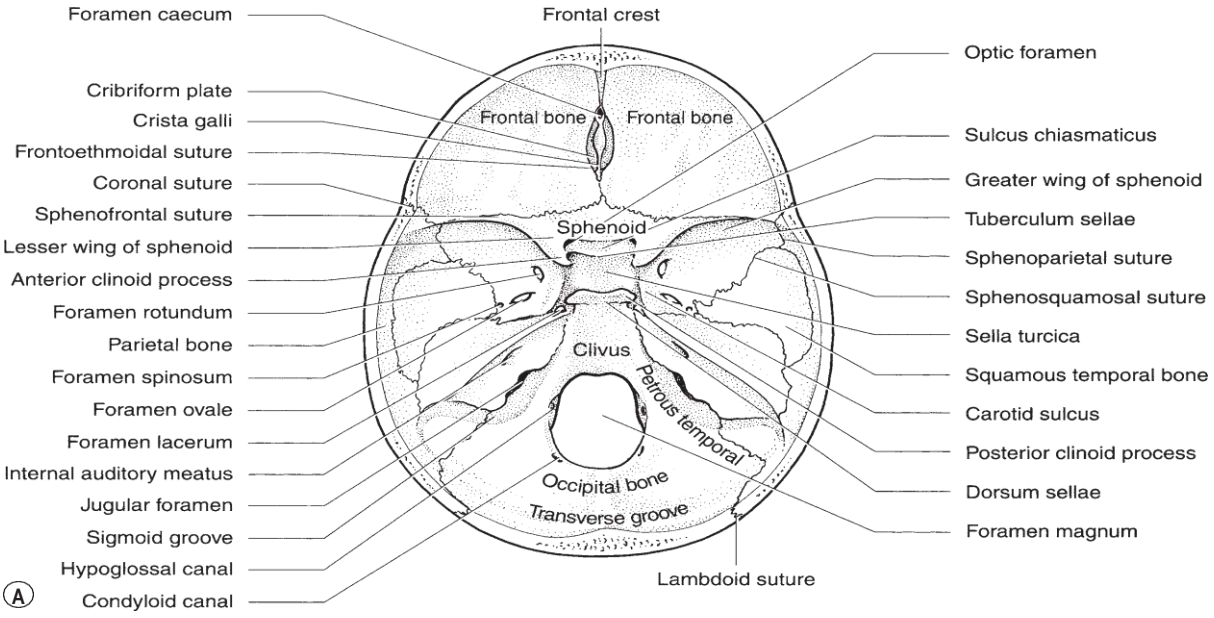



Skull base: internal aspect

(B) 3D CT of skull base, internal aspec

1. Crista galli
2. Anterior clinoid process
3. Optic canal
4. Posterior clinoid process
5. Cribriform plate
6. Posterior ethmoidal foramen

7.Foramen ovale

8.Foramen spinosum

9.Foramen lacerum

10.Jugular foramen

11.Foramen magnum

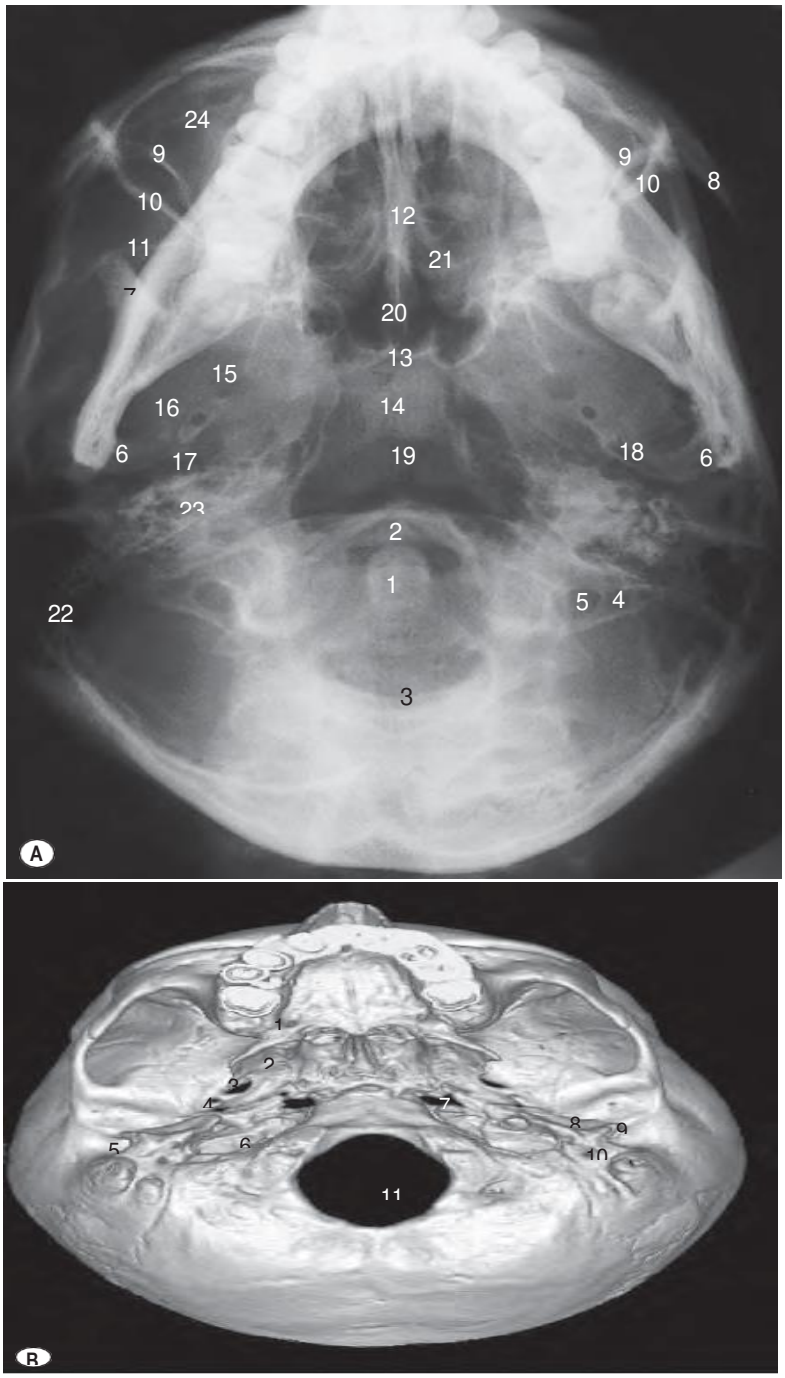

(A) SMV view of skull; (B) Skull base 3D CT of skull base, inferior view