Radius& ulna& elbow joint lateral view

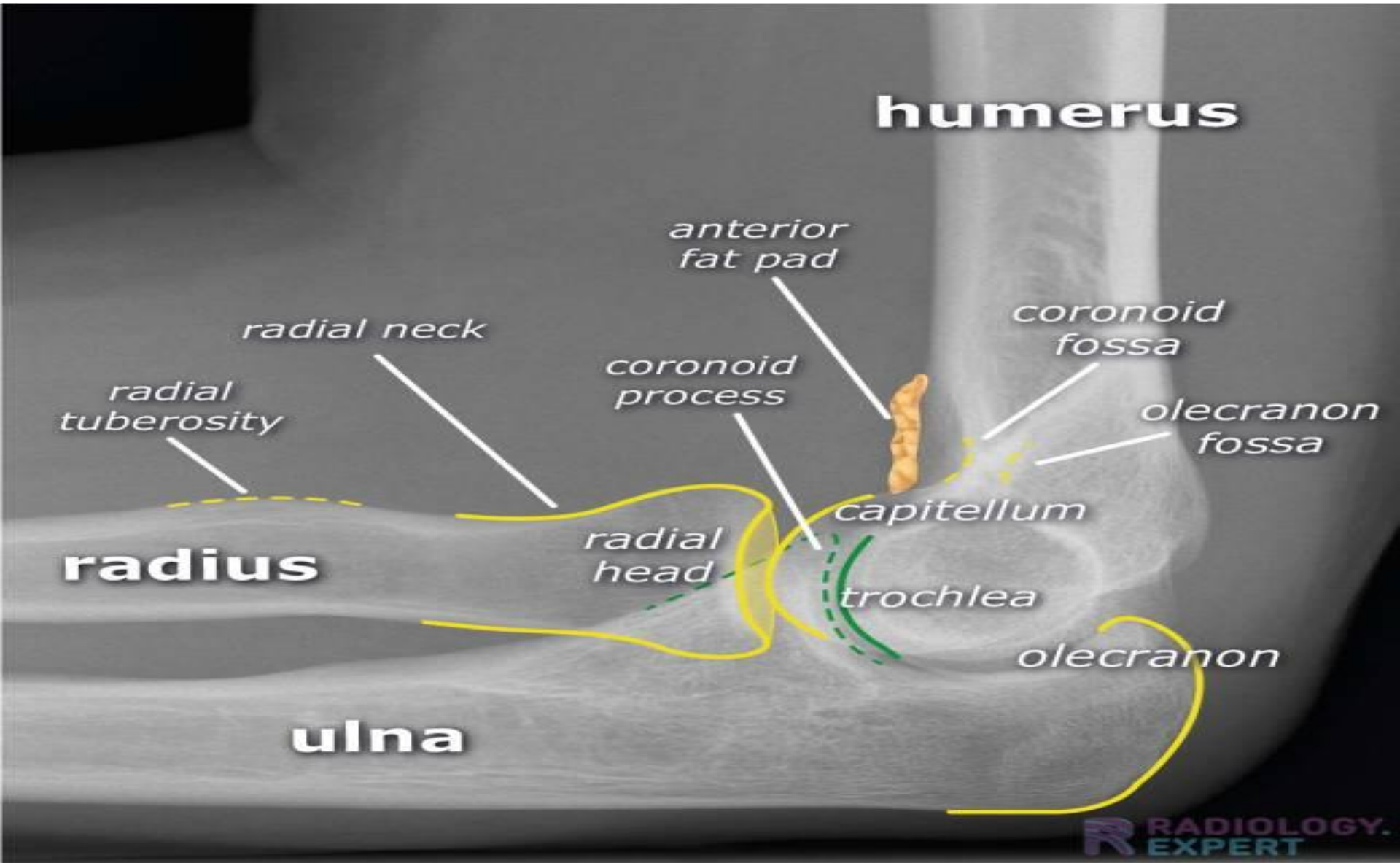

AP VIEW

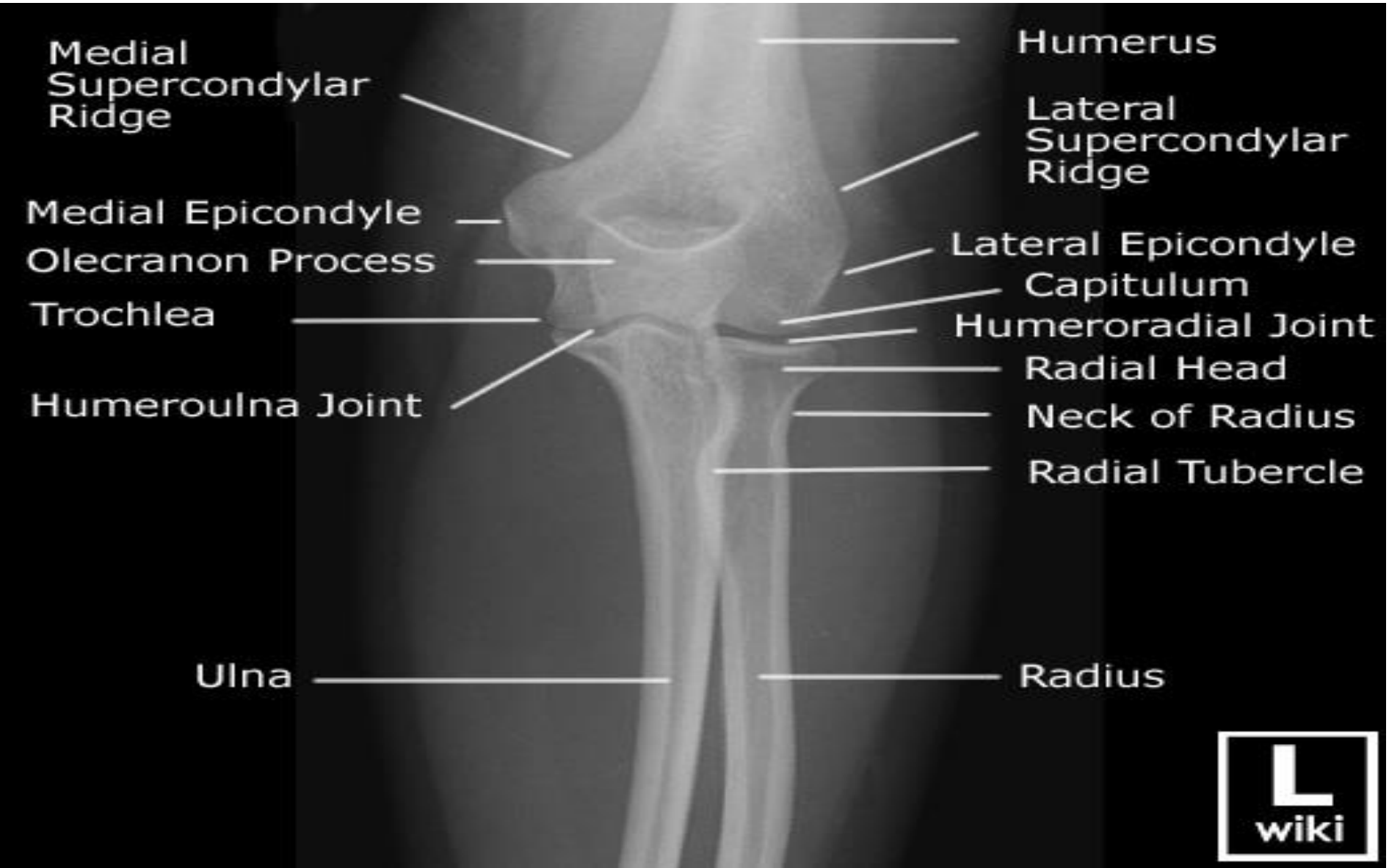
Medial Supercondylar Ridge
Medial Epicondyle
Olecranon Process
Trochlea
Humeroulna Joint
Ulna
Humerus
Lateral Supercondylar Ridge
Lateral Epicondyle
Capitulum
Humeroradial Joint
Radial Head
Neck of Radius
Radial Tubercle
Radius
L
wiki

Radius & ulna
AP & LAT

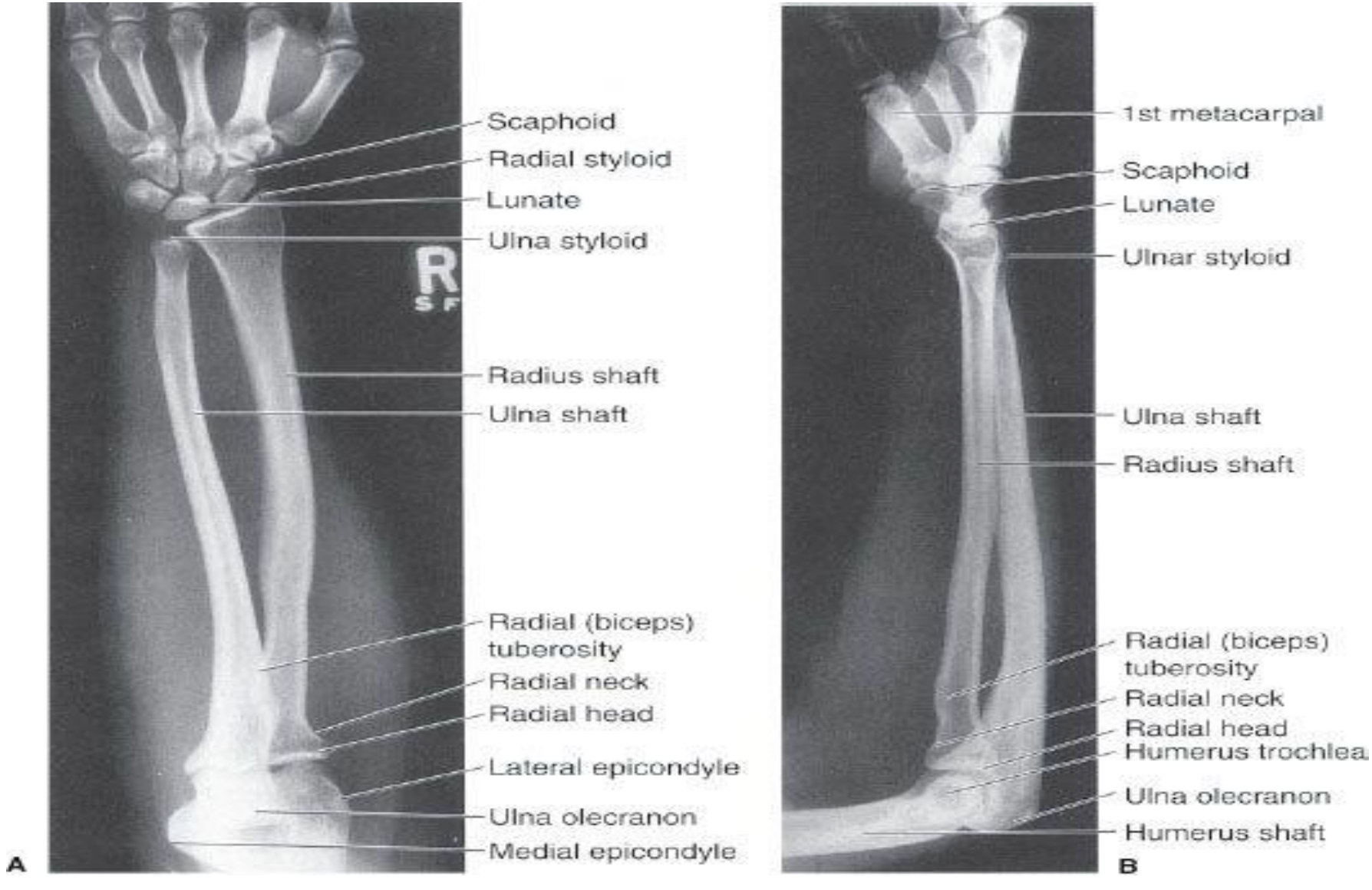

CT DISTAL RADIUS & ULNA



CT DISTAL RADIUS & ULNA



MRI ELBOW JOINT

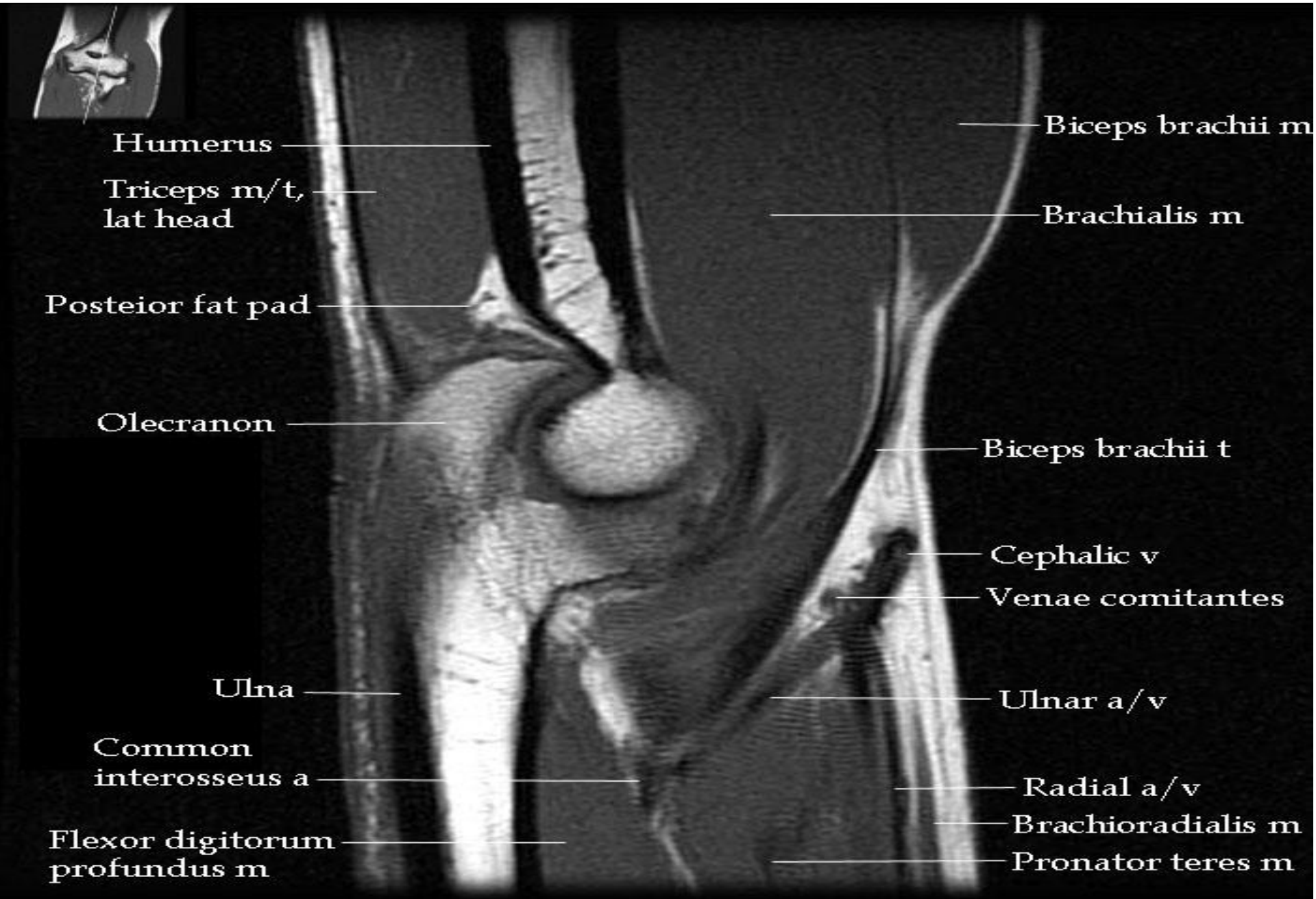

MRI

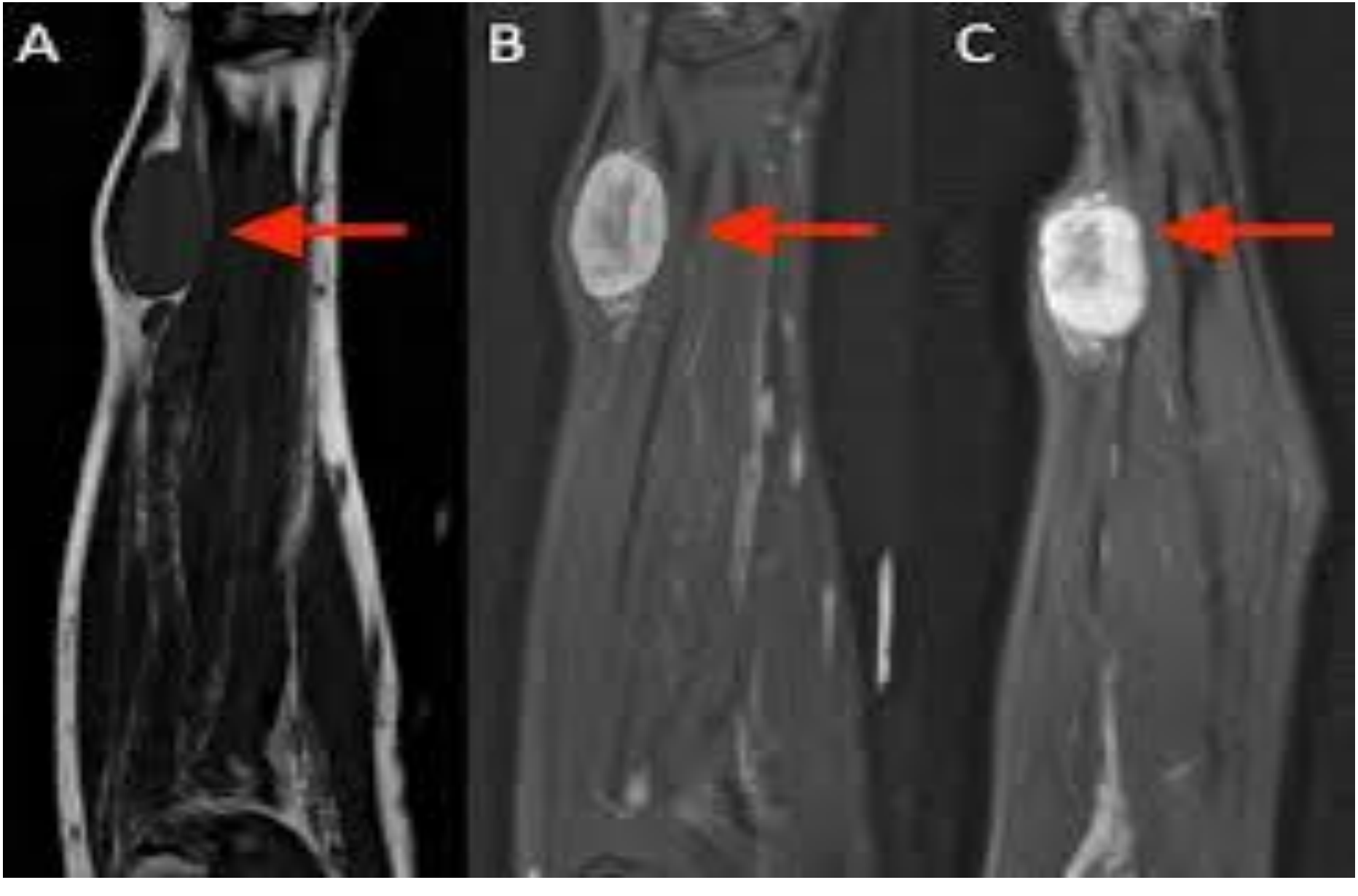

MRA

