Skeletal system

❖ Parts of the skeletal system

1. Bones (skeleton)
2. Joints
3. Cartilages
4. Ligaments(bone to bone) and Tendon(bone to muscle)

Bones (skeleton)

- Classification of Bones :

1.long 2.short 3.flat 4.irregular

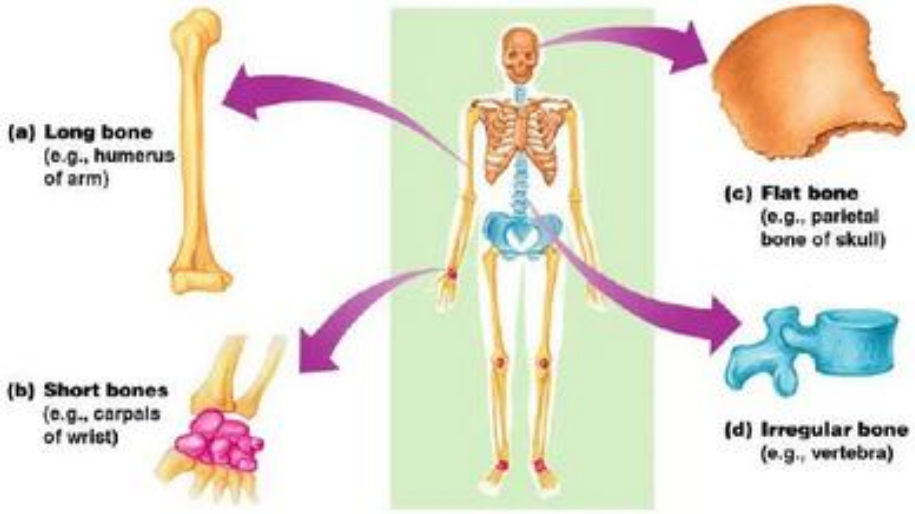

❖ skeletal system Divided into two divisions

1. Axial skeleton
   - ✓ Skull
   - ✓ Vertebral column
   - ✓ Thorax

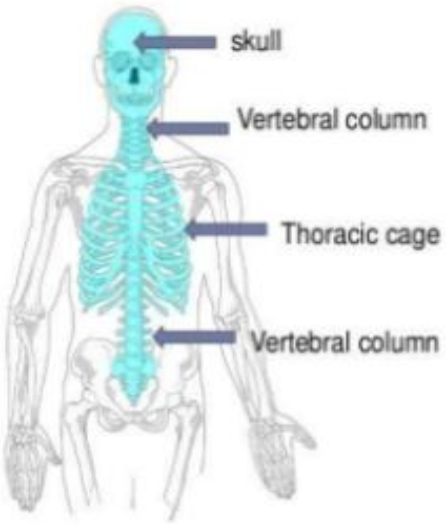

2. Appendicular skeleton
    - ✓ Limb
    - ✓ girdle

Two basic types of bone tissue

1) Compact bone (Homogeneous)
2) Spongy bone

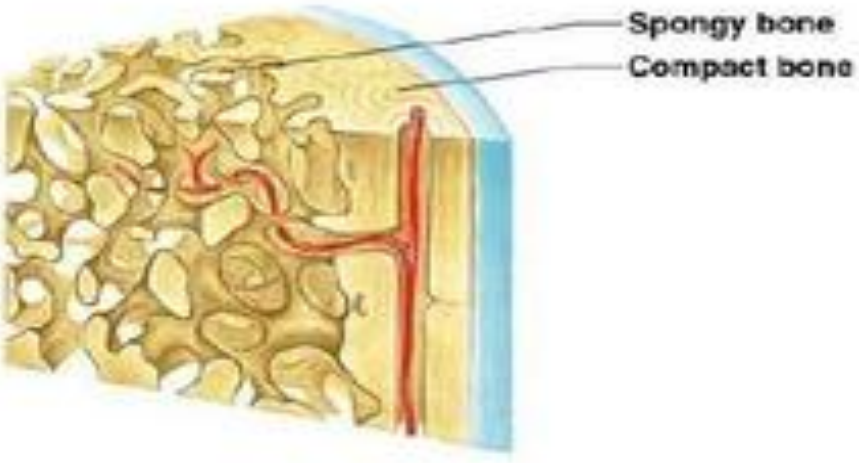

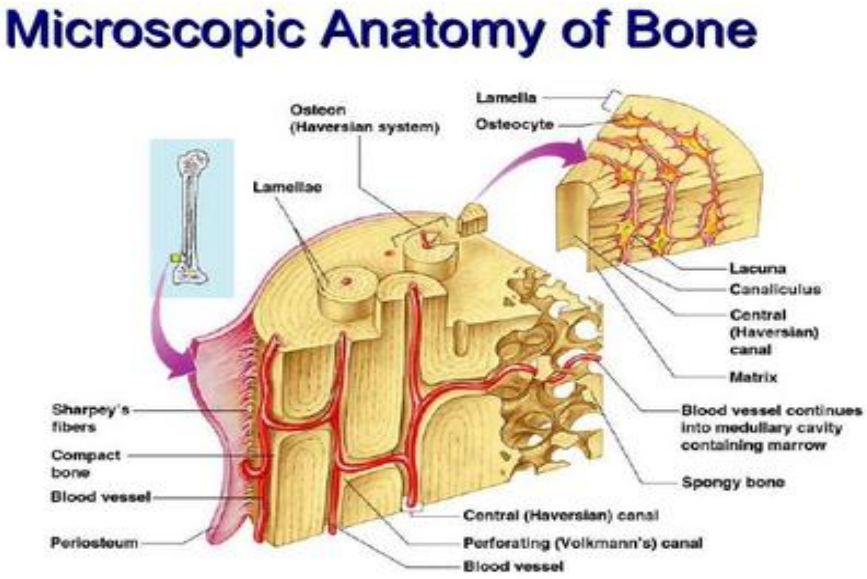

Structure of a Long Bone

1) Diaphysis
   - ✓ Shaft
   - ✓ Composed of compact bone
2) Epiphysis
   - ✓ Ends of the bone
   - ✓ Composed mostly of spongy bone
3) Periosteum
   - ✓ Outside covering of the diaphysis
   - ✓ Fibrous connective tissue membrane
   - ✓ Sharpey's fibers Secure periosteum to underlying bone

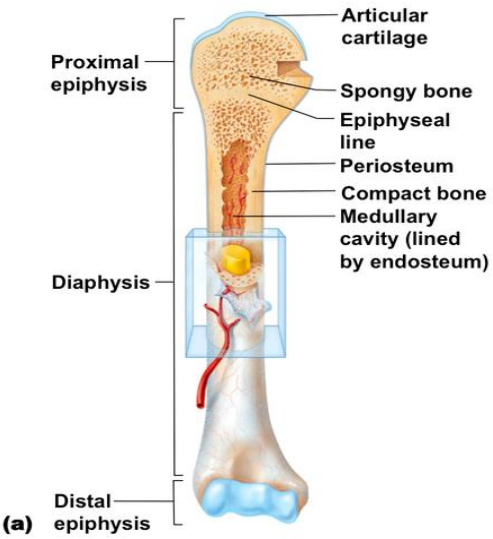

Types of bone fractures

1) Closed (simple) fracture – break that does not penetrate the skin
2) Open (compound) fracture – broken bone penetrates through the skin

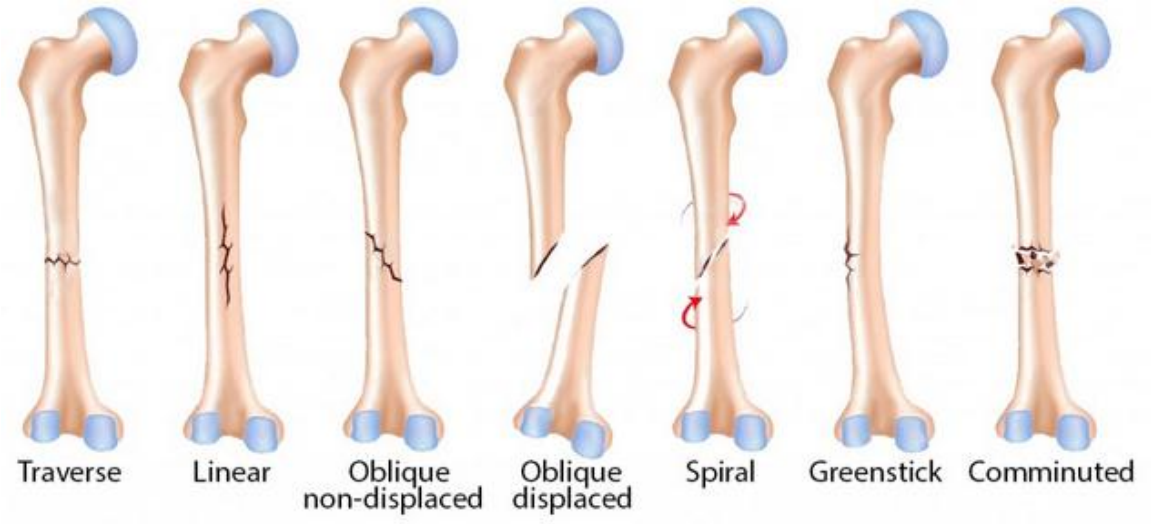

❖ Several types of fracture patterns:

- **Avulsion Fracture:** when a fragment of bone is separated from the main mass.
- **Comminuted Fracture:** the bone breaks into several pieces.
- **Compression or Wedge Fracture:** usually involves the bones in the back (vertebrae).
- **Greenstick Fracture:** an incomplete fracture in which the bone is bent; occurs most often in children.
- **Linear Fracture:** the break is parallel to the bone's long axis.
- **Oblique Fracture:** the break has a curved or sloped pattern.
- **Spiral Fracture:** one part of the bone has been twisted at the break point.
- **Transverse Fracture:** the broken piece of bone is at a right angle to the bone's axis.

❖ *The skull*

Component of skull

1) **The cranium parts :** 8 sutured bones

□ Parietal (2) □ Temporal (2) □ Frontal (1) □ Occipital (1)

□ Ethmoid (1) □ Sphenoid (1)

2) **Facial parts** : 13 sutured bones

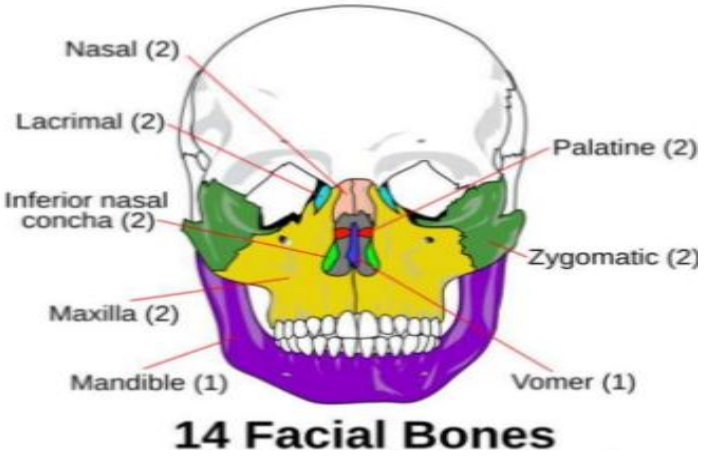

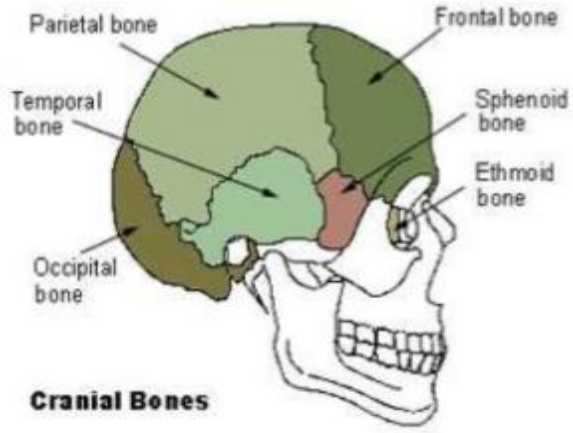

❖ *The Vertebral Column*

- Vertebral Column divided in to :

7 cervical

12 thoracic

5 lumbar

1 sacrum (5 fused)

1 coccyx (4 fused)

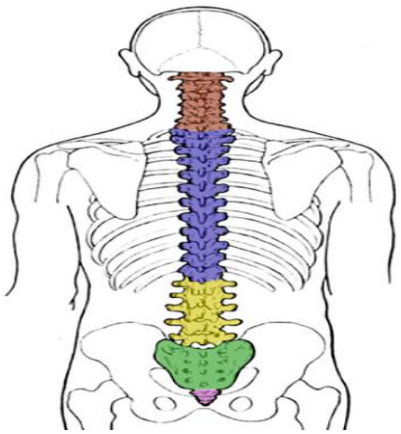

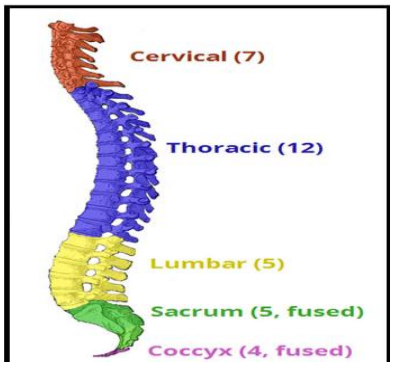

❖ *Thorax (chest)*

❖ Location of Thorax

located between the neck and abdomen.

❖ Components of Thorax:

1) Thoracic cavities

2) Neurovasculature

3) Internal organs
- Heart
- Trachea
- esophagus
- lungs

Thoracic cavity

- The thoracic cavity consist of :

1. sternum
2. twelve pairs of ribs
3. twelve thoracic vertebrae

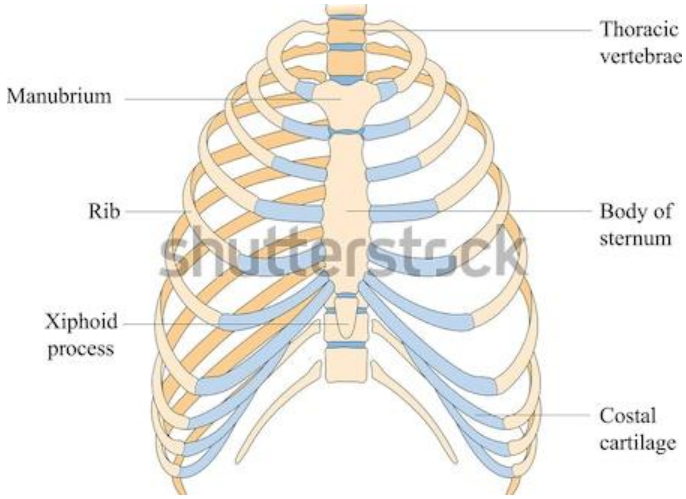

Sternum

It consists of parts:

- **The manubrium sterni:** upper part of the sternum
- **The body of the sternum:** is the middle large part composed of 4 pieces that fuse in one bone .
- **The xiphoid process**: the lower smallest part of the sternum.

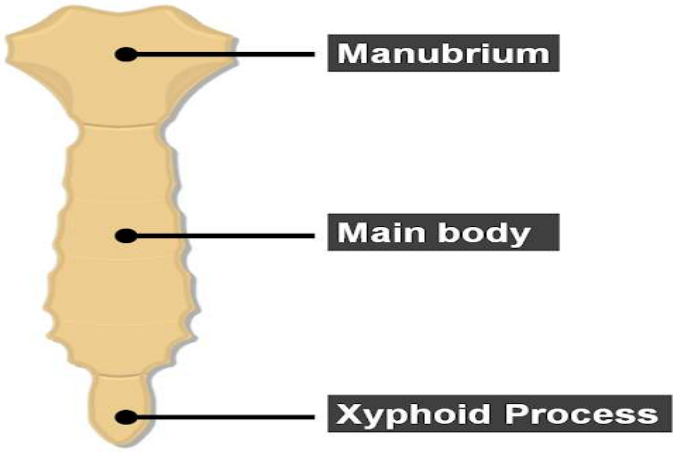

twelve pairs of ribs

- True ribs (first seven pairs)
- false ribs (Three pairs)
- Two pairs of floating ribs

