Limbs

☒ ***Upper Limb***

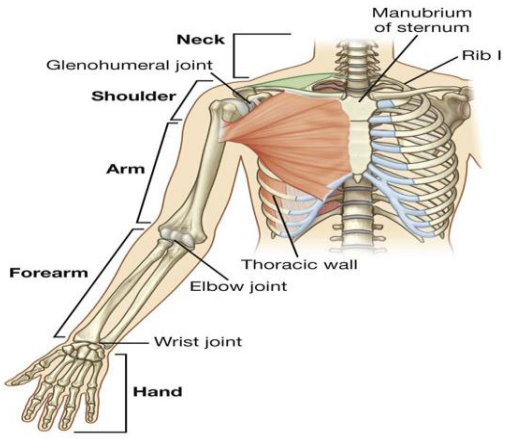

The upper limb consist of :

1) Shoulder
2) Arm (Humerus)
3) Forearm
4) Hand

Shoulder

1. The scapula

1) two surfaces Anterior Surface and Posterior Surface
2) Three Borders: superior, medial (vertebral) & lateral
3) Three Angles: superior, lateral and inferior.

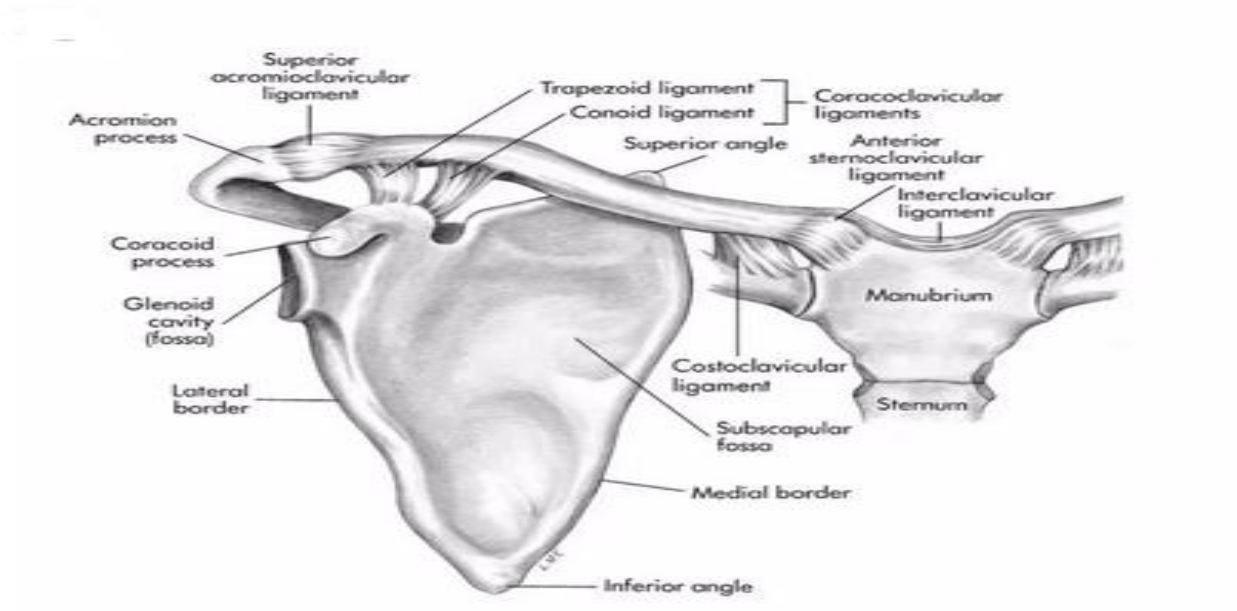

2. The clavicle (collarbone)

- Location: sits between the shoulder and top of the thorax
- Sternal end articulates with the manubrium
- Acromial end articulates with scapula

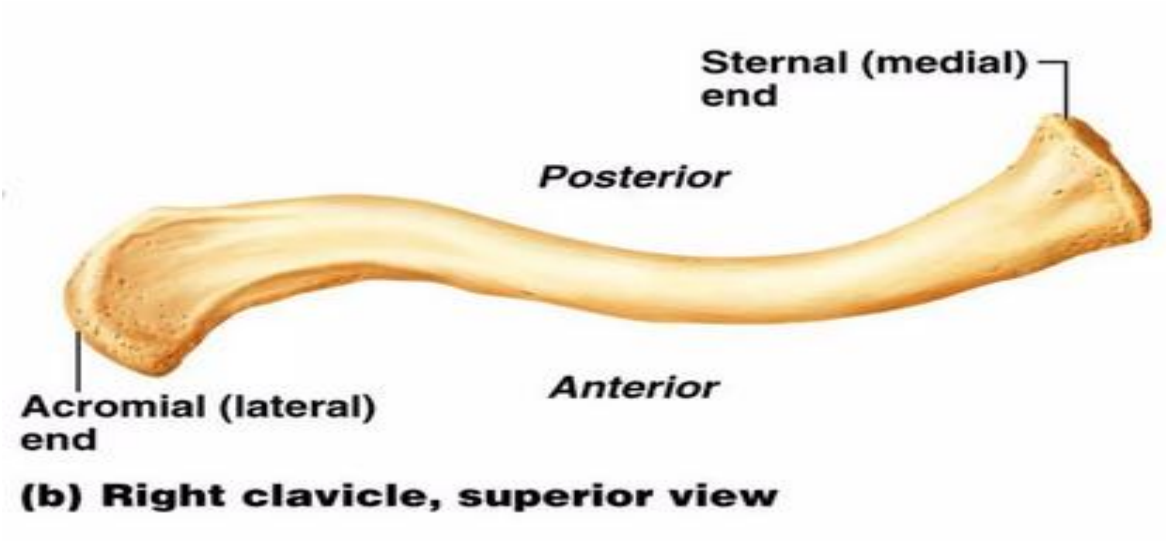

(b) Right clavicle, superior view

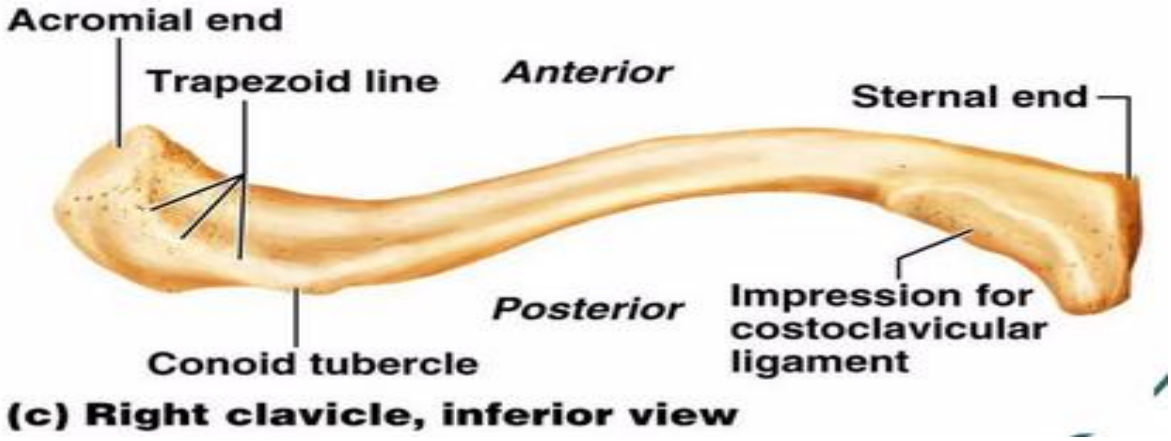

(c) Right clavicle, inferior view

The humerus

- joint with scapula at the shoulder joint
- joint with the radius and ulna at the elbow joint
- It has:

1) Upper end

Head: Smooth& forms 1/3 of a sphere.

Anatomical Neck: Immediately below the head

Surgical Neck: between the upper end and thes haft.

2) Lower end

Medial : Trochlea.

Lateral: Capitulum

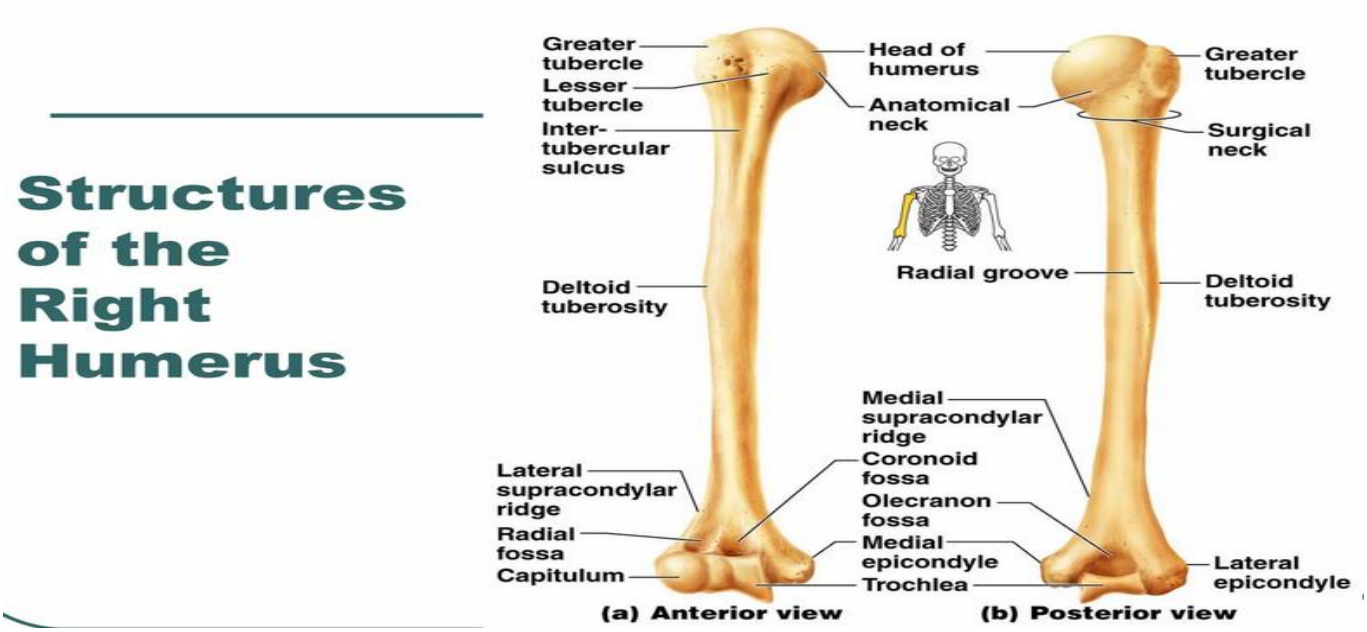

Forearm

- Forearm consist of :

  1- Radius

  2- Ulna

- joint with the humerus at the elbow joint
- joint with carpals at the wrist joint
- Radius and ulna articulate with each other
  - At the proximal and distal radioulnar joints
- The interosseous membrane
  - Interconnects radius and ulna

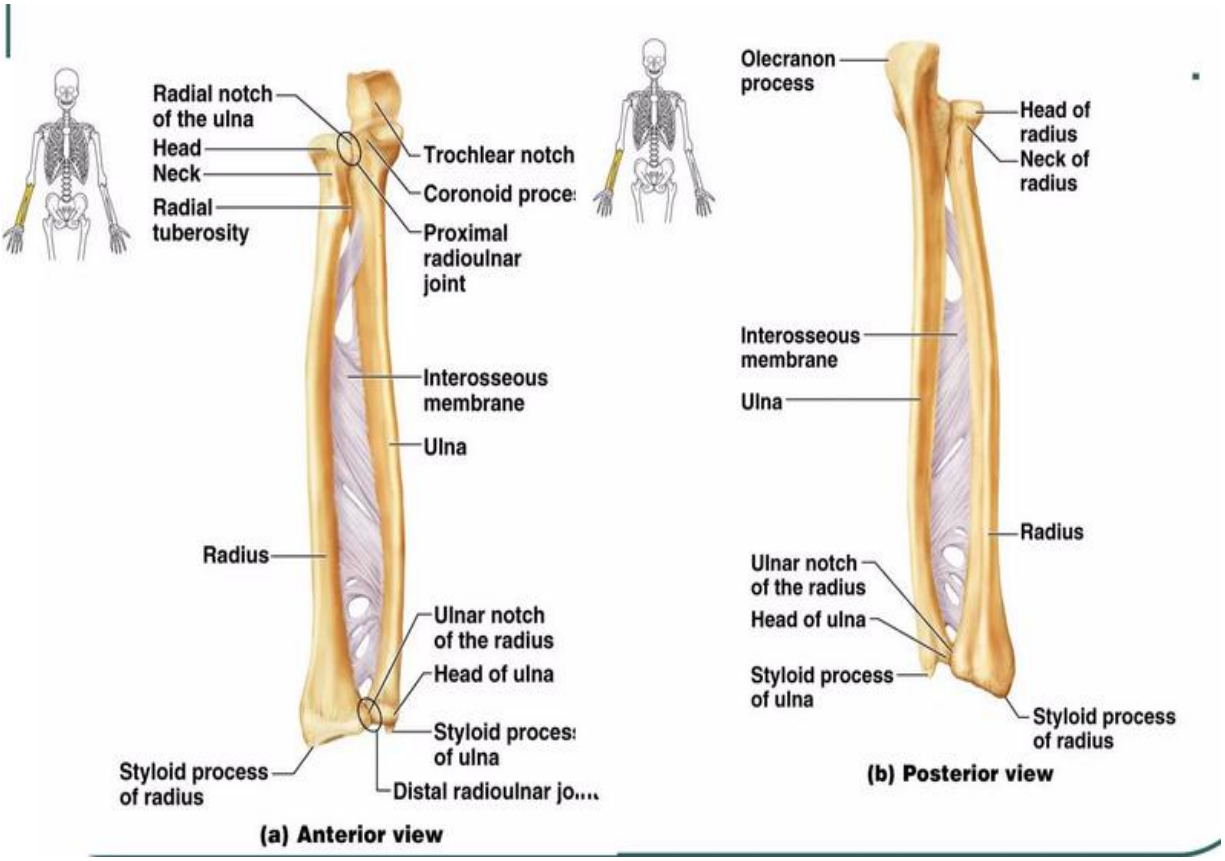

Details of Elbow Joint

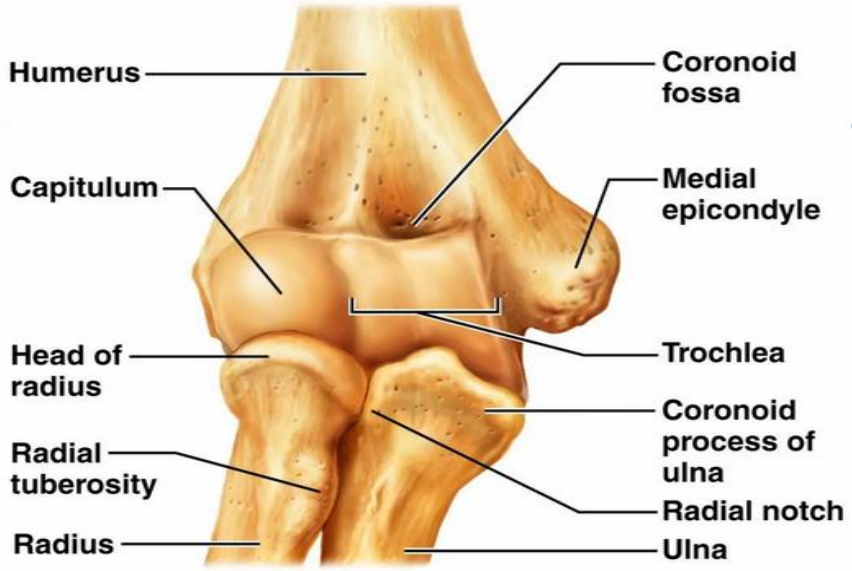

(a) Anterior view

Proximal Ends of Radius and Ulna

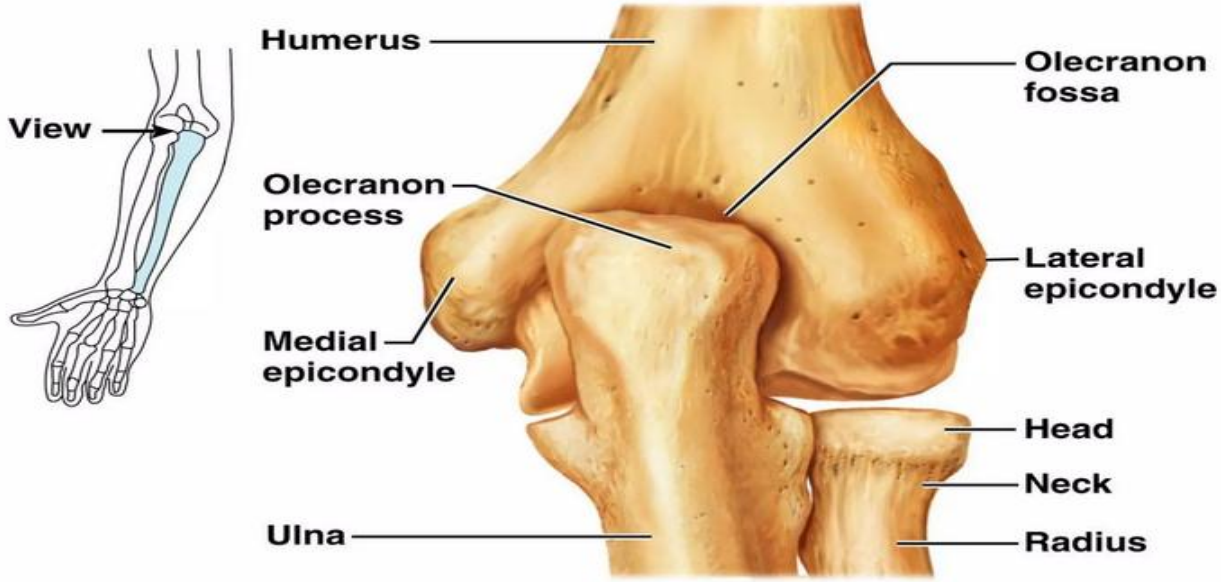

(c) Posterior view

Hand

The Hand consist of :

1. *carpals* : eight small bones
2. *metacarpals*: five bone
3. *phalanges*

Carpal bones

- Are arranged in two irregular rows
- Proximal row from lateral to medial
  - Scaphoid, lunate, triquetral, and pisiform
- Distal row from lateral to medial
  - Trapezium, trapezoid, capitate, and hamate

