The skin

- **Layers of Skin:**

1) The epidermis: outermost superficial region

2) The dermis: middle region

3) Hypodermis (subcutaneous tissue): deepest region

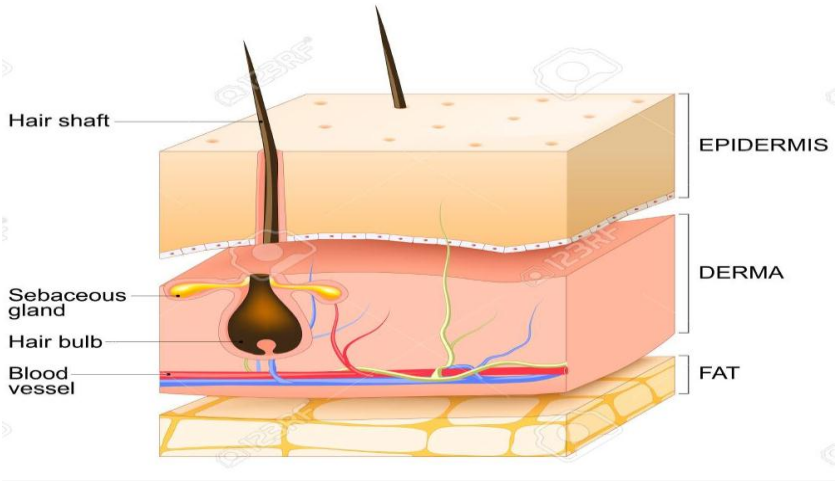

Epidermis :

1. Outer layer of skin
2. No blood vessels
3. Highly enervation
4. Composed of keratinized stratified squamous epithelium tissue
5. Composed of Five layers

Type of cells in Epidermis are :

- Keratinocytes: Produce keratin for strength
- Melanocyte cell: – produce the brown pigment *melanin*
- Merkel's cells – function as touch receptors in association with sensory nerve endings
- Langerhans' cells – epidermal macrophages that help activate the immune system

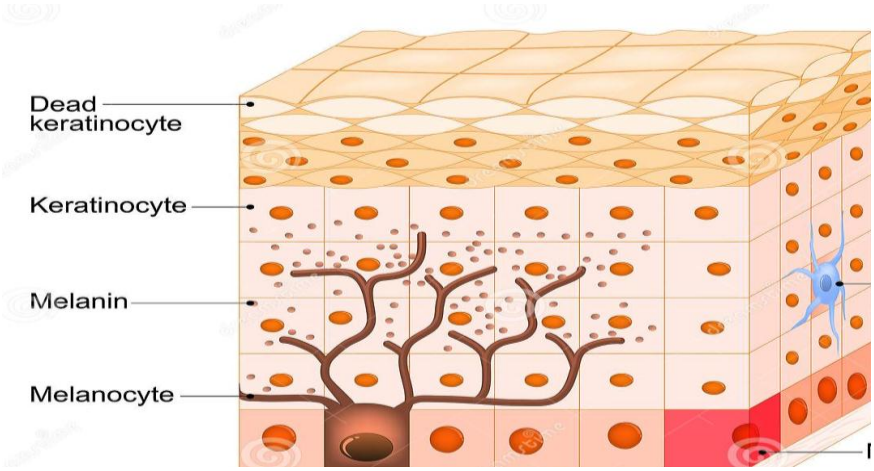

Dermis:

- Second major skin region containing strong, flexible connective tissue
- Composed of two layers – papillary and reticular
- contain :
    1) blood vessels and nerves
    2) Oil glands ،Sweat glands and Hair follicles
    3) Fat tissue and Connective tissue

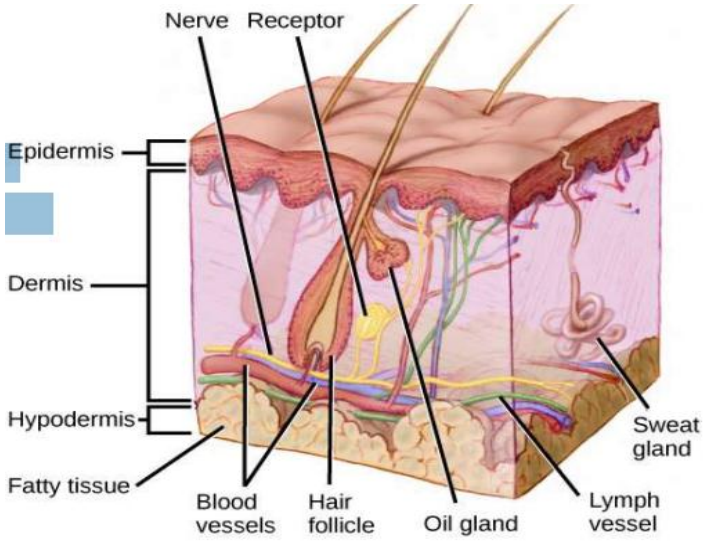

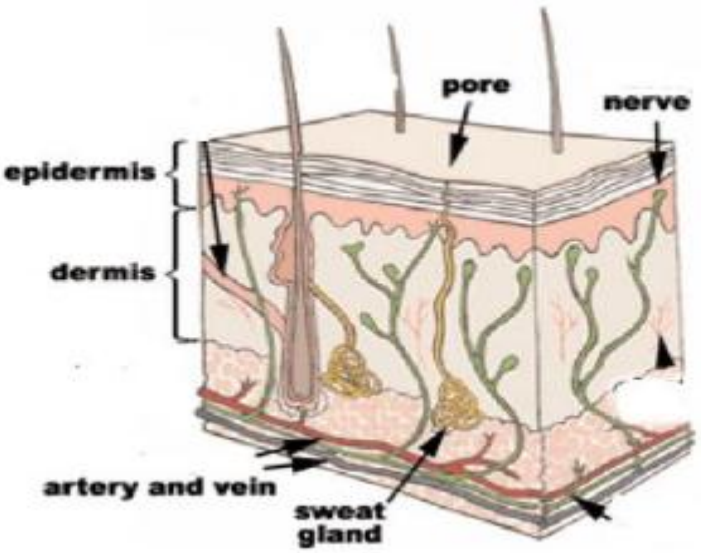

- Hair Structure
  - Shaft : Superficial portion
  - Root : Below the surface
  - Cuticle : Outermost layer of hair
- Papillary layer
  - Areolar connective tissue with collagen and elastic fibers
  - Its superior surface contains peg like projections called *dermal papillae*

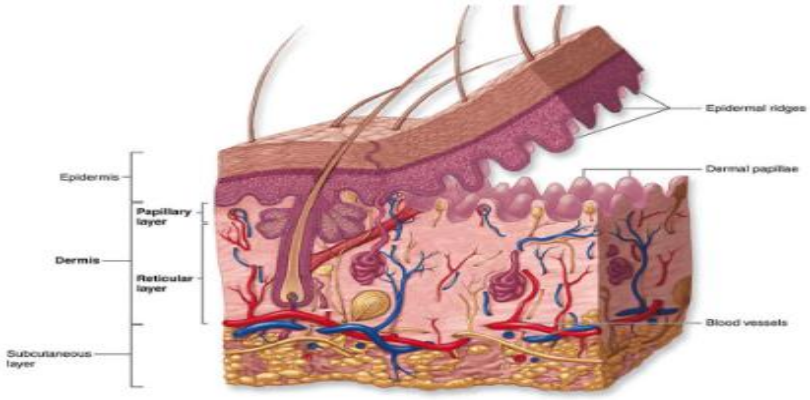

- Reticular layer
    - 80% of the thickness of the skin
    - Collagen fibers in this layer provide strength to the skin
    - Elastin fibers provide stretch properties

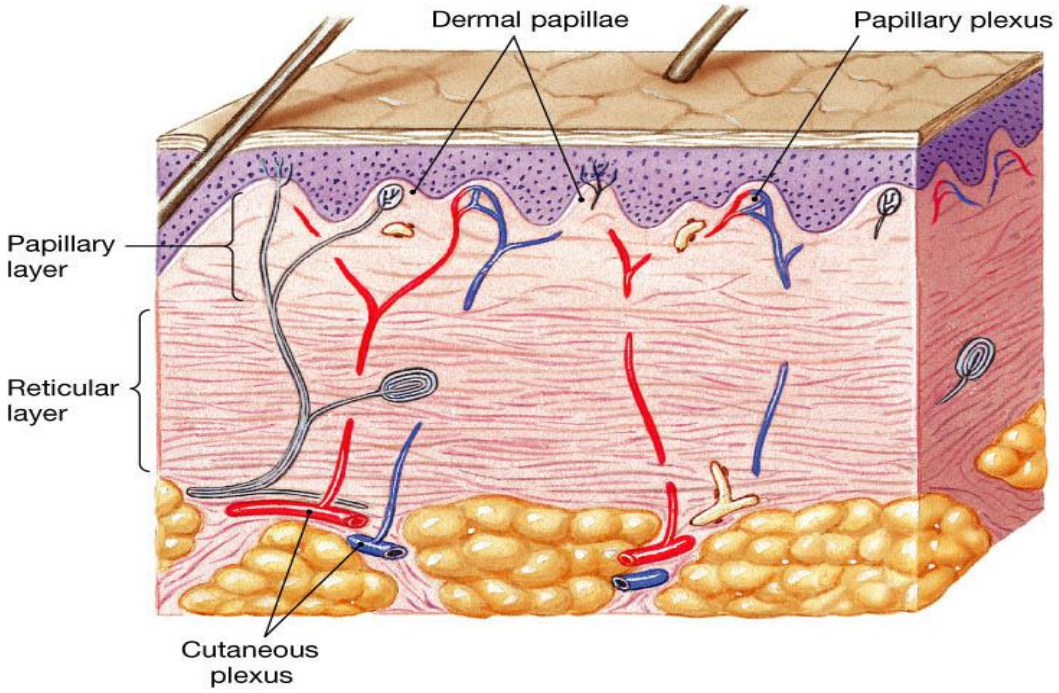

Type of cells in dermis are :

- Fibroblasts
- Mast cell
- Macrophages
- white blood cells

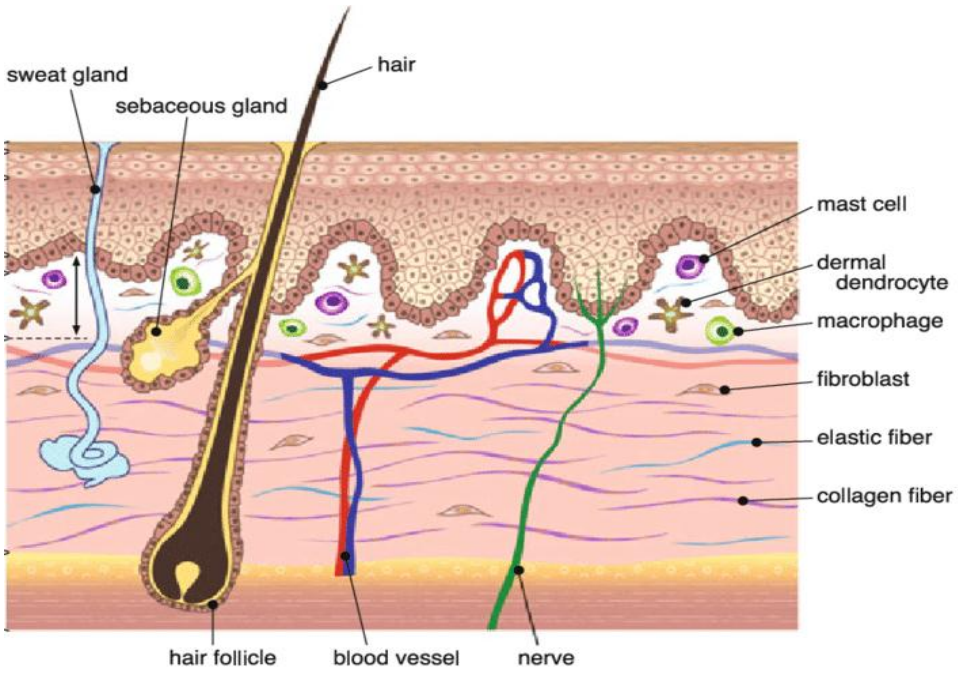

Hypodermis:

- contain Fat, blood vessels
- type of cells :Macrophages and Fibroblast
- Composed of adipose and areolar connective tissue

