Three Parts of Small Intestine

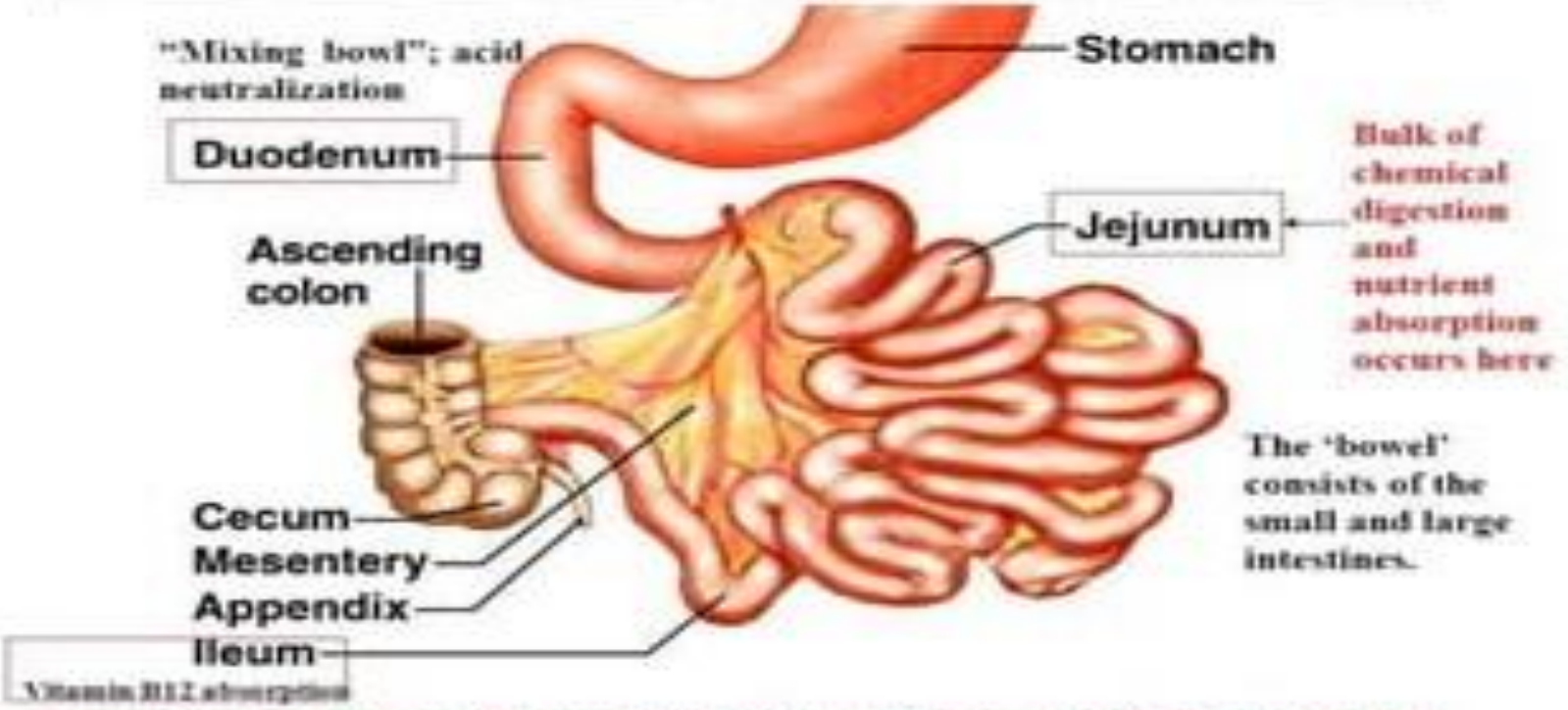

Main functions of small intestine: 1) chemical digestion 2) absorption of nutrients (90%) from chyme

SMALL AND LARGE INTESTINES

Mechanical obestruction

1-Volvulus is a twisting of a segment of bowel onits vascular mesentery, causing

intestinal obstruction and infarction

الأمعاء الدقيقة والكبيرة
الانسداد الميكانيكي



1- الانفتال هو التواء جزء من الأمعاء على مساريقها الوعائية

مما يسبب انسداد معوي واحتشاء

2-Intussusception is the telescoping of a proximal segment of the bowel into the distal segment. It is most common in infants andchildren.

1- **الانغلاف هو تداخل الجزء القريب من**



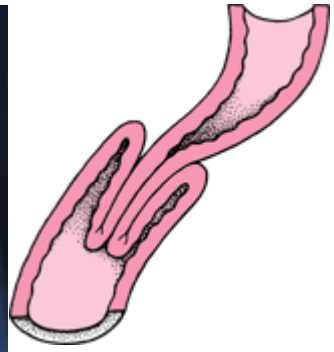

الأمعاء في الجزء البعيد. وهو أكثر شيوعًا عند الرضع والأطفال.

3-Incarcerated hernia is a segment of bowel that is imprisoned within a hernia; the condition can become complicated byintestinal obstruction and infarction. **1- الفتق المنعزل هو جزء من الأمعاء المحبوس داخل الفتق. يمكن أن تصبح الحالة معقدة بسبب انسداد الأمعاء والاحتشاء.**

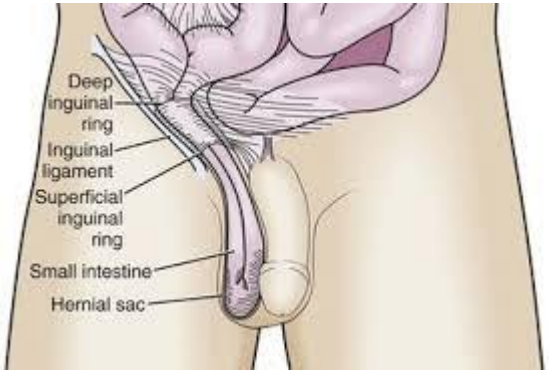



Small Bowel – Causes of Obstruction

- Hernias
- Adhesions

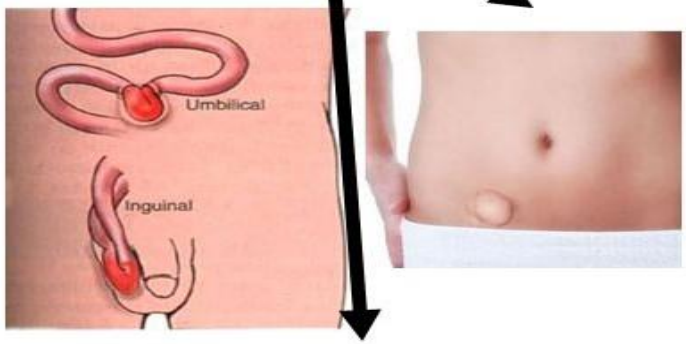



- Intussusception
- Volvulus

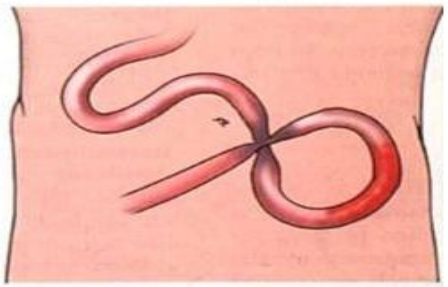





Malabsorption Syndromes

Celiac sprue (or **gluten-sensitive enteropathy** and nontropical sprue) is caused by hypersensitivity to gluten (and gliadin), resulting

in loss of small bowel villi and

malabsorption ينجم الذرب البطني (أو الاعتلال المعوي الحساس للجلوتين والذرب غير الاستوائي) عن فرط الحساسية للجلوتين (والجلياديين)، مما يؤدي إلى فقدان الزغابات المعوية الدقيقة وسوء الامتصاص.

Biopsy shows blunting of villi and a lymphocytic infiltrate.

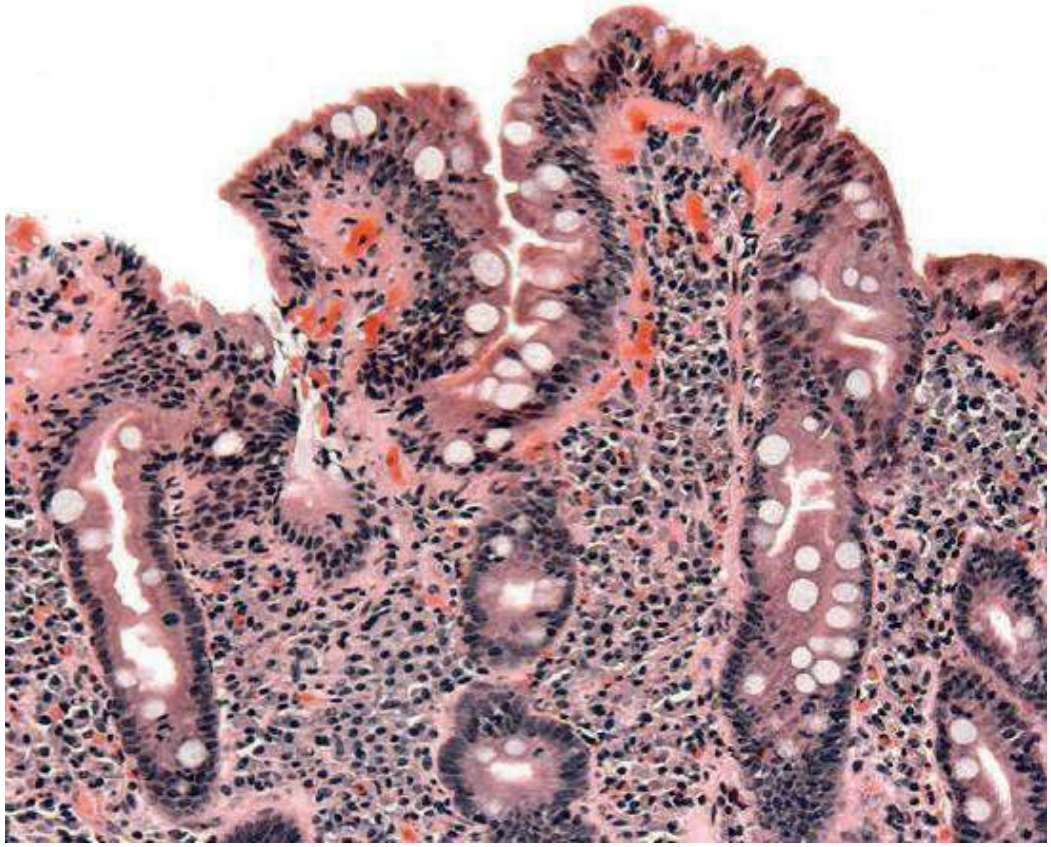

Small Bowel – Ischemia



- Predisposing Conditions
  - Arterial thrombosis
    - Atherosclerosis
    - Vasculitis
  - Arterial embolism – vegetation
  - Venous thrombosis – hypercoagulable
  - Non-occlusive – shock
  - Miscellaneous - volvulus



Inflammatory bowel disease IBD

1-ULCERATIVE COLITIS

2-Crohn;s disease

Small Bowel - Inflammatory Bowel Disease (IBD)

- Ulcerative Colitis
- Crohn's Disease

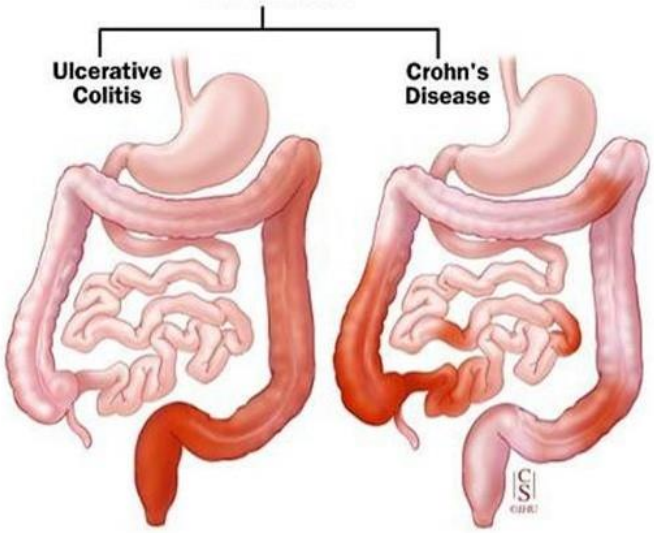

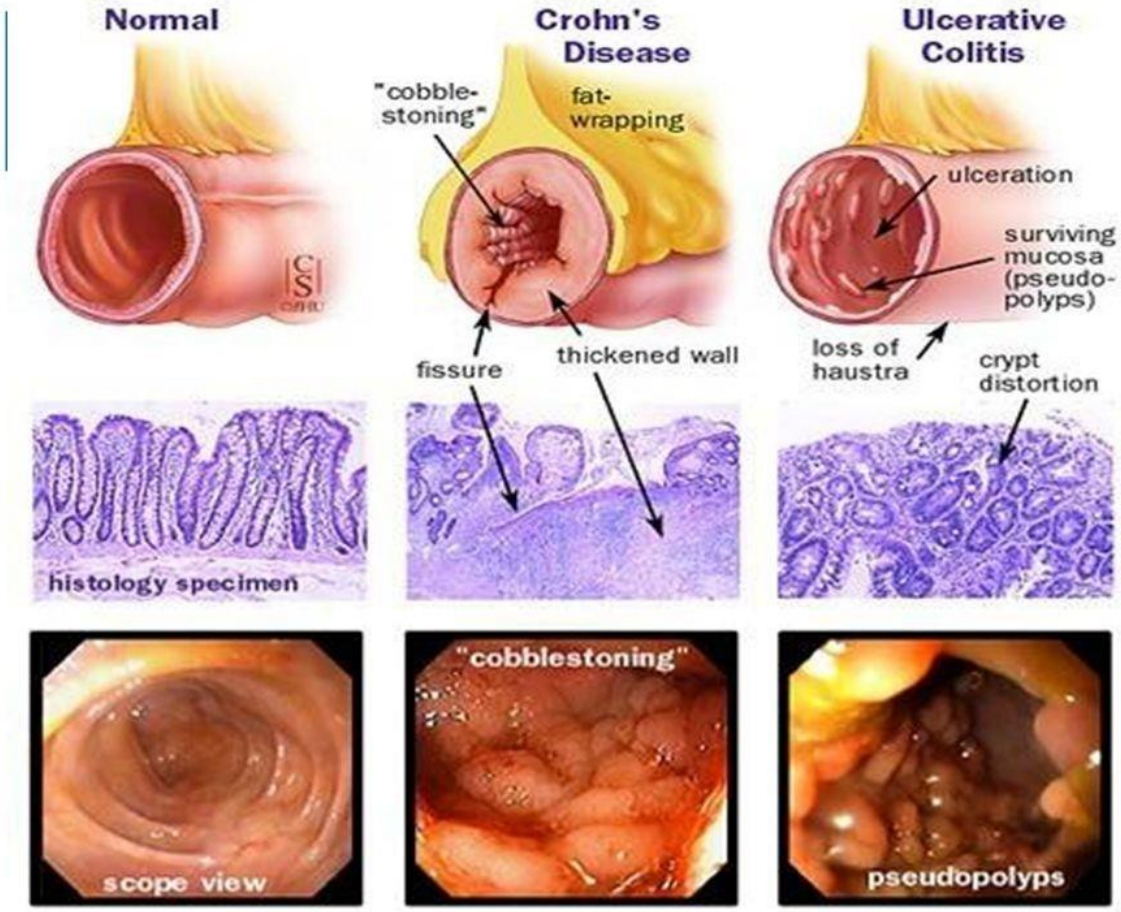
Normal
Crohn's Disease
Ulcerative Colitis
"cobble-stoning"
fat-wrapping
ulceration
surviving mucosa (pseudo-polyps)
fissure
thickened wall
loss of haustra
crypt distortion
histology specimen
"cobblestoning"
scope view
pseudopolyps

Small Bowel – Tumors

- < 6% GI tumors
- Benign
  - Leiomyoma
  - Adenoma
- Malignant
  - Adenocarcinoma
  - Neuroendocrine
  - Lymphoma
  - Sarcoma

