SPINAL CORD INJURIES

By

Dr. Sajjad M Alhakeem

F.I.B.M.S (Urology)



- Adults typically have 33 vertebrae, including:

- seven cervical vertebrae
- twelve thoracic vertebrae
- five lumbar vertebrae
- five sacral vertebrae (fused in adults to form the sacrum)
- four coccygeal vertebrae (fused to form the coccyx)

- An intervertebral disc sits between each vertebra. This provides a level of flexibility to the vertebral column.
- The cervical region is the most flexible area while the thoracic region is the least flexible

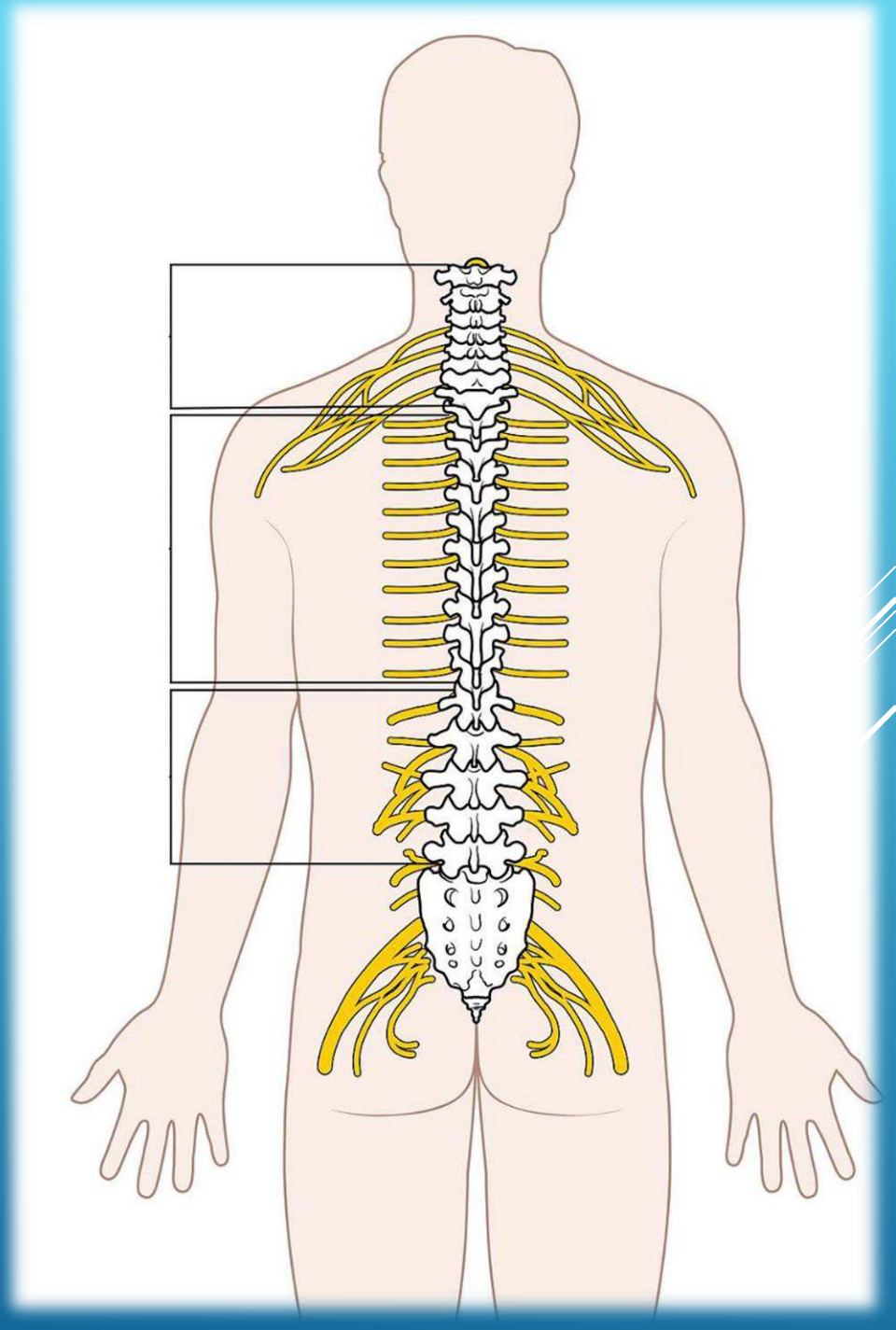

- The spinal cord extends from the foramen magnum to the lowest border of the first lumbar vertebra
- it transmits motor information from the brain to the muscles, tissues and organs
- In adults, the spinal cord is around 45 cm long.

- Humans have 31 pairs of spinal nerves:
- eight cervical
- twelve thoracic
- five lumbar
- five sacral
- one coccygeal



- Spinal cord injury (SCI) is an insult to the spinal cord resulting in a change, either temporary or permanent, in the cord's normal motor, sensory, or autonomic function.

- Complete: is characterized clinically as complete loss of motor and sensory function below the level of the traumatic lesion.

- Incomplete: syndromes have variable neurologic findings with partial loss of sensory and/or motor function below the level of injury

- The most common neurologic level of injury is C5. In paraplegia, T12 and L1 are the most common level

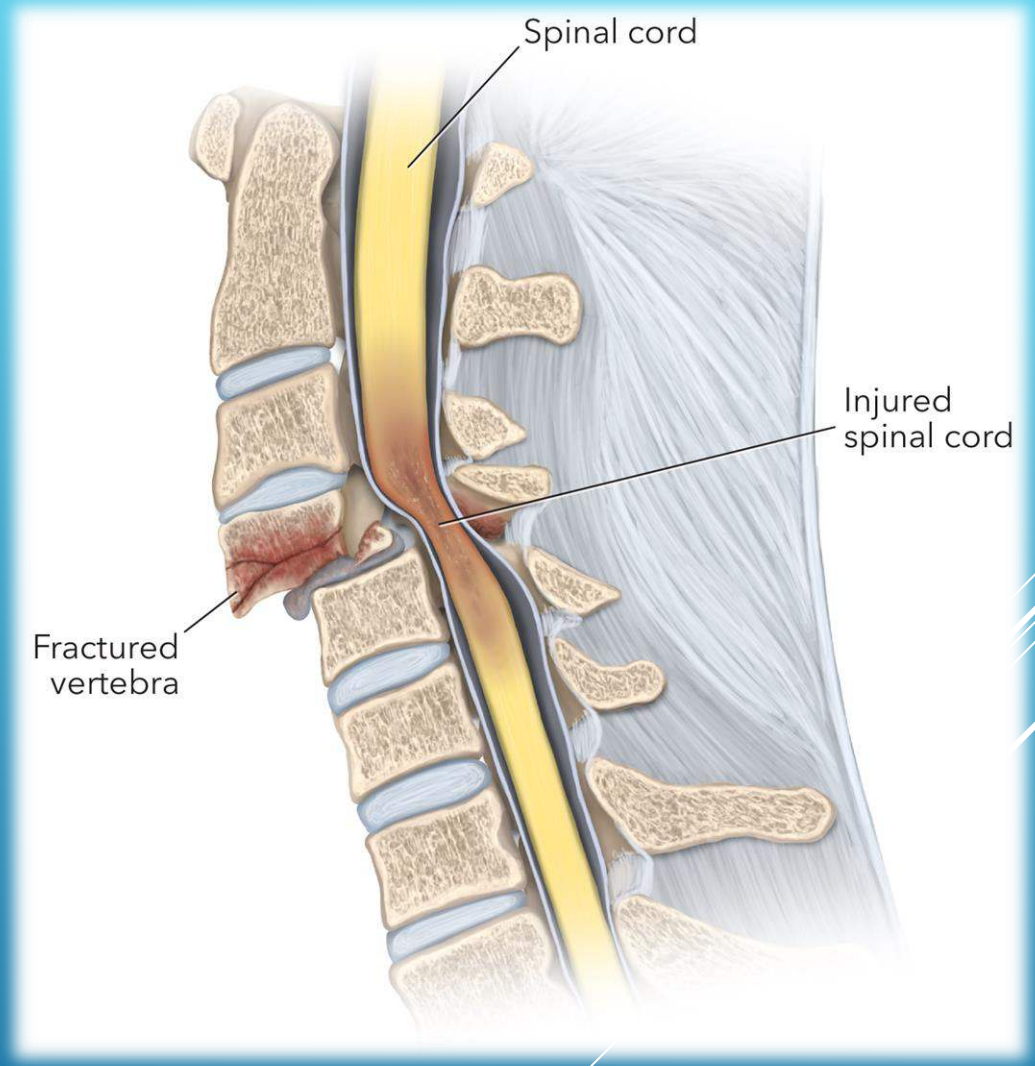

- quadriplegia: Injury to the spinal cord in the cervical region, with associated loss of muscle strength in all 4 extremities

- Paraplegia: Injury in the spinal cord in the thoracic, lumbar, or sacral segments, including the cauda equina and conus medullaris

- Approximately 10–20% of patients who have sustained an SCI do not survive to reach acute hospitalization, whereas about 3% of patients die during acute hospitalization.

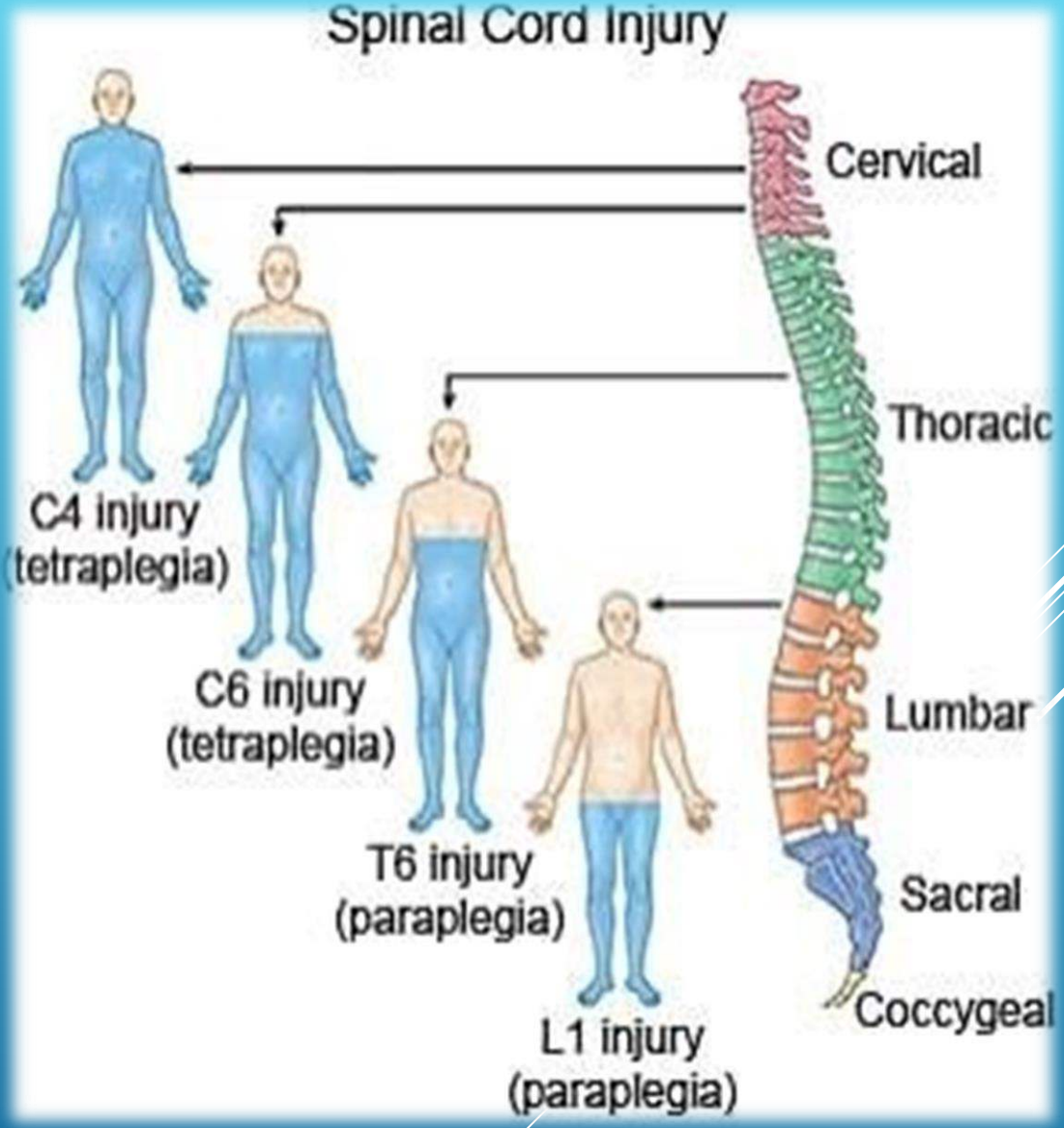

- Imaging techniques in spinal cord injury include the following

1. Plain radiography.

2. Computed tomography (CT) scanning : CT imaging is the gold standard for detecting fractures and bony injury

3. Magnetic resonance imaging (MRI) - Used for suspected spinal cord lesions, ligamentous injuries, and other soft-tissue injuries or pathology



- the most common causes of spinal cord injury :

(1) motor vehicle accidents

(2) falls, most common in those aged 45 years or older.

(3) interpersonal violence (primarily gunshot wounds)

(4) and sports in which diving is the most common cause

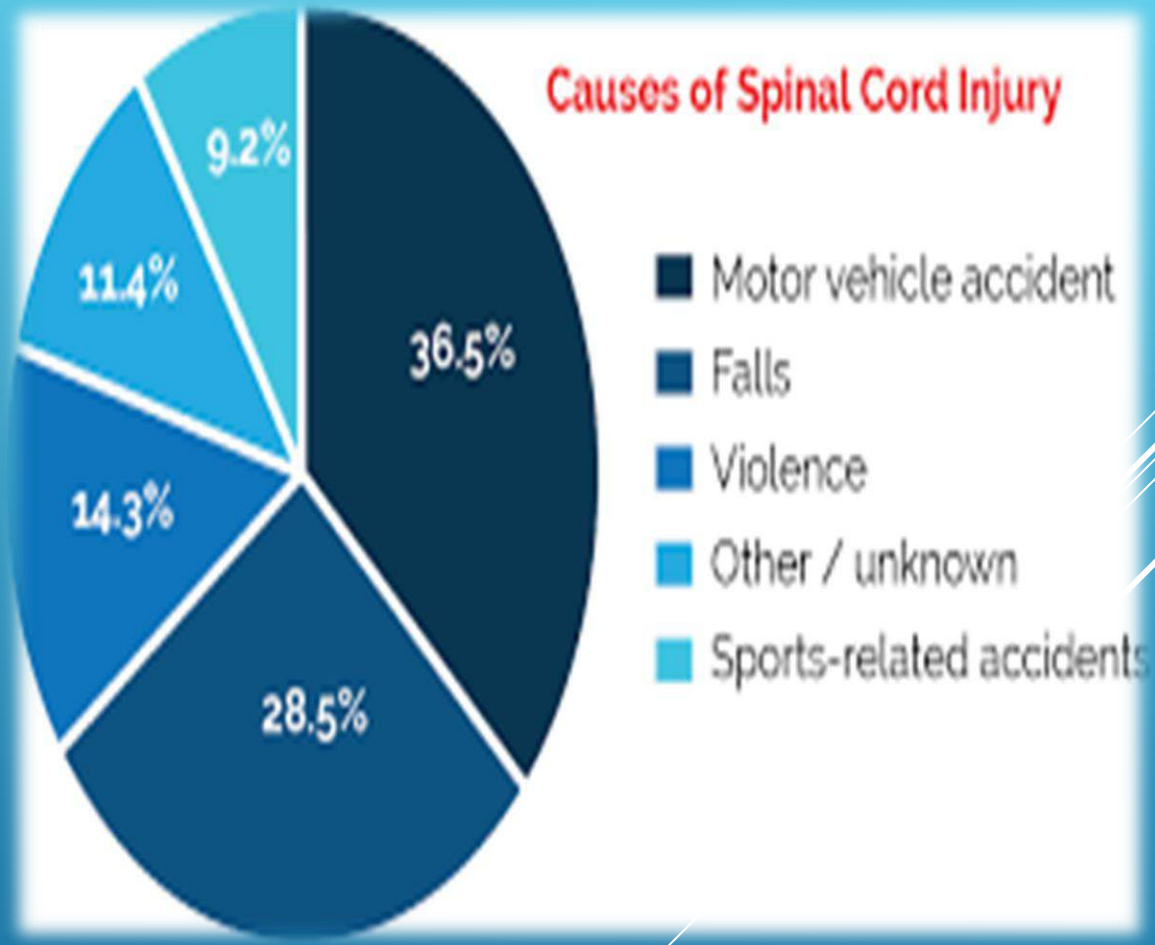

SCI can be sustained through different mechanisms, with the following 3 common abnormalities leading to tissue

1. Destruction from direct trauma
2. Compression by bone fragments, hematoma, or disk material
3. Ischemia from damage or impingement on the spinal arteries

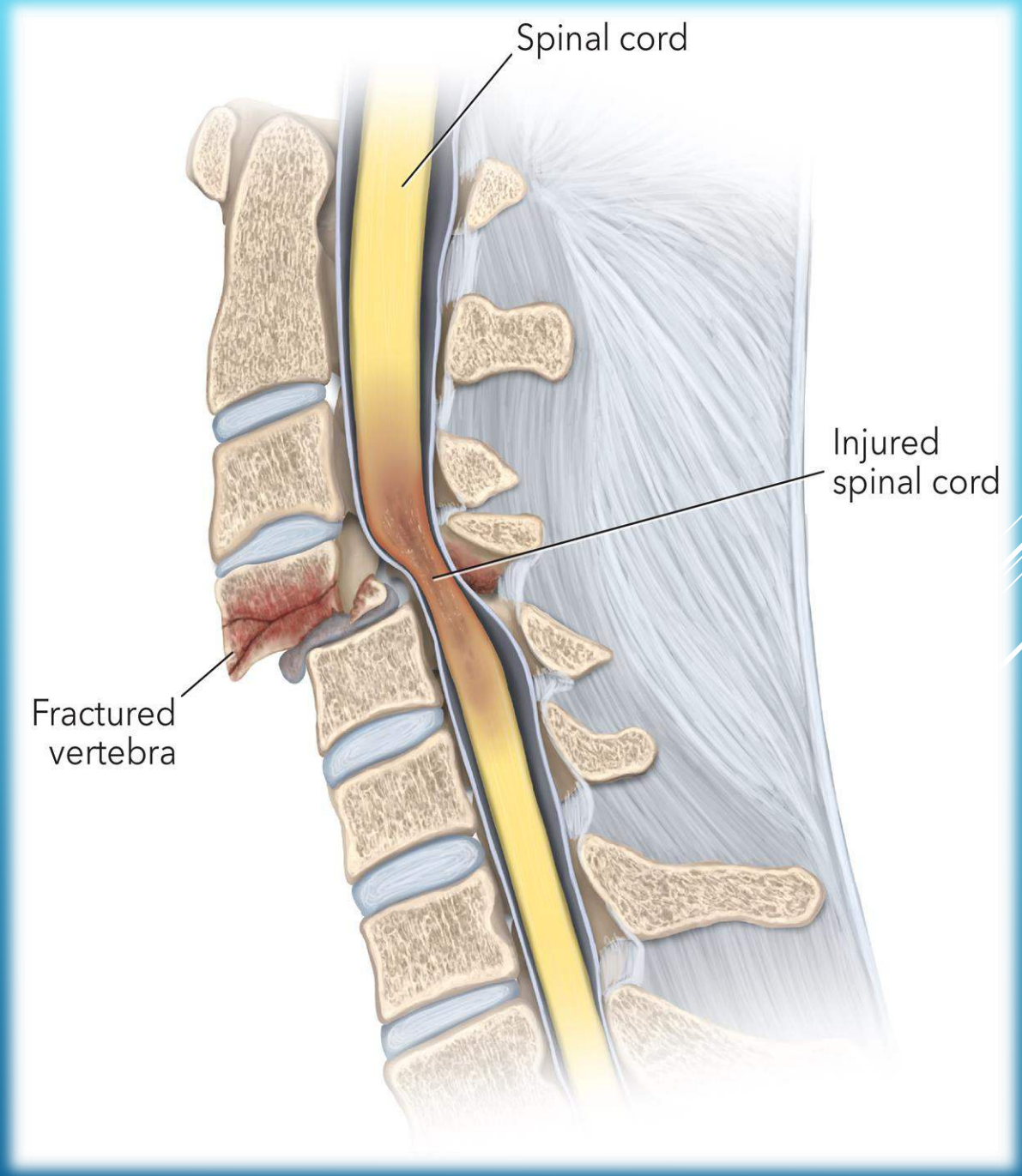

- Neurogenic shock refers to the hemodynamic triad of hypotension, bradycardia, and peripheral vasodilation resulting from severe autonomic dysfunction and the interruption of sympathetic nervous system control in acute SCI. Hypothermia is also characteristic. This condition is more common in injuries above T6

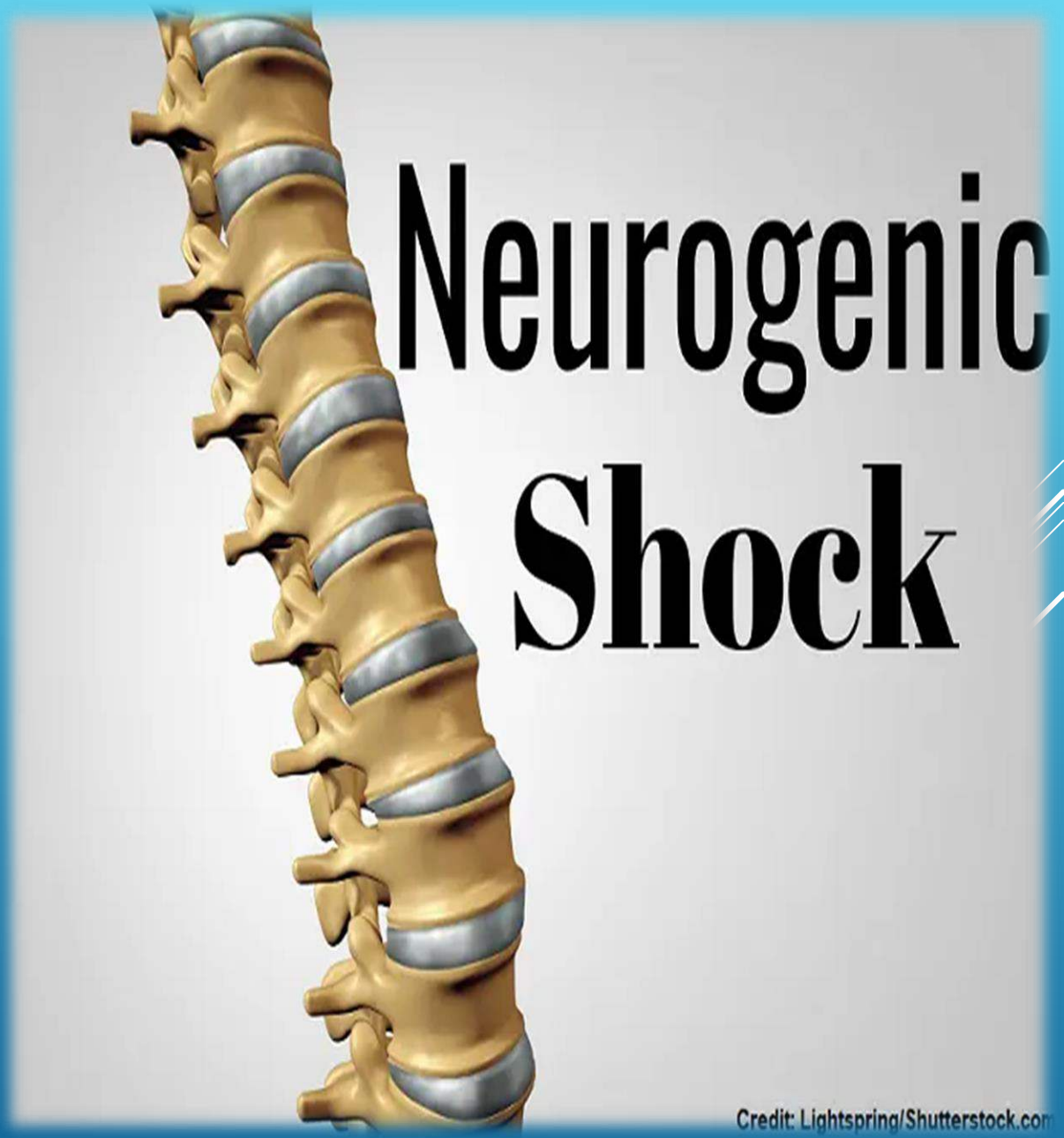

- **Airway management and spinal immobilization**

- As with all trauma patients, initial clinical evaluation of a patient with suspected spinal cord injury (SCI) begins with a primary survey.
- The primary survey focuses on life-threatening conditions. Assessment of airway, breathing, and circulation (ABCs) takes precedence.
- Perform manual immobilization rapidly (without traction), keeping the head and neck in the neutral position, by placing both hands around the neck and interlocking them behind, with the forearms preventing head movement
- Apply a hard collar. The collar should fit securely, but not occlude the airway or impair venous return from the head.
- Ensure airway patency and adequate ventilation
- Insert a urinary catheter to monitor urine output and prevent bladder distension.

