The bones of the upper limb(scapula & clavicle)

By
Muneer jawad MS.c RT

The scapula (Figs 7 1, 7 2)

This flat triangular bone has three processes:

- **The glenoid process**, which is separated from the remainder by the neck of the scapula The glenoid cavity forms part of the shoulder joint
- **The spine**, which arises from the posterior surface of the scapula and separates the supraspinous and infraspinous fossae The spine extends laterally over the shoulder joint as the acromion (see Fig 7 2)
- **The coracoid process**, which projects anteriorly from the upper border of the neck of the scapula.

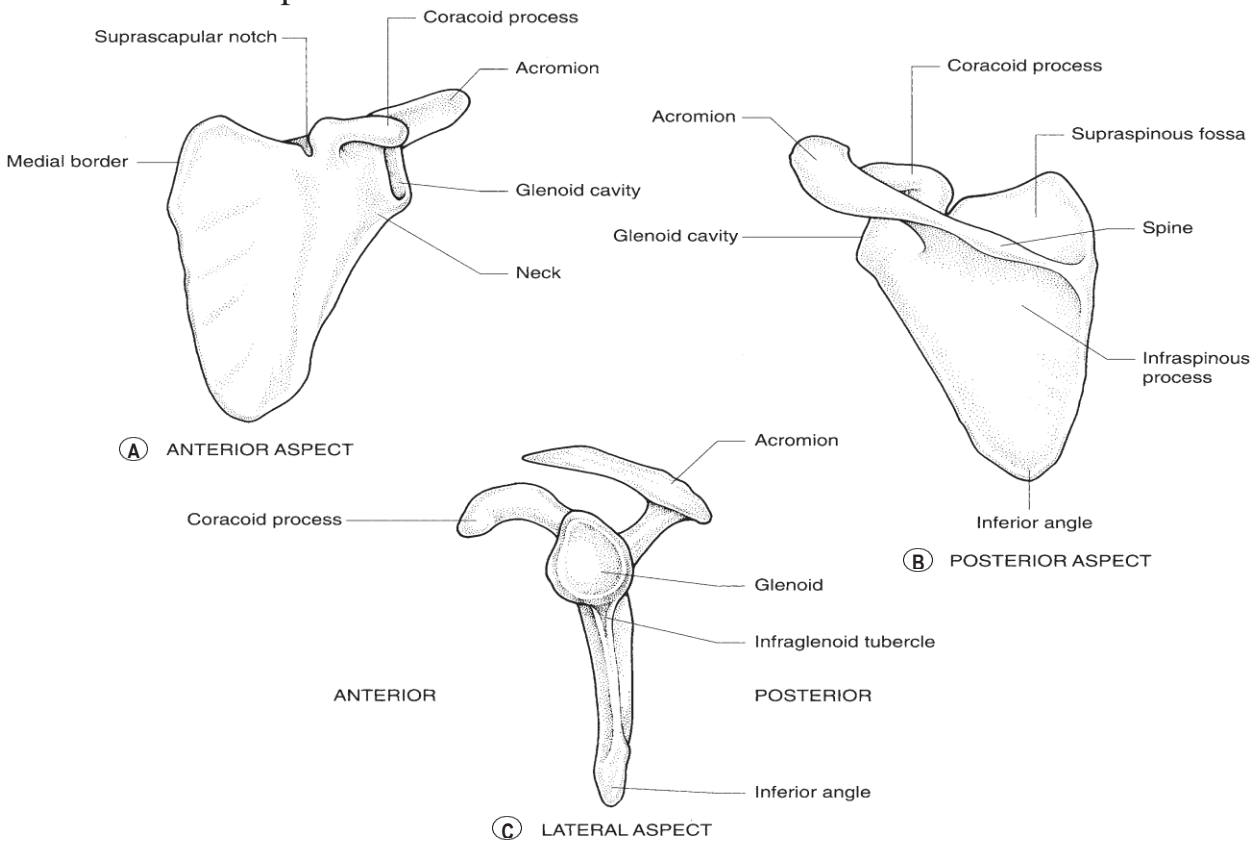

Figure 7.1 • The scapula: (A) anterior view; (B) posterior view; (C) lateral view

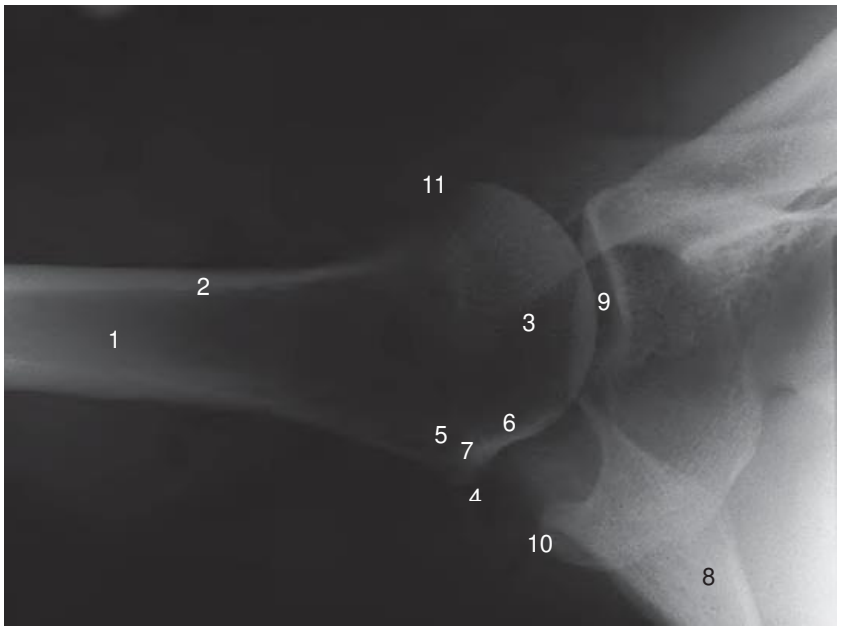

Figure 7.2 • Axial radiograph of the shoulder

1. Medullary cavity of humeral shaft
2. Cortex
3. Head of humerus
4. Lesser tuberosity
5. Tip of acromion process
6. Lateral end of clavicle
7. Acromioclavicular joint
8. Clavicle
9. Glenoid fossa of scapula
10. Coracoid process of scapula
11. Acromion process of scapula

Articulations

- acromion: clavicle (forming the acromioclavicular joint)
- glenoid cavity: humeral head (forming the glenohumeral joint)

Attachments

Musculotendinous

- supraspinous fossa: supraspinatus muscle
- infraspinous fossa: infraspinatus muscle, teres minor muscle
- subscapular fossa: subscapularis muscle, serratus anterior
- transverse scapular ligament and adjacent superior border of blade: inferior belly of omohyoid
- acromion: acromial part of deltoid muscle, trapezius
- scapular spine: spinous part of deltoid muscle, trapezius
- coracoid process: coracobrachialis, pectoralis minor, short head of biceps muscle
- lateral border (margo lateralis): teres minor muscle, teres major muscle
- vertebral border (posterior): levator scapulae, rhomboid minor muscle, rhomboid major muscle
- inferior angle: teres major muscle, a small slip of latissimus dorsi
- supraglenoid tubercle: long head of biceps muscle
- infraglenoid tubercle: long head of triceps muscle

Ligamentous

- transverse scapular ligament:
- coracoacromial ligament
- coracoclavicular ligament
- coracohumeral ligament
- glenohumeral ligaments: upper, middle, and lower bands
- acromioclavicular ligament (weak)

Radiological features of the scapula

Plain radiographs

The inferior angle of the scapula lies over the seventh rib or interspace – this is a useful guideline in identifying ribs or thoracic vertebral levels

The scapula lies over the ribs and obscures some of the lung fields in PA chest radiographs unless the shoulders are rotated forwards In AP views it is not usually possible to rotate the scapulae off the lung fields Similarly, in AP views of the scapula the beam is centred over the head of the humerus to project the thoracic cage away from the scapula In lateral chest radiographs, the lateral border of the scapula may be confused with an oblique fissure The inferior angle of the scapula may be slightly bulbous and simulate a mass on this view

Isotope bone scan:

The inferior angle of the scapula overlying the seventh rib may appear as a 'hot spot'.

Ossification

The scapula ossifies in the eighth week of fetal life An ossification centre appears in the middle of the coracoid process in the first year of life and fuses at 15 years of age Secondary centres appear in the root of the coracoid process, the medial border and the inferior angle of the scapula between 14 and 20 years, and fuse between 22 and 25 years of age

The clavicle (Fig 7 3; see also Fig 7 2)

The clavicle lies almost horizontally between the sternoclavicular and the

acromioclavicular joints It is also attached to the first costal cartilage by the cost clavicular ligament, which arises from the rhomboid fossa on its inferomedial surface It is connected to the coracoid process by the coracoclavicular ligament at the conoid tubercle and the trapezoid line on its inferolateral surface The subclavian vessels and the trunks of the brachial plexus pass behind its medial third.

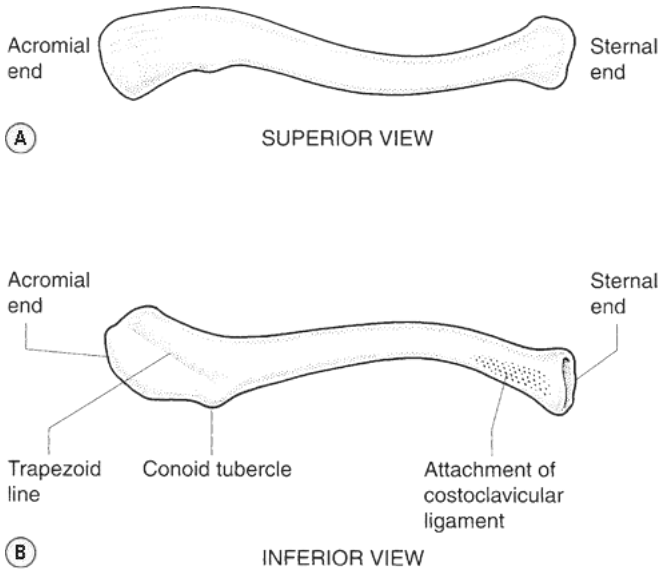

Figure 7.3 • The clavicle: (A) superior view; (B) inferior view

Radiological features of the clavicle

Chest radiograph

The clavicle overlies the apices of the lungs in chest radio- graphs Apical or lordotic views are used to project the clavicles above the lungs to evaluate this area further In portable AP chest radiography, if the patient is inclined backwards from a true vertical position the horizontal beam projects the clavicles above the lungs On a chest radiograph, the

distance between the medial end of the clavicle and the spine of the vertebrae is equal on both sides unless the patient is rotated

Ossification

The clavicle begins to ossify before any other bone in the body It ossifies in membrane from two Centre's that appear at the fifth and sixth fetal weeks, and fuses in the seventh week A secondary Centre appears at the sternal end at 15 years in females and 17 years in males, and fuses at 25 years of age .

Articulations

The clavicle articulates with the **acromion** at the acromioclavicular joint laterally and the **sternum** at the sternoclavicular joint medially**.**

Attachments

- **Muscles(5)**
  - pectoralis major, sternocleidomastoid (clavicular head), deltoid, trapezius, subclavius, sternohyoid
- **Ligamentous(5)**
  - acromioclavicular ligament, coracoclavicular ligament, sternoclavicular ligament, costoclavicular ligament, interclavicular ligament