Tumors of the uterus and ovaries

involve a range of conditions, some of which are benign (non-cancerous) and others malignant (cancerous). Here's a brief overview:

1. **Uterine Tumors**

   A. Benign Uterine Tumors:

   - Fibroids (Uterine Leiomyomas):
     These are the most common benign tumors of the uterus. They are made of muscle cells and other tissues that grow within the wall of the uterus. Fibroids can cause symptoms such as heavy menstrual bleeding, pelvic pain, and pressure on the bladder or rectum.
   - Endometrial Polyps:
     These are growths attached to the inner wall of the uterus that extend into the uterine cavity. They can cause irregular bleeding, spotting between periods, or heavy menstrual bleeding.

B. Endometrial Cancer:
Cancer of the lining of the uterus. Endometrial carcinoma is the most common type of uterine cancer, accounting for approximately 90% of all uterine malignancies. It arises from the inner lining of the uterus, called the endometrium. Endometrial carcinoma can be further classified into different histologic subtypes, including endometrioid, serous, clear cell, and mucinous carcinomas.

C. Uterine sarcomas: are rare malignant tumors that arise from the mesenchymal tissues of the uterus, such as the muscle or connective tissue. They account for approximately

3-7% of all uterine malignancies. Uterine sarcomas can be further classified into subtypes such as leiomyosarcoma, endometrial stromal sarcoma, and undifferentiated sarcoma.

- **Risk Factors:** Factors such as obesity, hormonal imbalances, and a history of estrogen therapy can increase the risk of endometria
  Symptoms may include abnormal vaginal bleeding, pelvic pain, or pain during intercourse.

2. Ovarian Tumors:

Ovarian Cysts: These are fluid-filled sacs that can develop in or on the ovaries. Most ovarian cysts are benign and go away on their own, but some may cause pain or complications.

Benign Ovarian Tumors: These include tumors such as dermoid cysts (containing hair, skin, or teeth) and cystadenomas (developing from ovarian tissue). They are usually non-cancerous.

Ovarian Cancer:

This can arise from various types of cells within the ovary.

- **Epithelial Tumors**: These tumors arise from the cells on the surface of the ovary. They are the most common form of ovarian cancer and primarily affect adults.
- **Germ Cell Tumors**: Derived from the egg-producing cells within the body of the ovary.
- **Stromal Tumors**: Originate from structural tissue cells that hold the ovary together and produce female hormones (estrogen and progesterone).

Clinical presentation:
of ovarian and uterine tumors can vary depending on the type and stage of the tumor. Common symptoms may include pelvic pain, abnormal vaginal bleeding, bloating, changes in bowel or bladder habits, and unexplained weight loss.

Imaging techniques

play a crucial role in the diagnosis and staging of ovarian and uterine tumors. Some commonly used imaging modalities include:

- Ultrasound: Transvaginal ultrasound is often the initial imaging modality used to evaluate ovarian and uterine tumors. It can help visualize the size, location, and characteristics of the tumors.
- Computed Tomography (CT) Scan: CT scans provide detailed cross-sectional images of the abdomen and pelvis, allowing for a more comprehensive evaluation of the extent of the tumor and its involvement with nearby structures.
- Magnetic Resonance Imaging (MRI): MRI is particularly useful in assessing the local extent of uterine tumors and evaluating the involvement of adjacent structures. It can also provide valuable information for surgical planning.
- Positron Emission Tomography (PET) Scan: PET scans are used to evaluate the metabolic activity of tumors and can help determine the presence of metastases or recurrent disease. **Treatment options**
  include surgery, radiation therapy, hormone therapy, and chemotherapy.

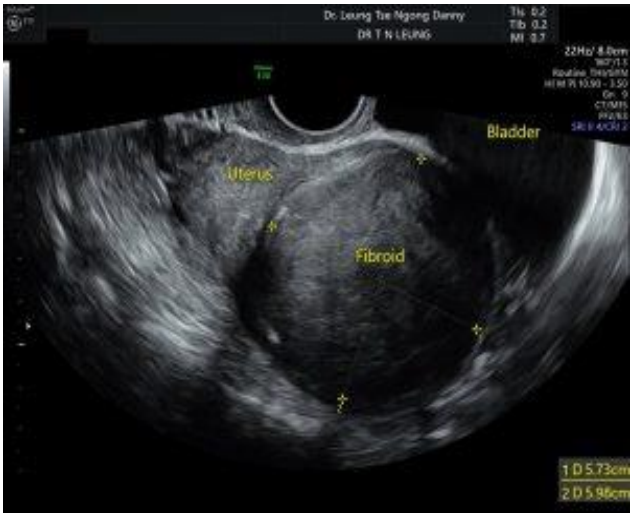

Fundal fibroid

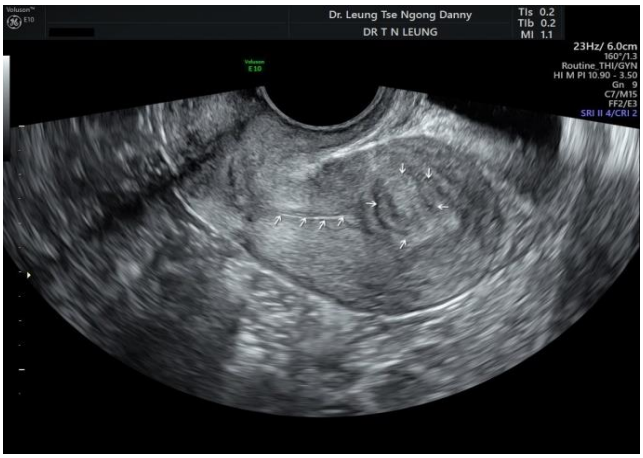

Submucosal fibroid

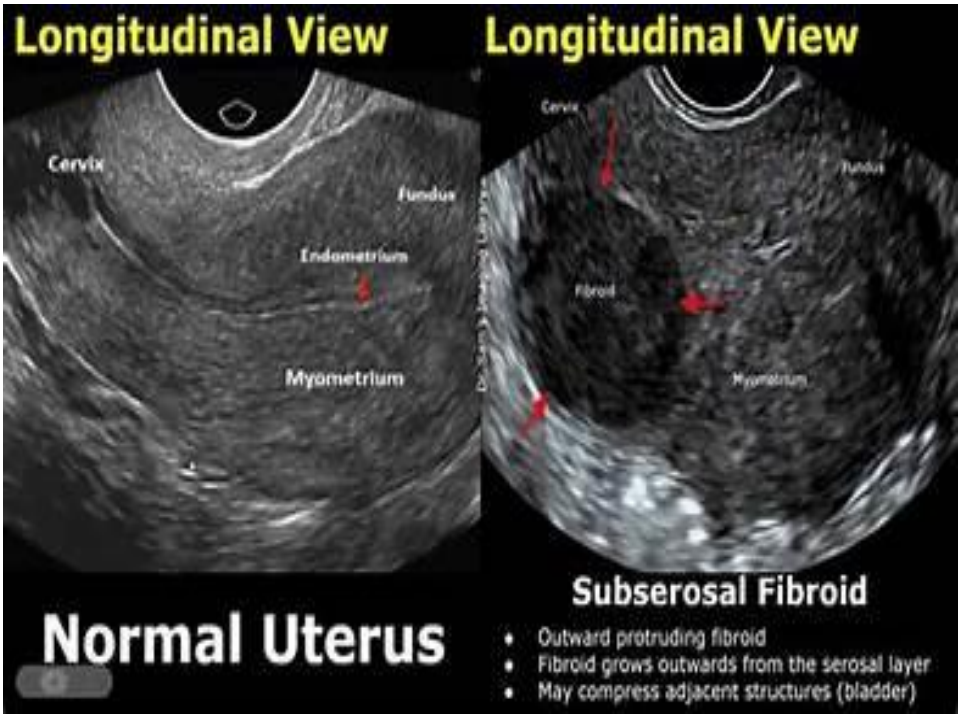

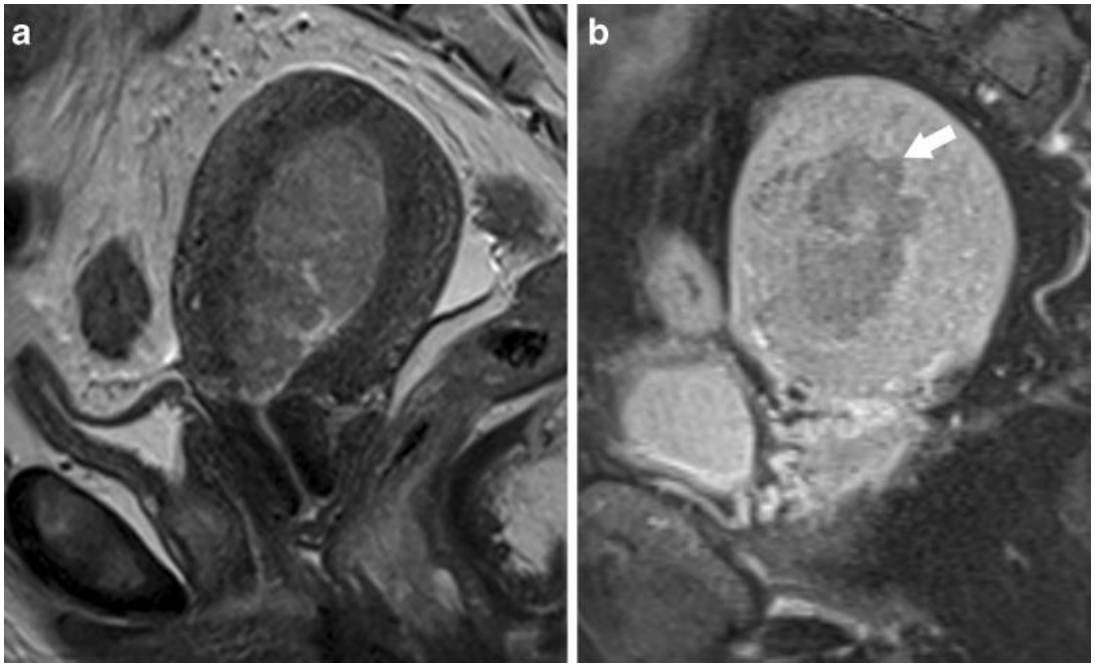

Endometrial cancer. a Sagittal T2-weighted and b para-sagittal post-contrast images. There is a large volume of tumour within the endometrial cavity. There is invasion of the myometrium, extending to <50% of the myometrial thickness (arrow). The post-contrast image demonstrates the typical bright enhancement of the myometrium with intermediate enhancement of the tumour .

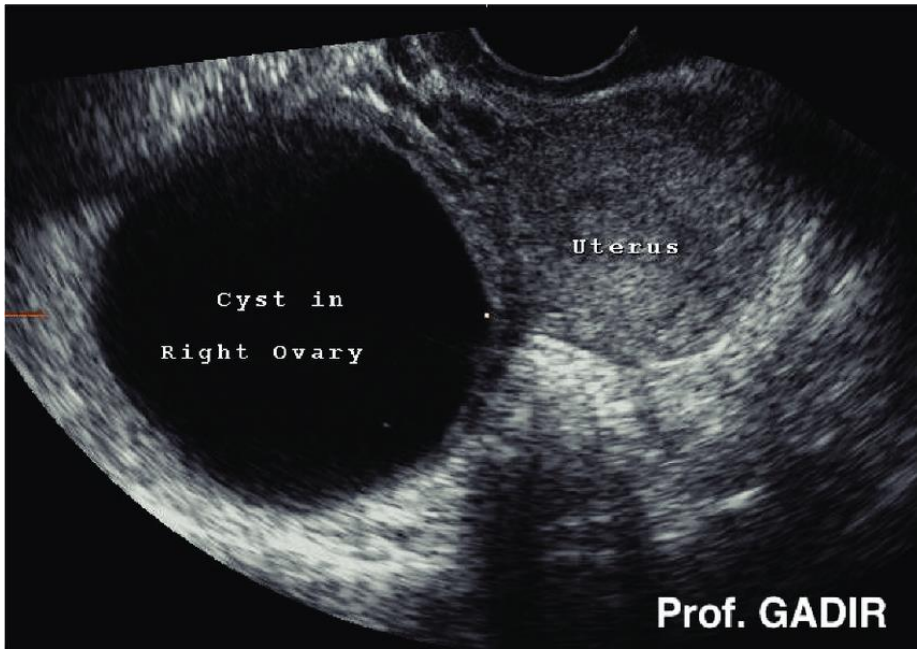

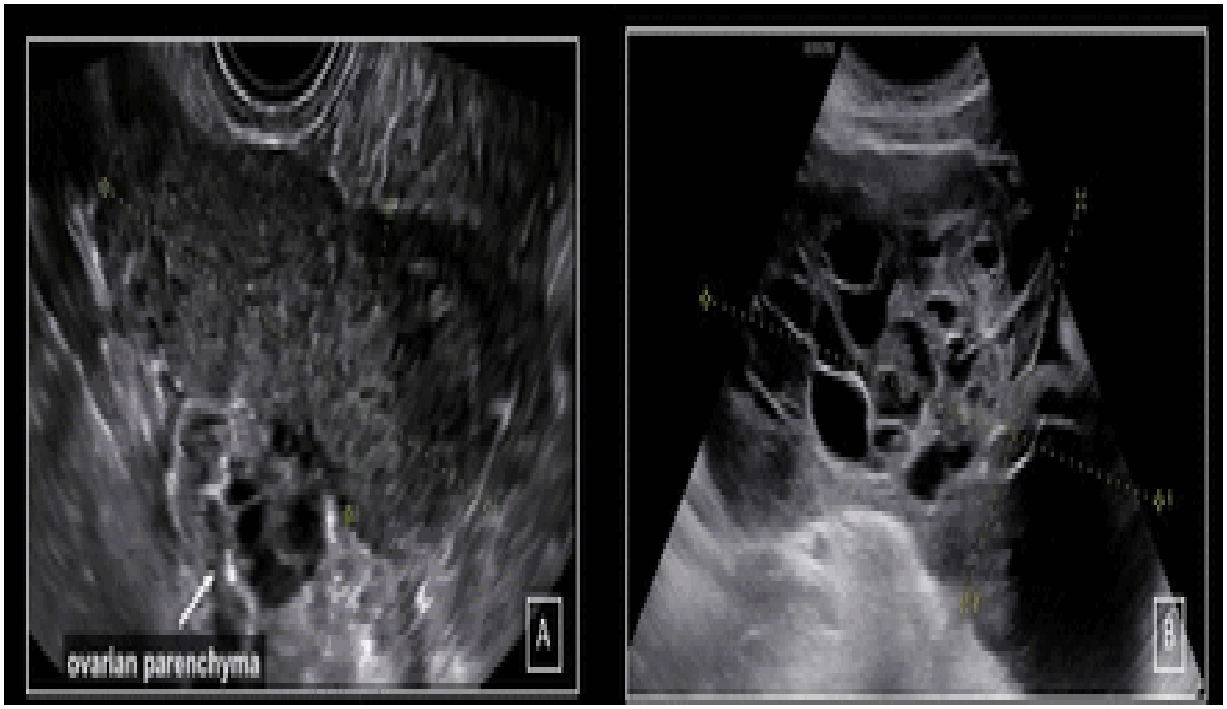

(A) An oblong solid mass, with inhomogeneous echostructure and irregular external walls, without stripes. (B) Multilocular solid mass, with several irregular locules, anechoic cystic content, and a solid component.

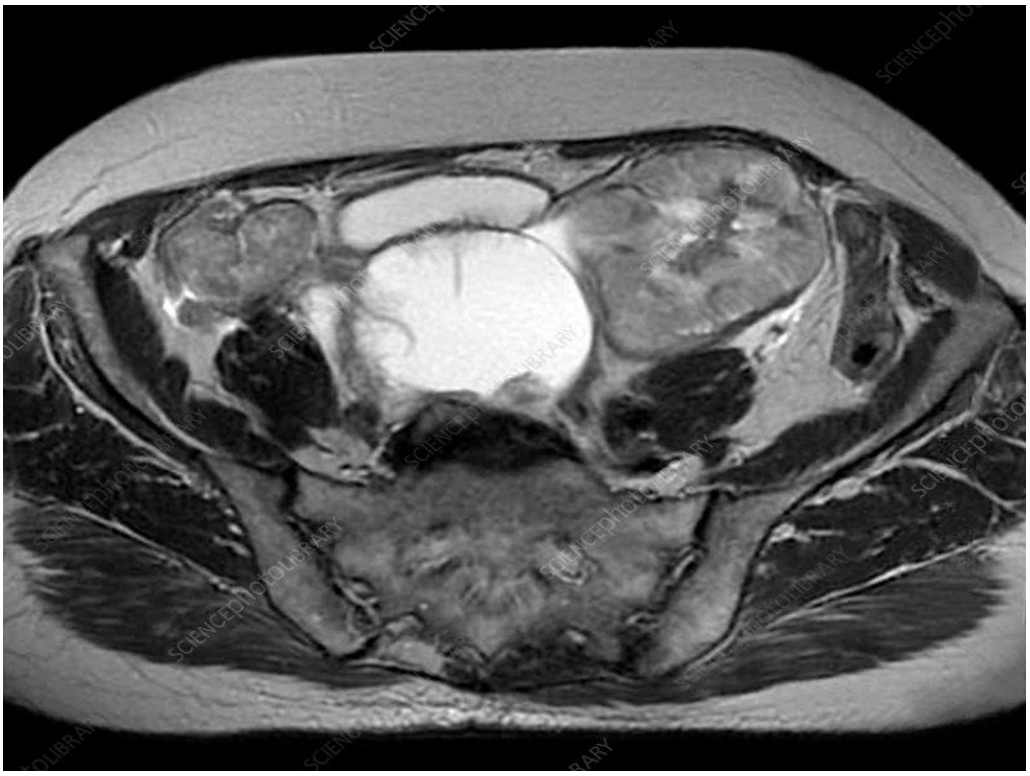

Bilateral ovarian cancer. Magnetic resonance imaging (MRI) scan of an axial section through a woman's abdomen, showing ovarian cancer in both ovaries. The tumours appear pale grey, either side of the bladder (white)