

LIVER SCAN

Hayder Jasim Taher

PhD of Medical Imaging



Outline of my presentation

- ✓ Indications.
- ✓ Preparation.
- ✓ Scanning technique.

Indications



1. Enlarged liver/hepatomegaly.
2. Suspected liver abscess.
3. Jaundice .
4. Abdominal trauma.
5. Ascites.
6 . Suspected metastases in liver.
7 . Suspected liver mass.
8. Right upper abdominal pain.
9. Screening for endemic echinococcosis.

Preparation



1. **Preparation of the patient.**
   - The patient should take nothing by mouth for 8 hours preceding the examination.
   - If fluid is essential to prevent dehydration, only water should be given.
   - If the symptoms are acute, proceed with the examination.
   - Infantsclinical condition permitting-should be given nothing by mouth for 3 hours preceding the examination.
2. **Position of the patient.**
   - The patient lies supine.
   - Apply coupling agent liberally, first over the right upper abdomen, then over the rest ofthe abdomen as the examination proceeds.

Preparation



3. **Choice of transducer.**

   - For adults use a 3.5 MHz transducer.
   - For children or thin adults use a 5 MHz transducer.

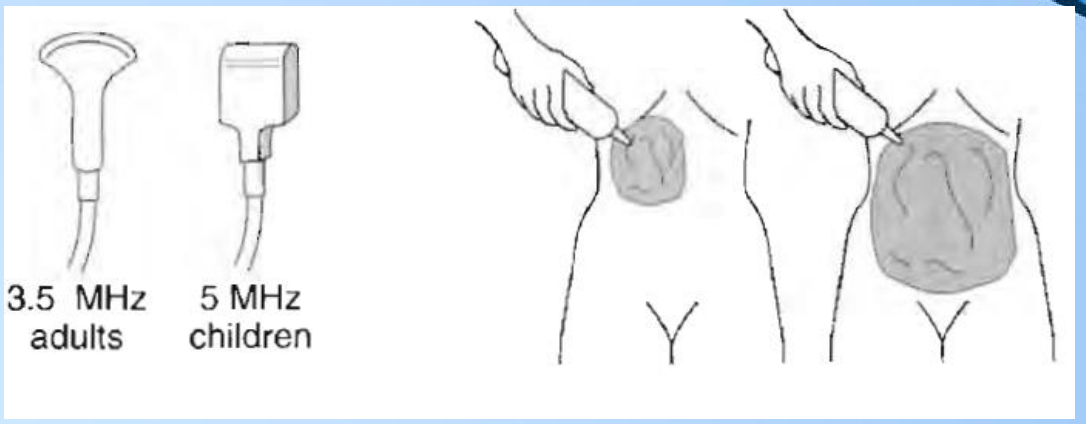

4. **Setting the correct gain.**

   - The gain setting should allow the diaphragm to be clearly seen; the liver (when normal) should appear homogeneous throughout its depth.
   - It should be possible to see clearly the normal tubular structures (the portal veins with bright edges and the hepatic veins without bright edges).
   - Hepatic arteries and bile ducts are not seen unless dilated.
   - Before scanning a specific area, ask the patient to take a deep breath and hold it in.

Preparation



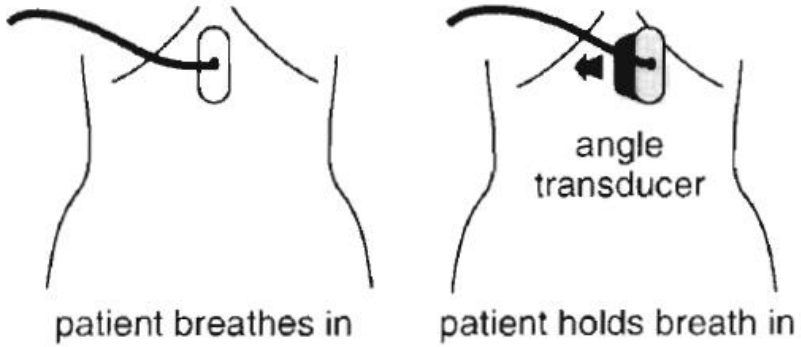

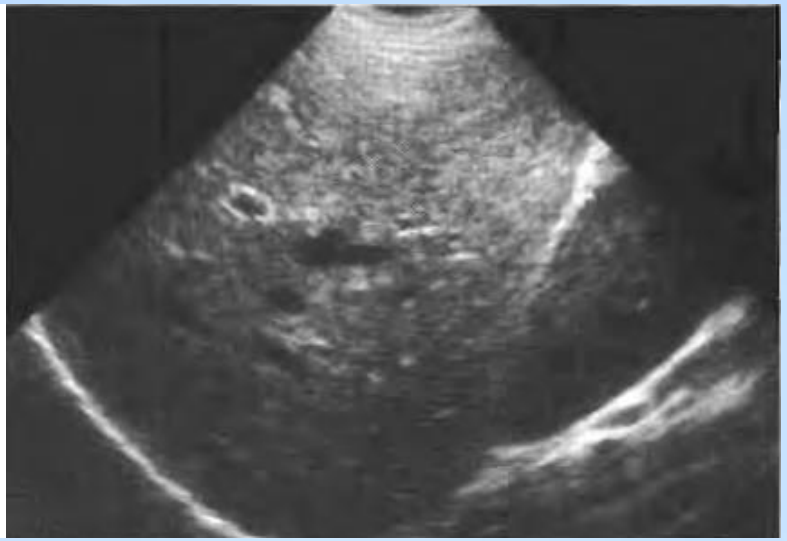



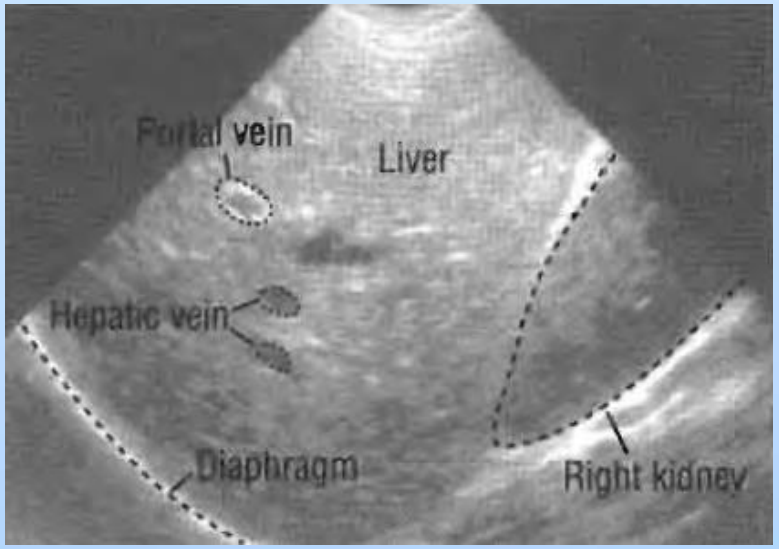

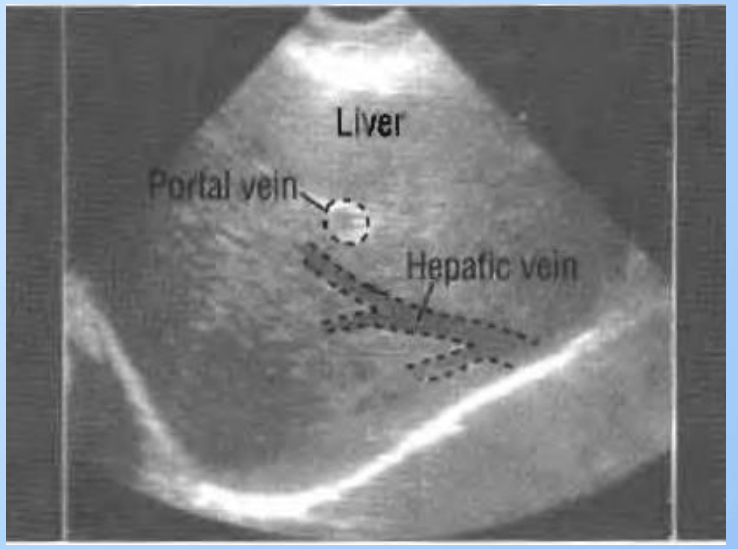

Scanning technique



- Scanning should be in sagittal, transverse and oblique planes, including scans through the intercostal and subcostal spaces.
- Scanning should be done with a slow rocking movement of the transducer in all planes to obtain the best visualization of the whole liver.

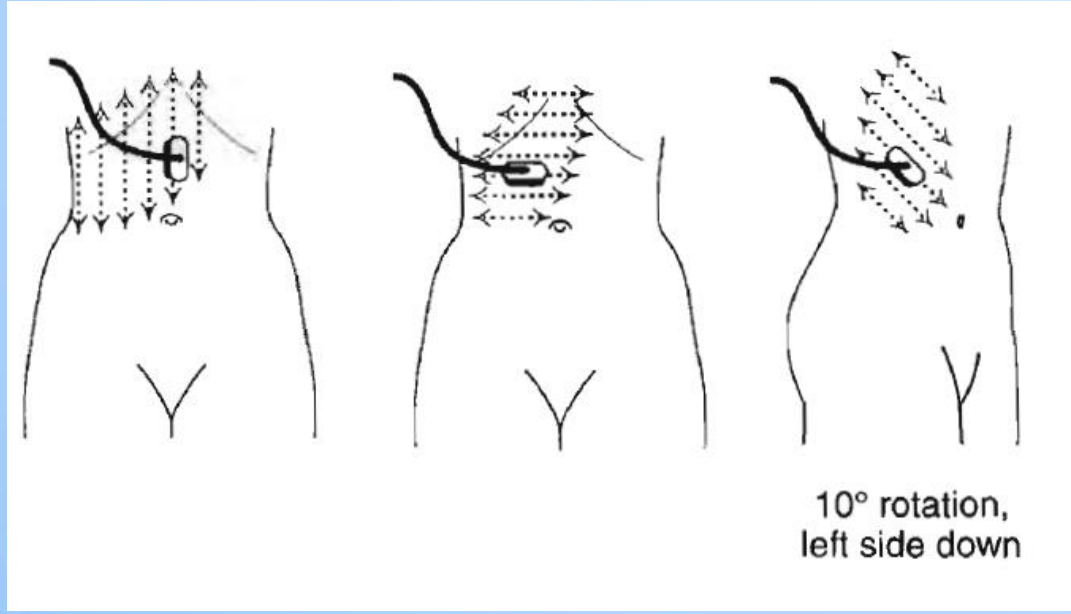

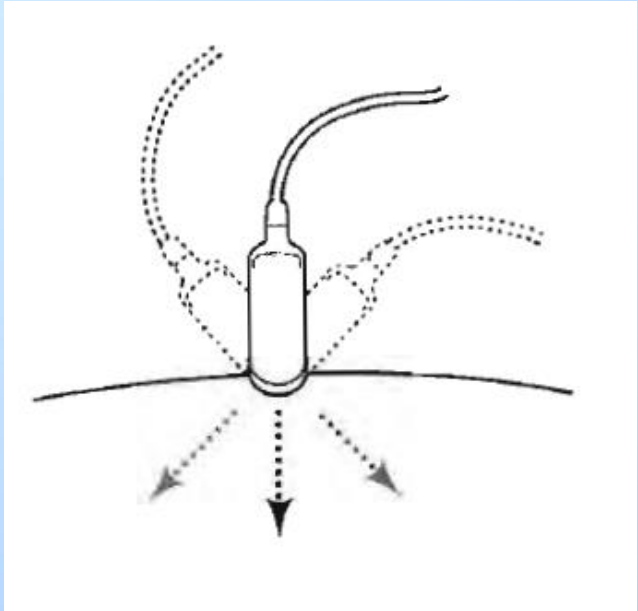

Scanning technique



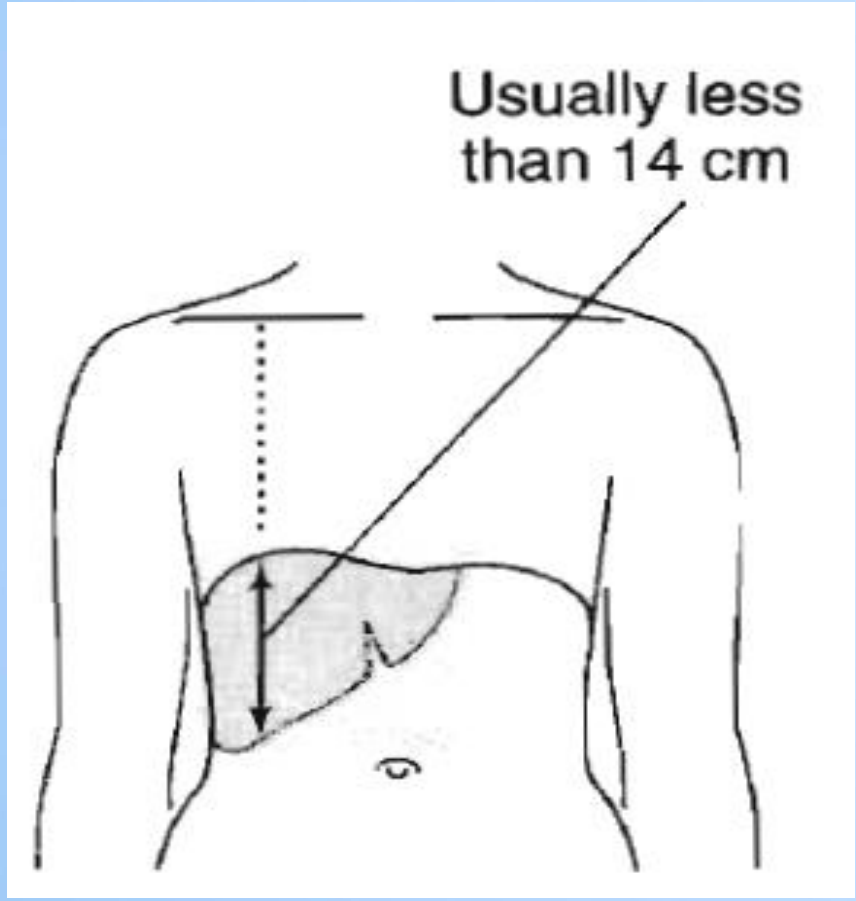

It is difficult to measure accurately the overall size of the liver. In the mid-clavicular line, the longitudinal measurement from the diaphragm to the lower edge of the liver is usually less than 14 cm in an adult, but there is considerable variation.

Normal liver



- The normal liver parenchyma appears homogeneous, interrupted by the portal vein and its branches which are seen as linear tubular structures with reflective walls.
- The thinner hepatic veins are non-reflective. In a normal liver, it should be possible to follow the hepatic veins to their confluence with the inferior vena cava.
- Hepatic veins can be made to dilate when the patient performs the Valsalva manoeuvre (forced
- expiration against a closed mouth and nose) .
- The vena cava may be seen in the liver and may vary with respiration. The aorta may be identified as a pulsatile tubular structure behind and medial to the liver

Normal liver

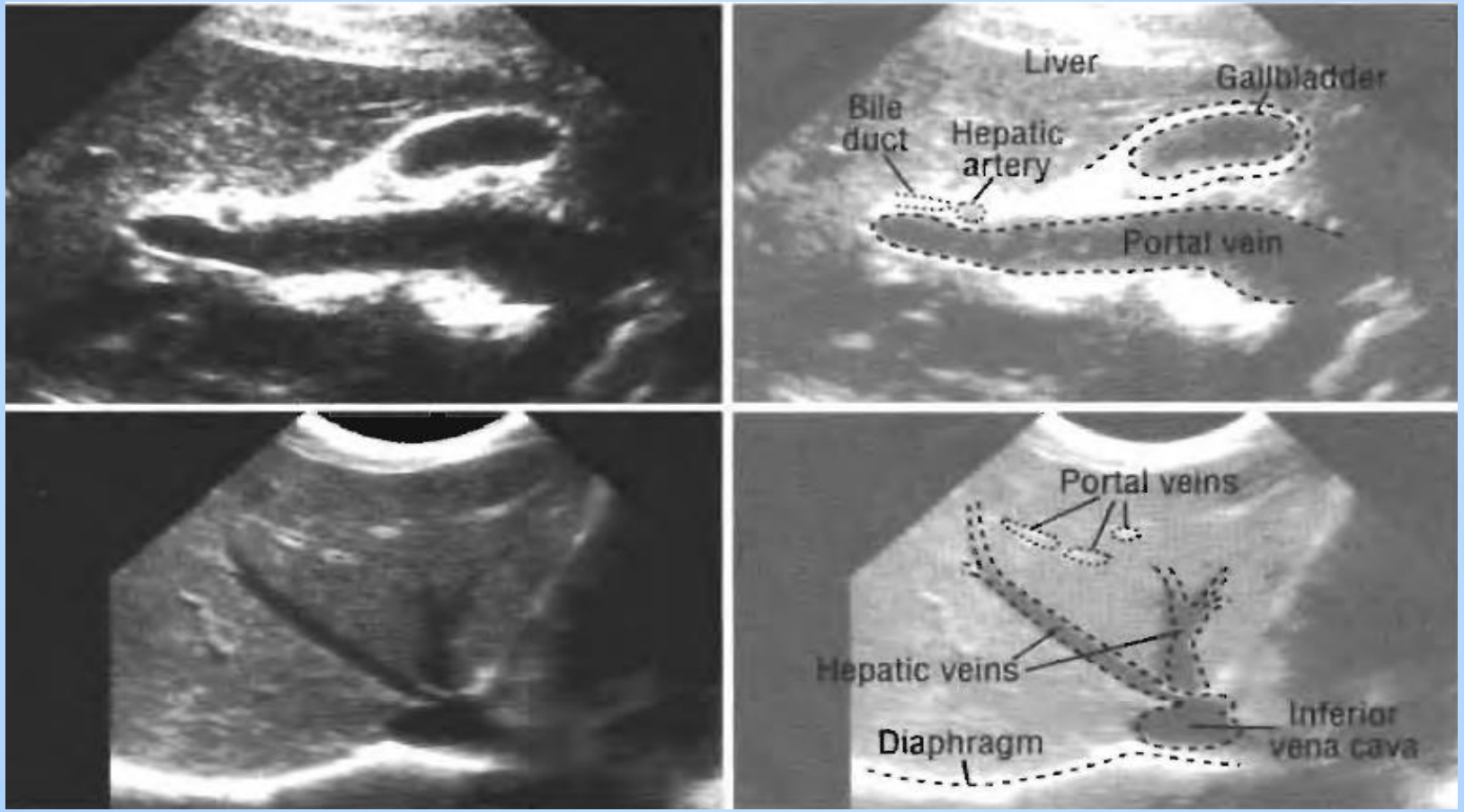

Oblique (upper) and transverse (lower) scans of the liver showing the portal and hepatic veins and the inferior *vena cava*

Normal liver



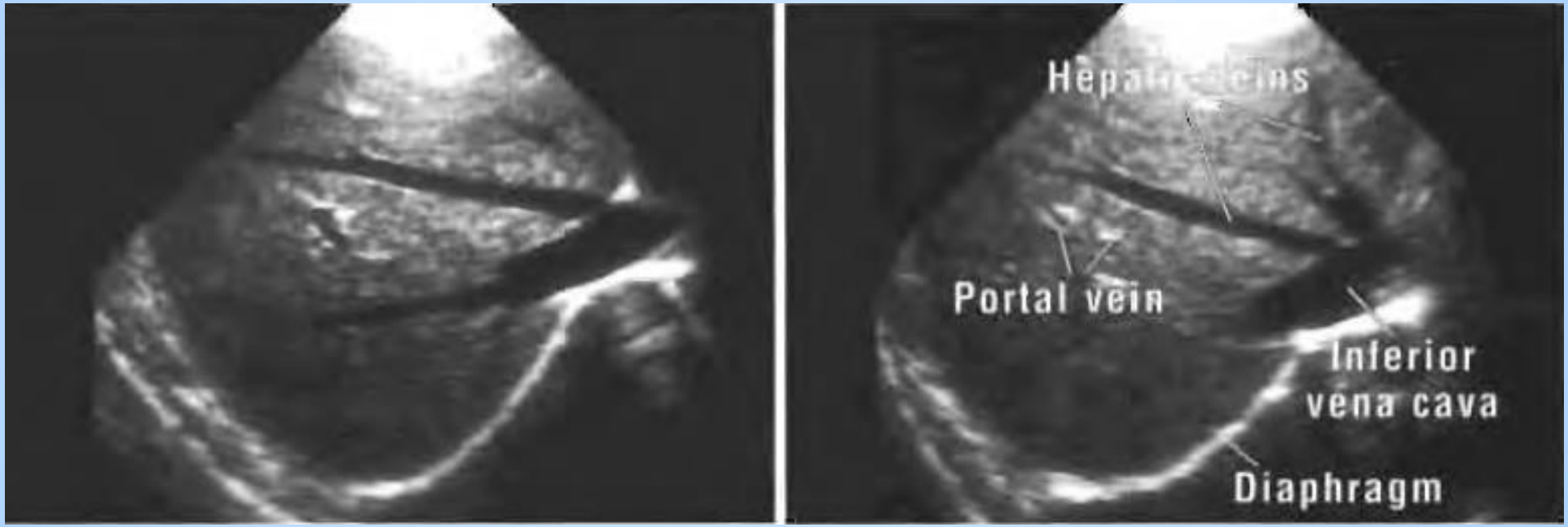

Two transverse scans at slightly different angles showing the inferior vena cava, the hepatic veins and the bright (echogenic) walls of the portal veins

Normal liver



The falciform ligament will be seen as a hyperechogenic structure just to the right of the midline in the transverse plane

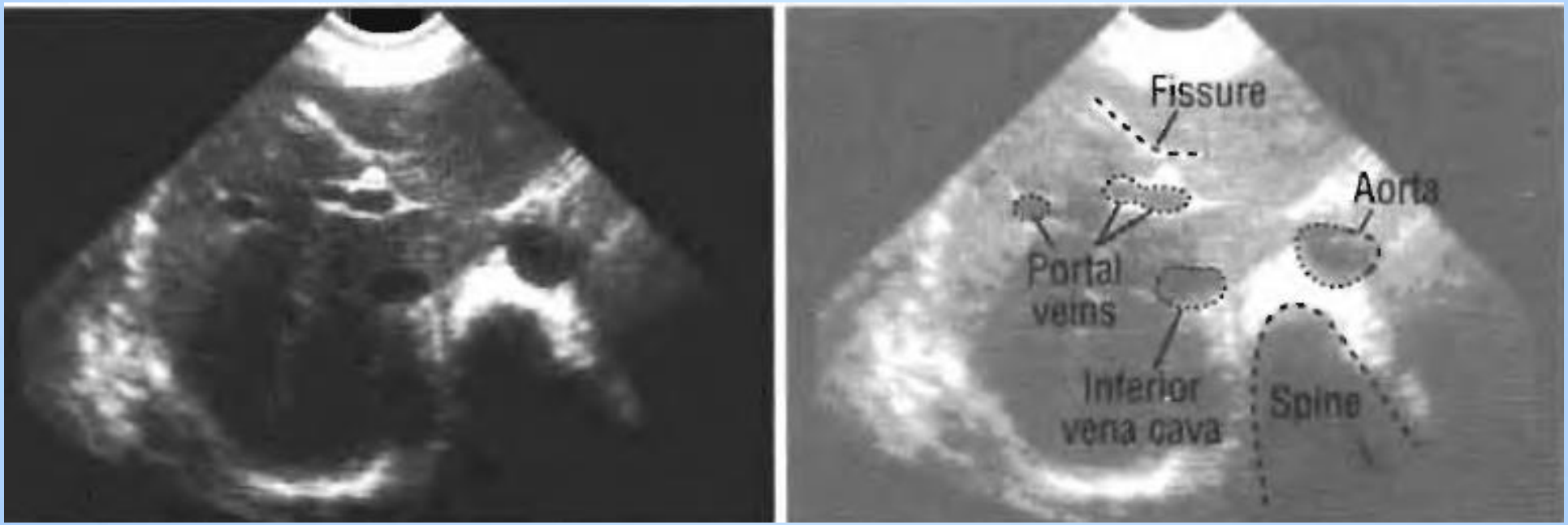

Transverse scan: the fissure of the ligamentum teres and the falCiform ligament.

Normal liver



As well as the light and left lobes of the liver. it is also important to recognize the caudate lobe. limited posteriorly by the infelior vena cava and separated antero-sup riorly from lhe left lobe of the liver by a highly reflective line. It is limited inferiorly by the proximal left portal vein. The caudale lobe must be identified because it may be mistaken for a mass

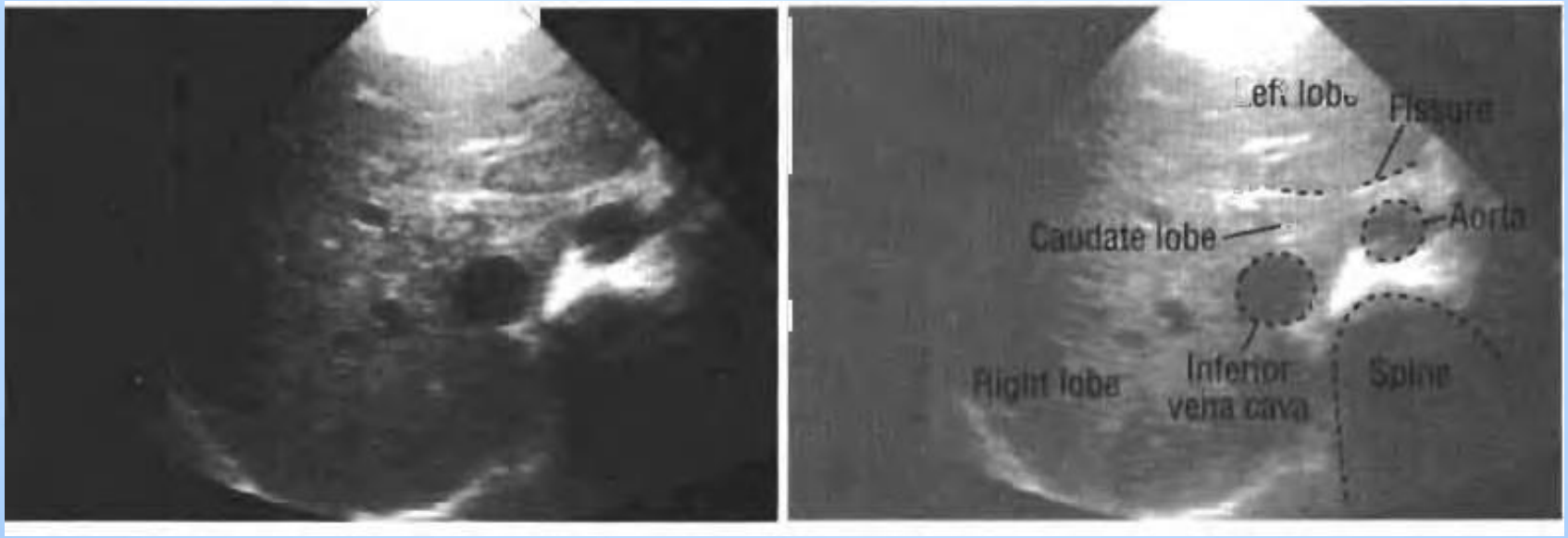

Transverse scan: the caudate lobe of the liver and the fissure of the ligamentum venosum

Normal liver



The gallbladder and the right kidney must also be identified. The gallbladder will appear on a longitudinal scan as an echo-free. Pear shaped structure

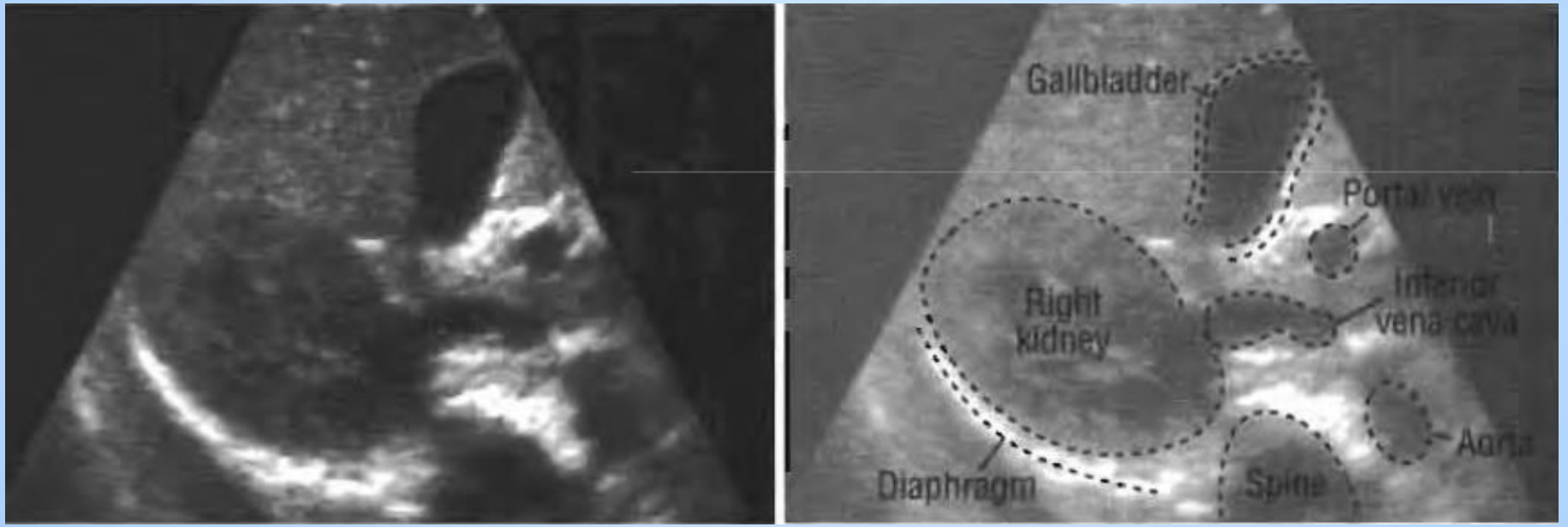

Transverse scan: the normal gallbladder

Normal liver



- The pancreas and vertebral column should be identified.
- The echogenicity of the normal liver parenchyma lies midway between
- that of the pancreas (more echogenic) and the spleen (less echogenic)

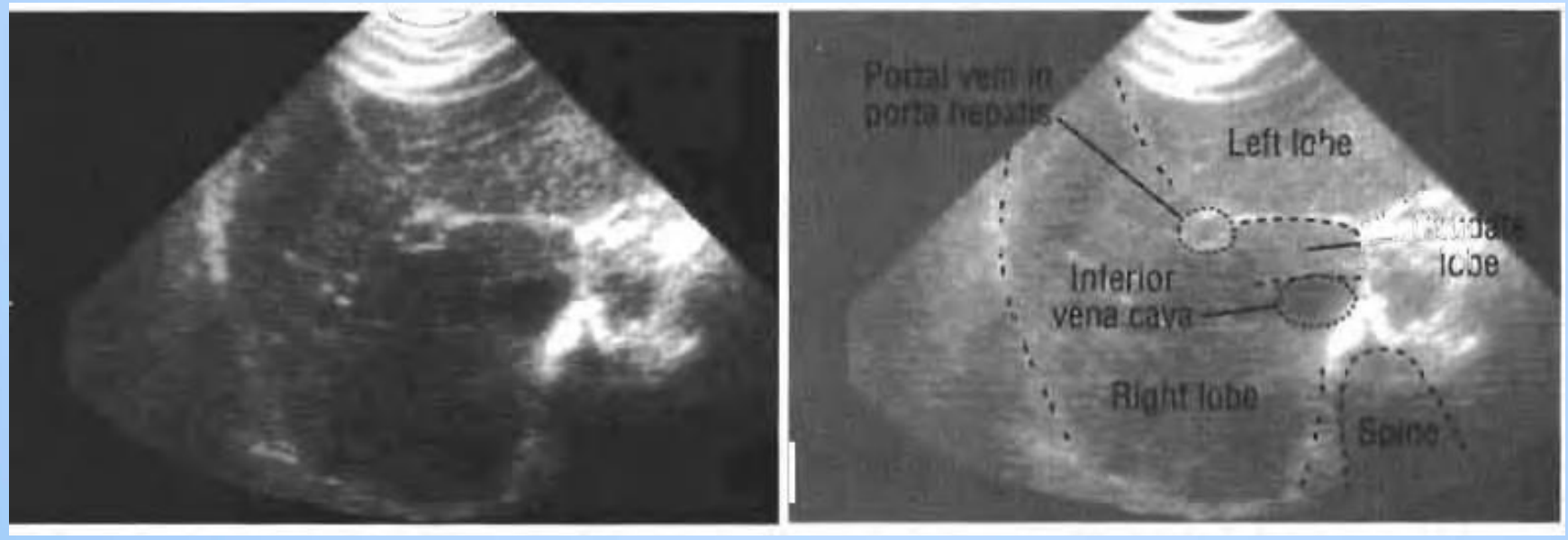

Thank you