

Renal cysts and renal masses

Hayder Jasim Taher

PhD of Medical Imaging



Outline of my presentation

- ✓ Introduction
- ✓ Renal cysts.
- ✓ Renal masses.
- ✓ Small kidney.

Introduction



Focal renal masses are commonly identified on imaging studies. Although the most commonly encountered etiology is a benign cyst, a significant subset of renal masses may represent malignant or inflammatory etiologies. Because of the possibility of more sinister etiologies, each renal lesion encountered on imaging needs to be characterized regarding its malignant potential. Ultrasound is a widely available, radiation-free, and relatively inexpensive modality that plays an important role in characterizing focal renal masses. It is used to differentiate benign cysts from solid renal neoplasms, characterize the degree of complexity of renal cysts, and identify features to help differentiate the etiologies of various lesions. In addition, the increasingly widespread availability of contrast-enhanced ultrasound (CEUS) has now provided us the ability to study the enhancement characteristics of renal lesions.

Introduction



When assessing a renal lesion, the first question that a radiologist needs to address is whether it is solid or cystic. The underlying reason for this bifurcation point is that most solid lesions are malignant and treated accordingly. On the other hand, all simple cysts and even most complex cysts are benign. As simple cysts far outnumber all other focal renal lesions, confident characterization of a lesion as a simple cyst can stop any further need for workup in most lesions. The ability to differentiate cysts from solid renal lesions is one of the most important strengths of ultrasound. On ultrasound, renal cysts present as spherical or ovoid anechoic lesions with thin, smooth, or imperceptible walls and posterior acoustic enhancement. The ultrasound waves traverse the fluid within the cyst exceptionally well, resulting in the anechoic appearance of the cyst. Solid lesions, such as lymphoma and renal cell carcinoma (RCC), are sometimes quite hypoechoic but not completely anechoic. Posterior acoustic enhancement is another feature of cysts (and other fluid-filled structures).

After traversing the cyst, the relatively unattenuated sound beam results in increased brightness just posterior to the cyst.

Renal cysts



When ultrasound shows multiple, echo free, well circumscribed areas throughout the kidney, suspect multicystic kidney. This condition is usually unilateral, whereas congenital polycystic kidney disease is almost always bilateral (although the cysts may not be symmetrical).

1. **Simple cysts** can be single or multiple. On ultrasound the walls are smooth and rounded without internal echoes (Fig 11), but with a clearly defined back wall. Such cysts are usually unilocular and, when multiple, will differ in size. Rarely, these cysts be come infected or haemorrhage, producing internal echoes. When this occurs or when the outline of any cyst is irregular, further investigation is required.

Renal cysts



	Internal echoes	Back wall	Contour	Shape
Cyst	No	Strong	Well defined	Spherical
Tumour	Yes	No change or strong	Irregular	Variable Ill defined

Renal cysts



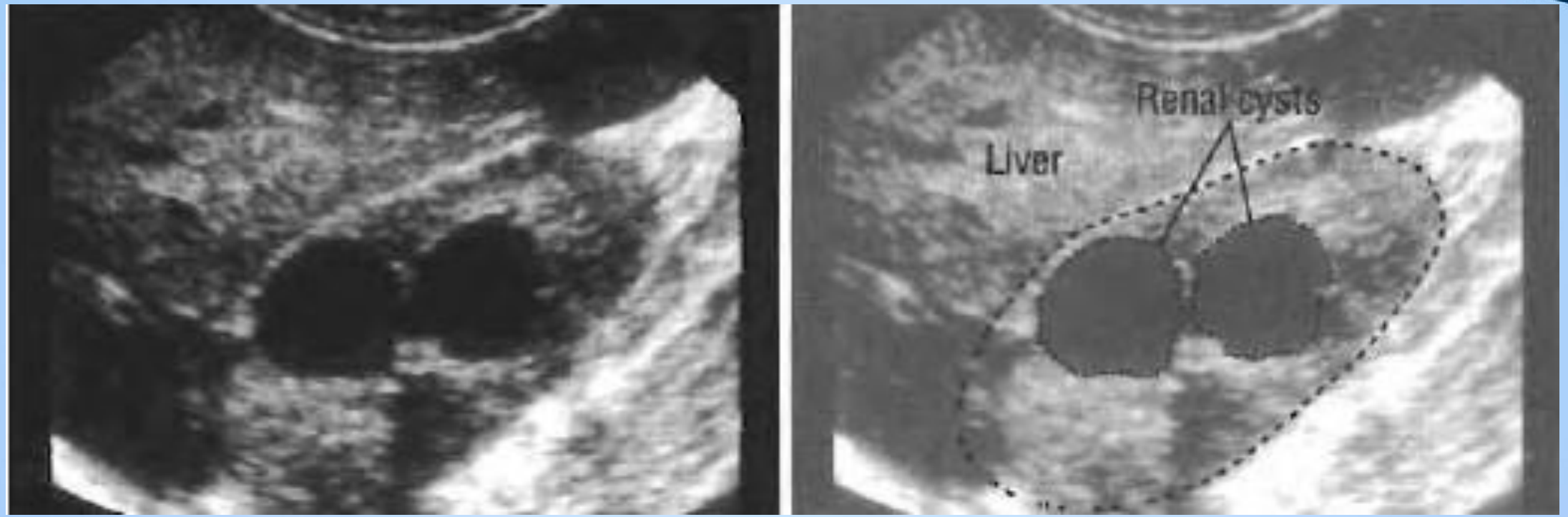

More than 70% of all renal cysts are due to benign cystic disease. These cysts are very common over the age of 50 years and may be bilateral. They seldom cause symptoms.

Renal cysts



2. Hydatid cysts usually contain debris and are often loculated or septate. When calcified, the wall appears as a bright, echogenic convex line with acoustic shadowing. Hydatid cysts may be multiple or bilateral. Scan the liver for other cysts and X-ray the chest

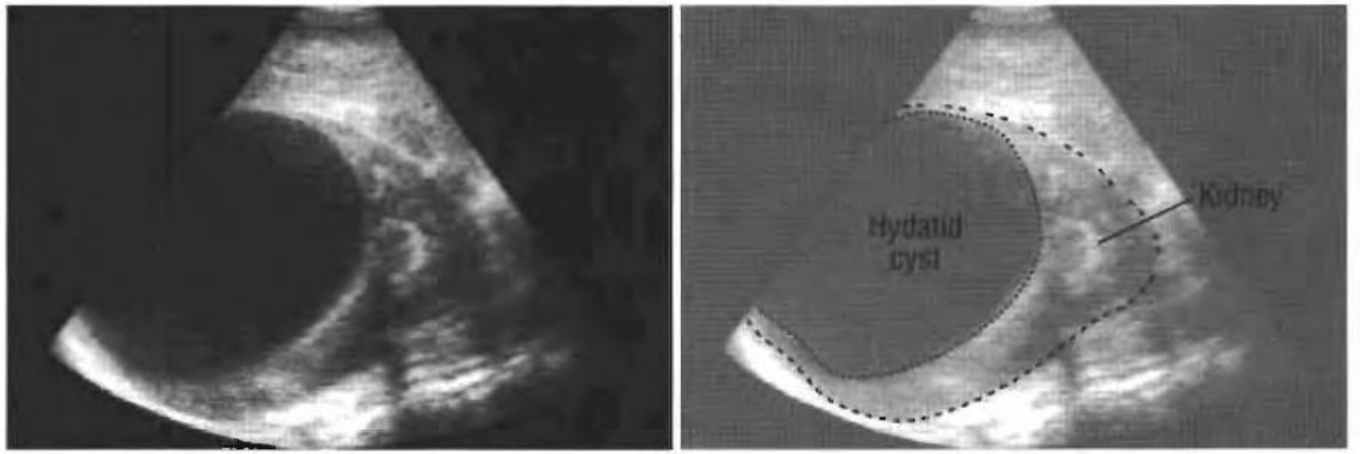

Fig. 107a. Longitudinal scan: a hydatid cyst in a right kidney.

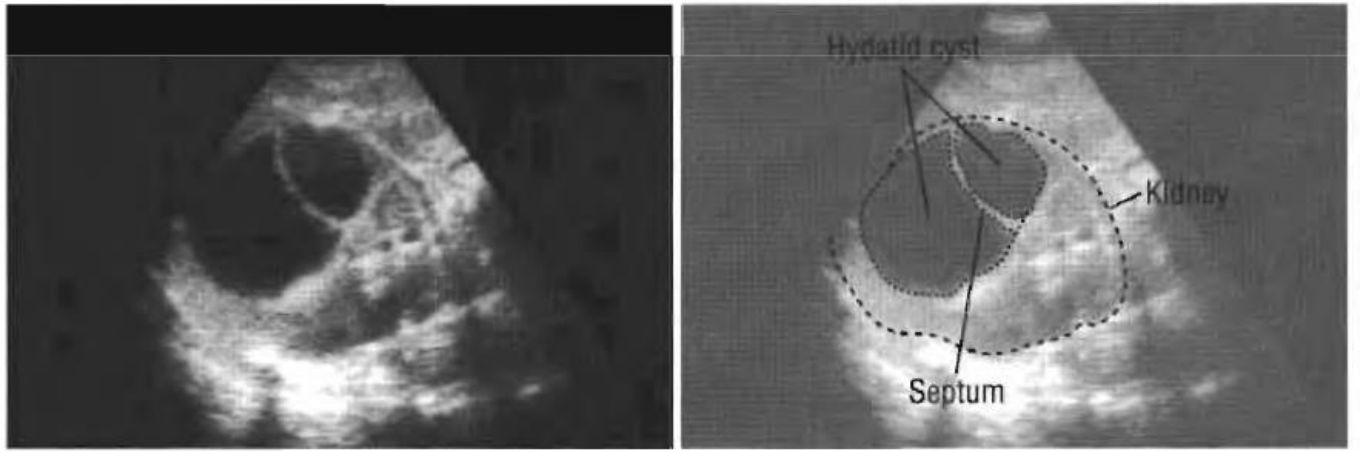

Fig. 107b. Transverse scan: a septate hydatid cyst in a right kidney.

Renal cysts



3. If there are multiple cysts in one kidney, the kidney is usually enlarged. This may indicate alveolar echinococcosis. If the patient is less than 50 years old and clinically well. check the other kidney to exclude polycystic disease: congeniial cysts are echo-free and without mural calcification. Both kidneys are always enlarged

Renal masses



Ultrasound cannot reliably differentiate between benign renal tumours (other than renal cysts) and malignant renal tumours, and cannot always accurately differentiate malignant tumours from renal abscesses.

Renal masses



There are two exceptions to the above statement:

1. In the early stages, a renal angiomyolipoma (Fig. 1 08a) has ultrasound characteristics that allow accurate recognition. These tumours can occur at any age and may be bilateral. Ultrasound images show a well Circumscribed, hyperechogenic and homogeneous mass, and as the tumour grows there will be back wall attenuation. However, some tumours will undergo central necrosis and there will be strong back wall echoes. At this stage differentiation by ultrasound is no longer possible, but abdominal X-rays may show fat within the tumour, which is unlikely to occur in any other type of renal mass.
2. When a renal tumour spreads into the inferior vena cava or into the perirenal tissues, there is no doubt that the tumour is malignant (Fig. 108b).

Renal masses



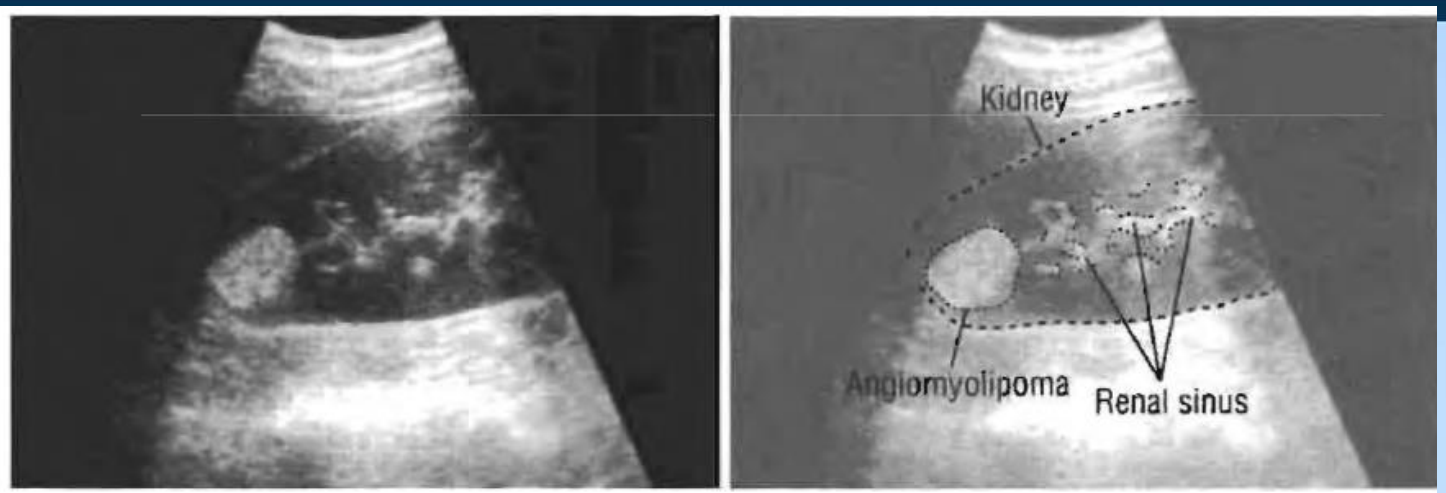

Fig. 108a. Supine longitudinal scan: an angiomyolipoma in a right kidney.

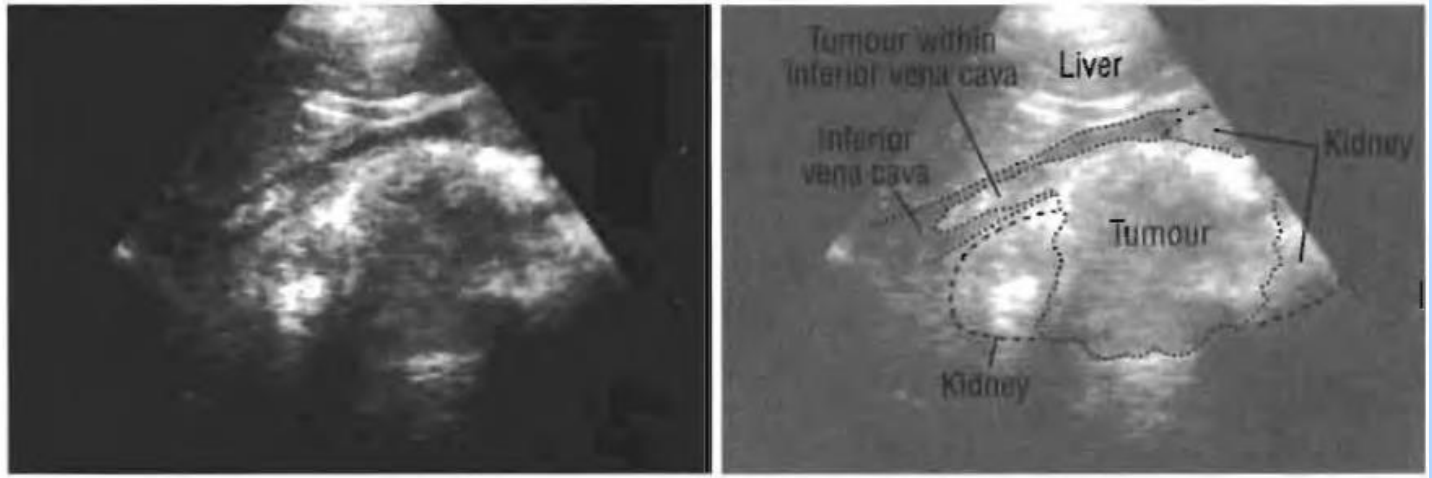

Fig. 108b. Longitudinal scan: a large renal tumour involving the inferior vena cava and spreading beyond the renal capsule.

Solid renal mass



Renal masses may be well circumscribed or irregular and may alter the shape of the kidney. Echogenicity may be increased or decreased. In the early stages, the majority of malignant tumours are homogeneous: if central necrosisoccurs, they become nonhomogeneous.

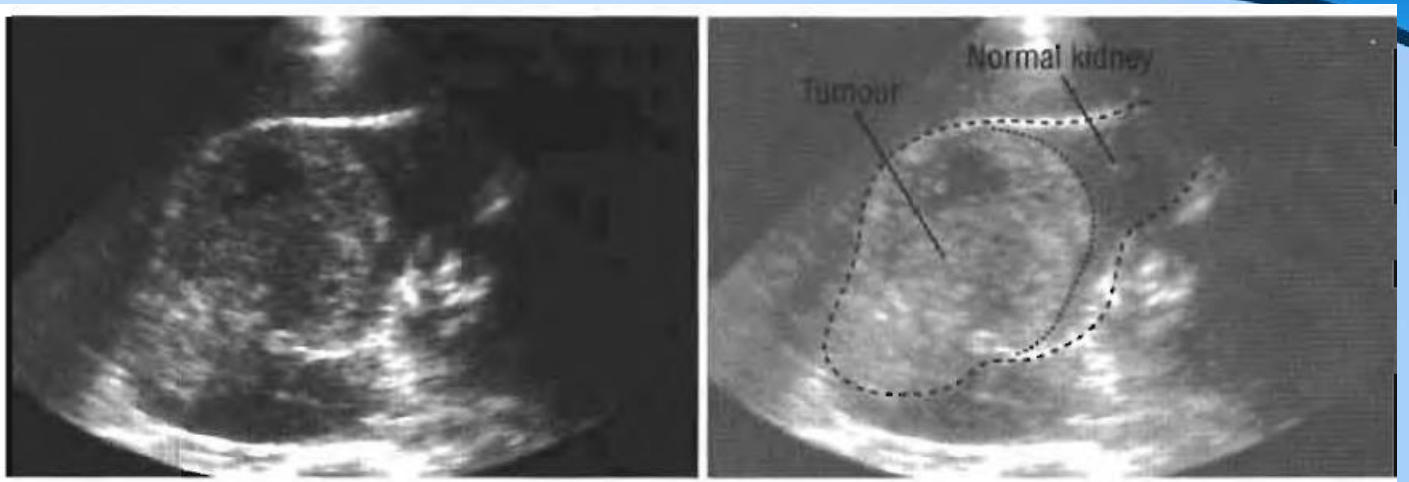

Fig. 109a. Oblique longitudinal scan: a well-circumscribed tumour in a right kidney.

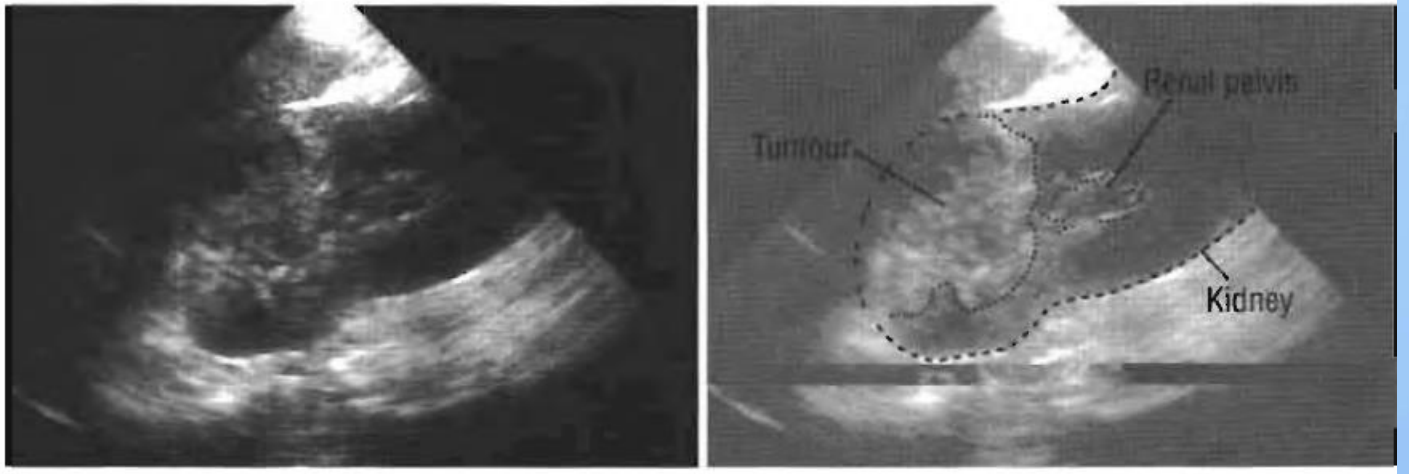

Fig. 109b. Oblique longitudinal scan: an irregular, ill-defined tumour in a right kidney.

A complex nonhomogeneous mass



The differential diagnosis of complex masses can be very difficult, but when there is spread of a tumour beyond the kidney, there is no doubt that it is malignant.
Malignant tumours may also be contained within the kidney. Both tumours and haematomas may show acoustic shadowing due to calcification.
As a tumour grows, its centre may become necrotic with a rough irregular outline and much internal debris, causing a complex ultrasound pattern. The differentiation of this from an abscess or a haematoma can be difficult. The clinical condition of the patient may indicate the correct diagnosis. Tumours can spread into the renal vein or inferior vena cava and resemble thrombosis.
A rough, irregular, echogenic mass containing debris within an enlarged kidney may be malignant or a pyogenic or tuberculous abscess. The patient's clinical condition may help to differentiate

A complex nonhomogeneous mass

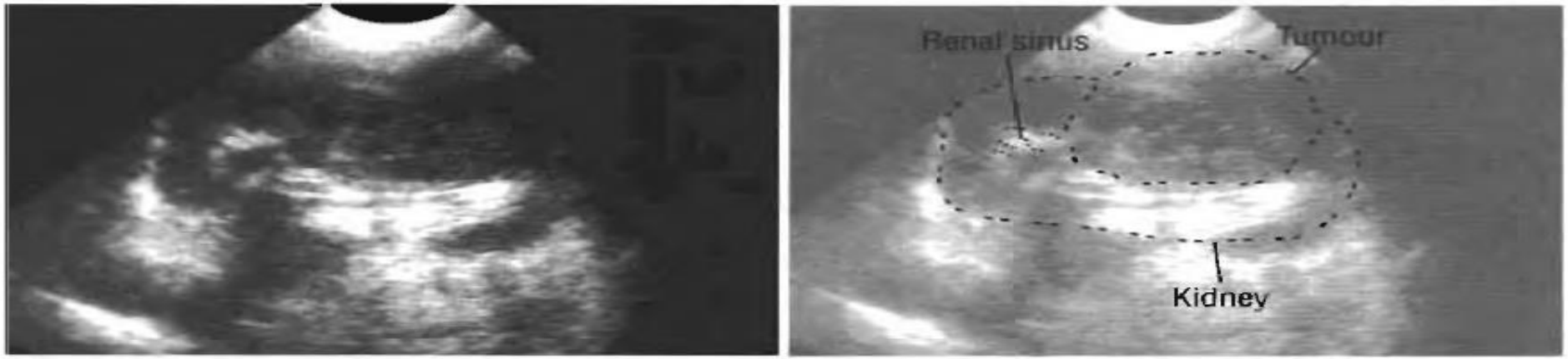

Fig. 111a. Longitudinal scan: a tumour in a left kidney, which is invading the renal tissue and beyond it (renal carcinoma).

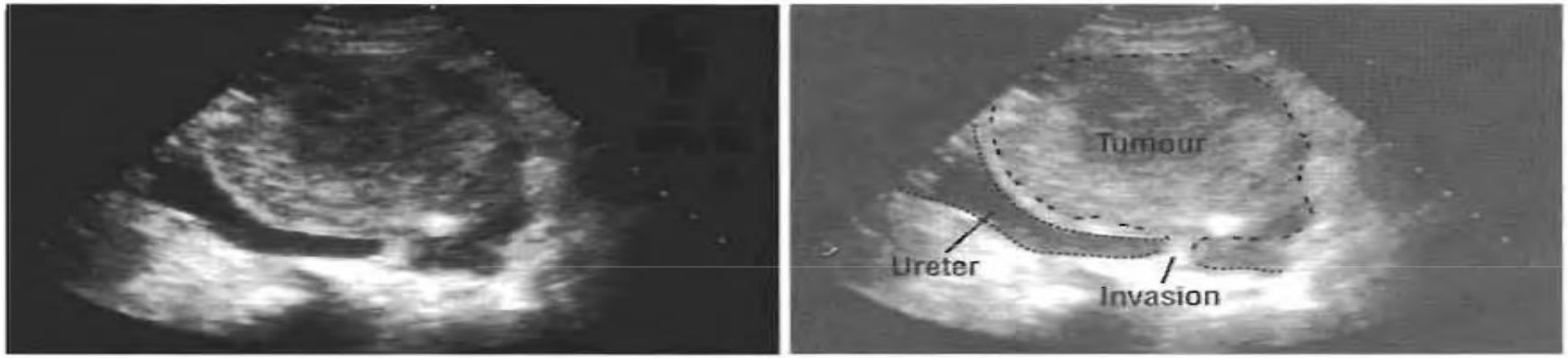

Fig. 111b. Transverse scan: a tumour in the lower pole of a left kidney, invading the left ureter and causing obstructive hydronephrosis.

A complex nonhomogeneous mass



Always scan both kidneys. When a malignant renal tumour is suspected (at any age), scan the liver and the inferior vena cava. Also X-ray the chest for metastases.

Small kidney



1. A small kidney with nonnal echogenicity may be due to renal artery stenosis or occlusion, or to congenital hypoplasia (Fig. 1I3a).



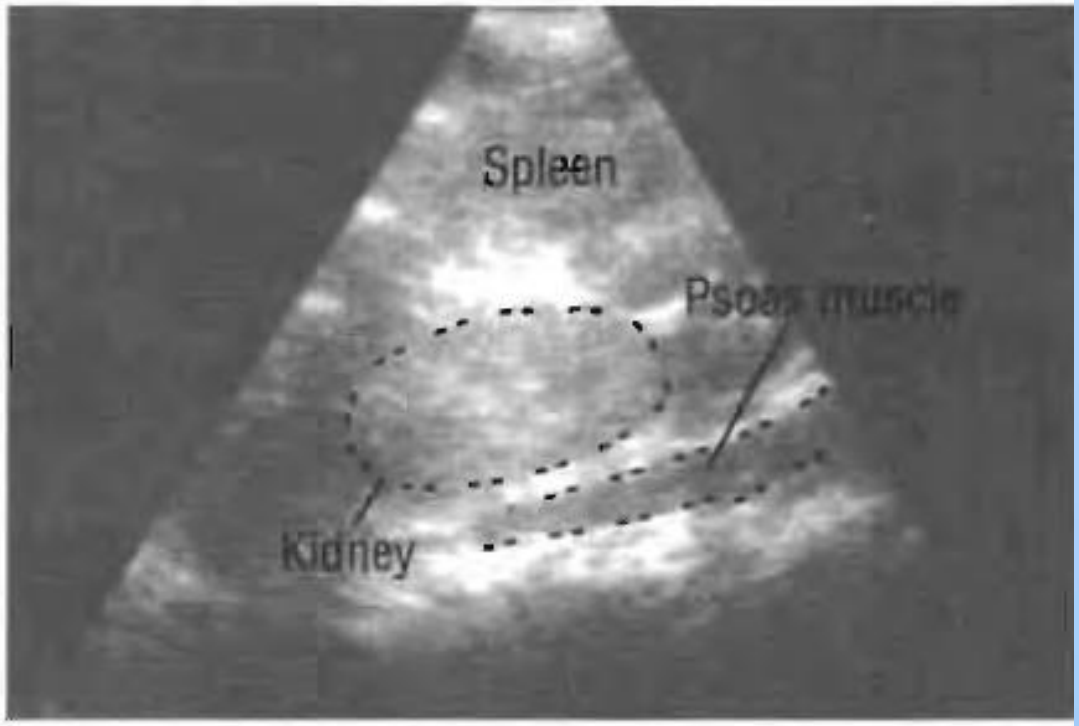

Fig. 113a. Longitudinal scan: a small, isodense but otherwise normal left kidney: the result of renal artery stenosis.

Small kidney



2. A small kidney, nonnal in shape but hyperechogenic, may indicate chronic renal disease (Fig. 1I3b). In renal failure, both kidneys are likely to be equally affected.

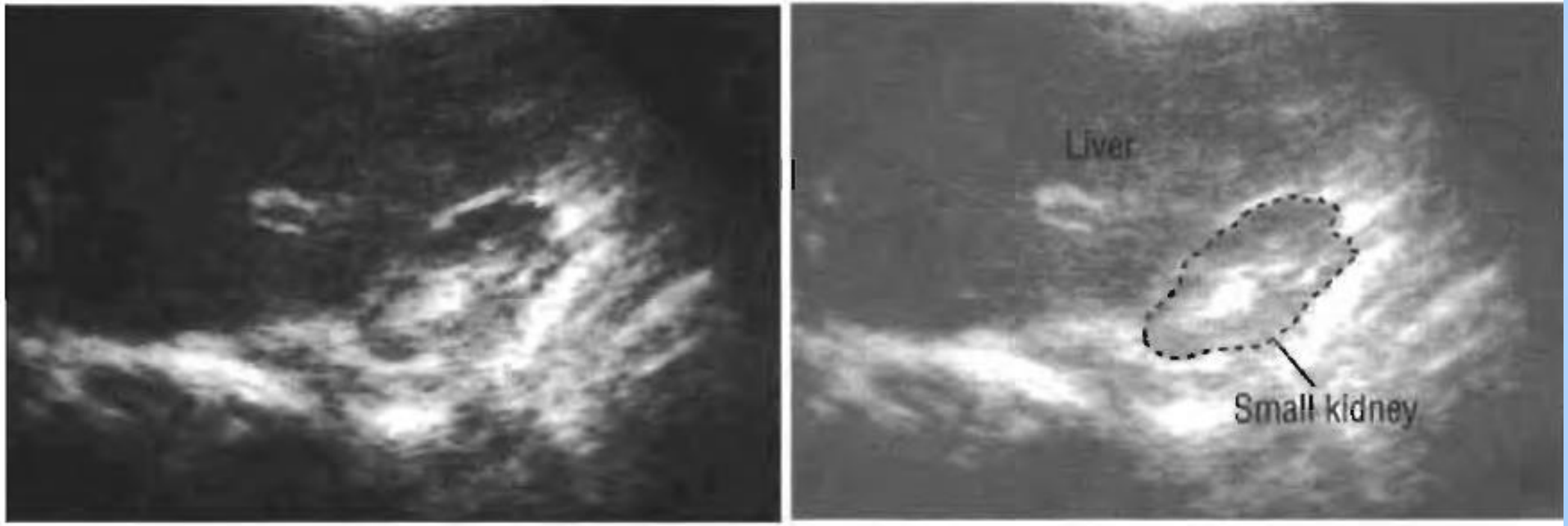

Fig. 113b. Longitudinal scan: a small right kidney, associated with chronic renal failure.

Small kidney



3. A small, hyperechogenic kidney with an irregular, rather "rough“ outline and variable thickness of the cortex (usually bilateral but often very asymmetrical) is probably the result of chronic pyelonephritis or infection such as tuberculosis. There may be calcification in the abscesses, showing as bright areas (Fig. 1I3c).

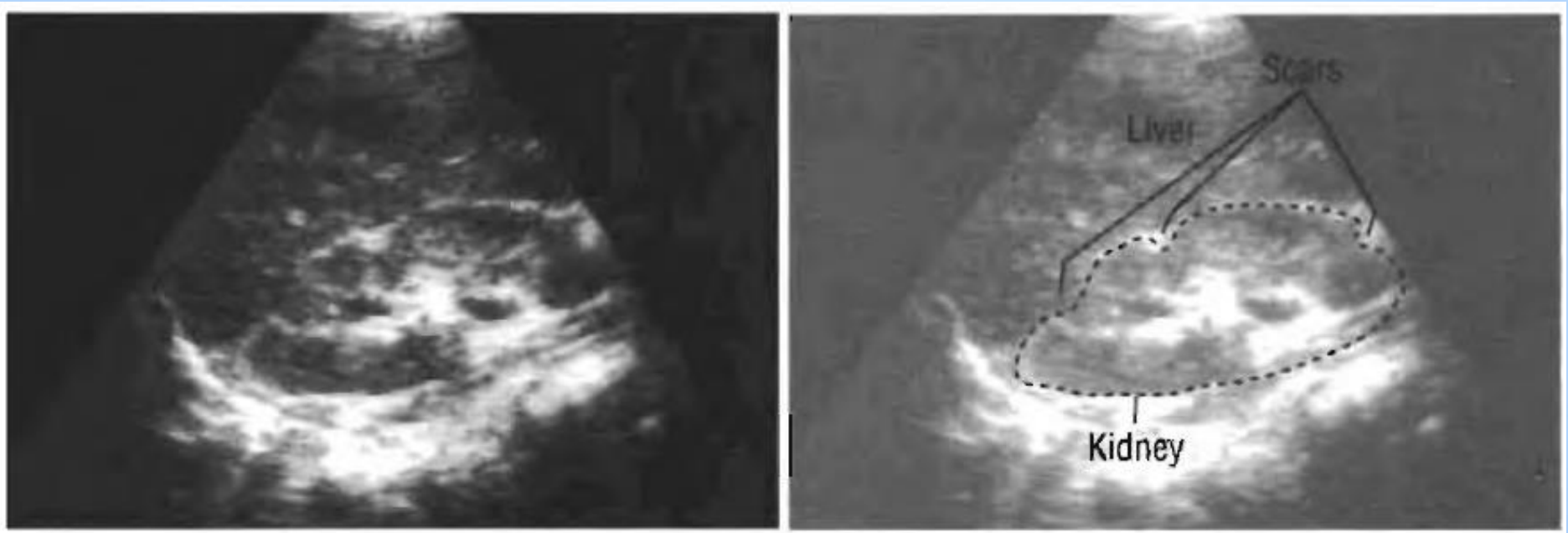

Fig. 113c. Longitudinal scan: a small, irregular (scarred) kidney, the result of chronic pyelonephritis.

Small kidney



4. A single, small, nonnally shaped but hyperechogenic kidney may be due to end-stage renal vein thrombosis. Acute renal vein thrombosis usually causes renal enlargement, with shrinkage occurring later. Chronic obstructive nephropathy can affect one kidney in the same way, but chronic glomerulonephritis is usually bilateral.


Thank you