

Renal calculi (stones)

Dr.Hayder Jasim Taher

PhD of Medical Imaging



Outline of my presentation

- ✓ Renal calculi (stones) .
- ✓ Trauma.
- ✓ Perirenal fluid.
- ✓ Ureters.
- ✓ Cortical changes.
- ✓ Transducers (scanning probes)

Renal calculi (stones)



Not all calculi can be seen on a plain radiograph of the abdomen, and not all renal calculi can be detected by ultrasound. If clinical symptoms suggest calculi, all patients with a negative ultrasound examination need intravenous contrast urography.

Suspected urinary calculi, urine abnormal but negative ultrasound = intravenous urography.

Renal calculi (stones)



Calculi are most easily seen in the renal collecting system. The minimum detectable size on a general purpose ultrasound unit, using a 3.5 MHz transducer, is (3-4) mm diameter. Smaller stones (2-3 mm) may be seen with a 5 MHz transducer. A calculus will be hyperechogenic with an acoustic shadow . The calculus must be visualized in two different planes, longitudinal and transverse, to permit accurate localization and measurement. This may avoid confusion with calcification in the renal parenchyma.

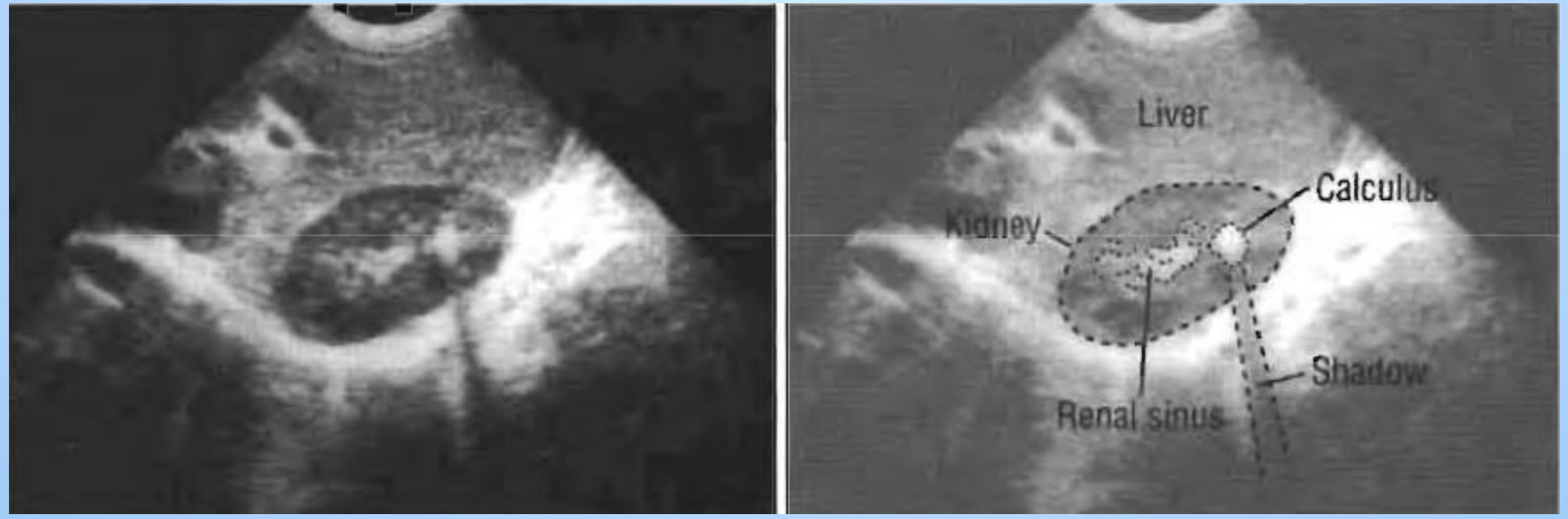

Renal calculi (stones)



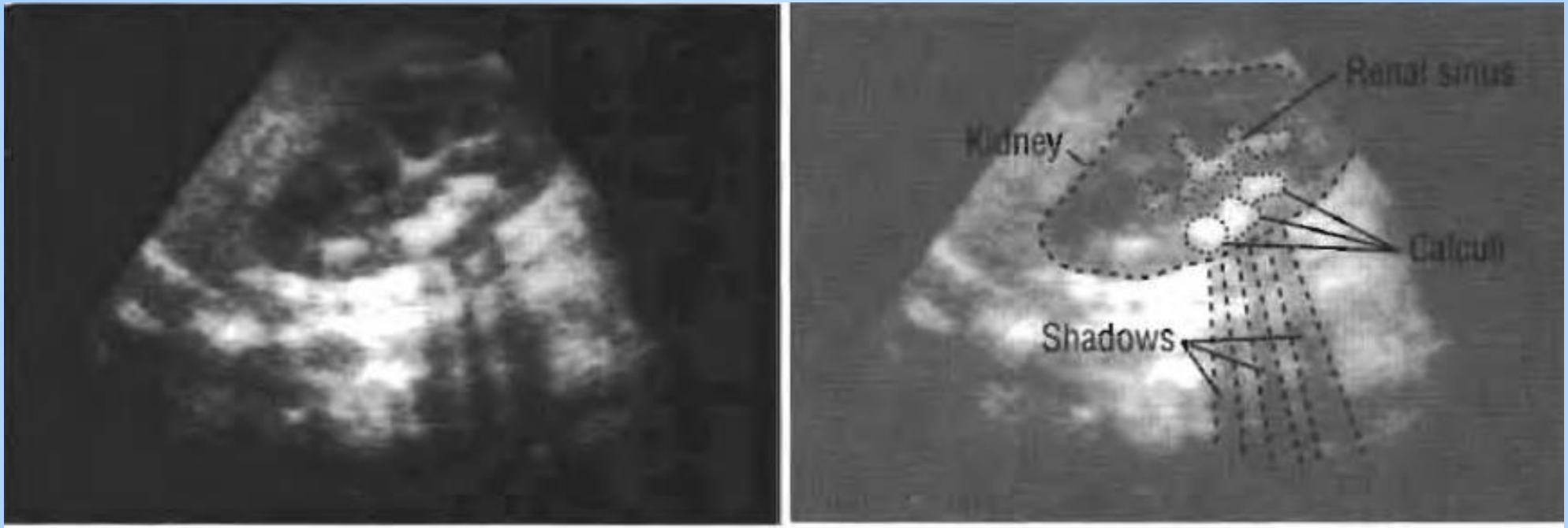

Fig. 114b. Longitudinal scan: multiple calculi in a right kidney.

Ureteric calculi are *very* difficult to locate by ultrasound. *Failure to see a ureteric calculus does not mean that there is no calculus.*

Trauma



1. **In the acute stage**, renal ultrasound may show intrarenal or perirenal echo-free areas as a result of the presence of blood (haematoma) or extravasated urine.

2. **When the blood has clotted and formed a thrombus**, the same areas will show as bright echoes or a mixture of echo and echo-free areas.

Ability to visualize the kidney does *not* mean that it is functioning. To assess renal function, use contrast urography, a radionuclide study or laboratory tests. Remember that injury to a kidney may result in temporary loss of function.

Trauma



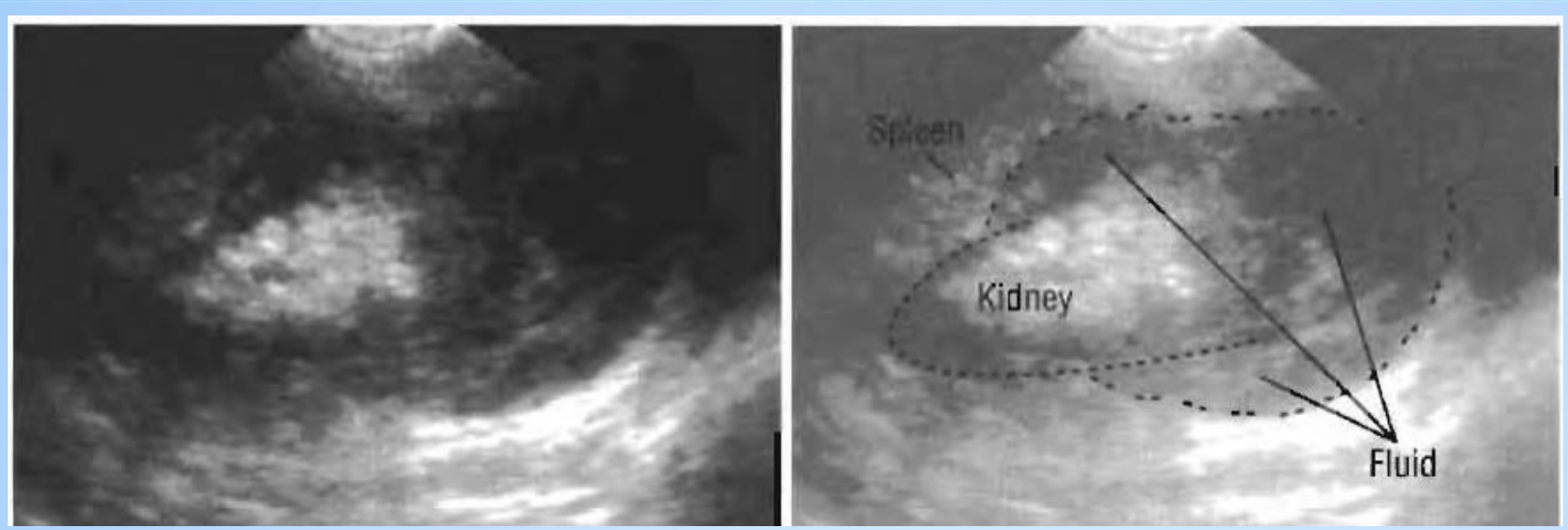

Longitudinal scan of an injured patient: the lower pole of the left kidney has been ruptured and there is fluid (blood or urine) around the left kidney

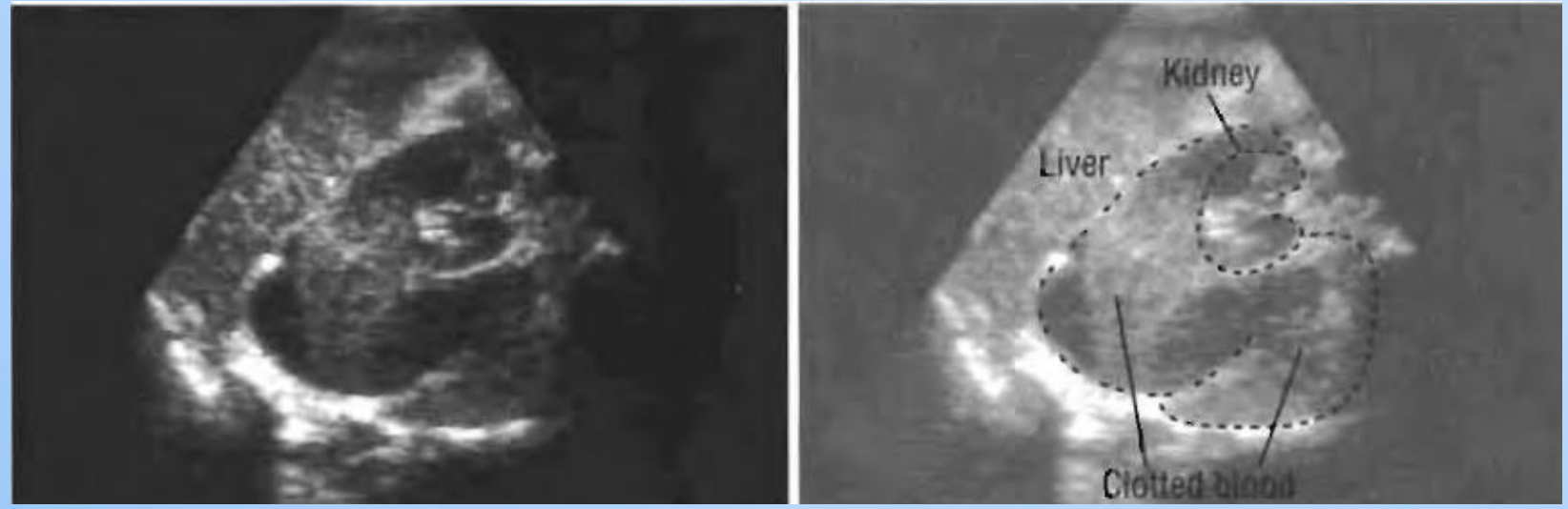

Transverse scan: clotted blood around the right kidney, following injury

Perirenal fluid



Blood, pus and urine around the kidney cannot be distinguished on ultrasound. All appear as an echo-free area



Ureters



Because of their position behind the bowel. it is not easy to examine normal ureters by ultrasound. If dilated (e.g. by outlet obstruction due to an enlarged prostate or urethral stricture, or due to vesico-ureteric reflux), they are easier to see, particularly near the kidney or bladder.

The middle of the ureters is never seen easily and is much better demonstrated by intravenous urography. However, if thickened, as in schistosomiasis (sometimes with calcification), they can be recognized with ultrasound .

The lower end of the ureters can be observed by scanning through a full bladder, which provides a useful acoustic window.

Ureters





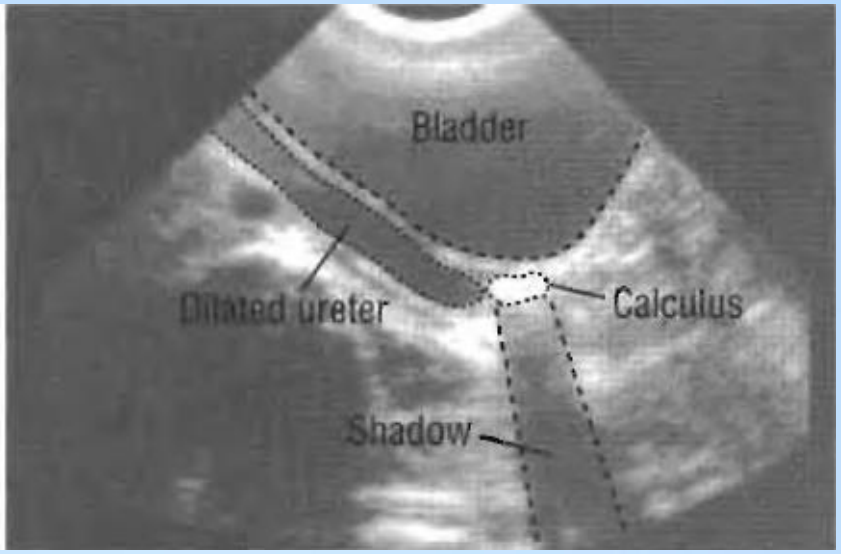

Dilatation of the lower end of the right ureter, caused by a calculus.

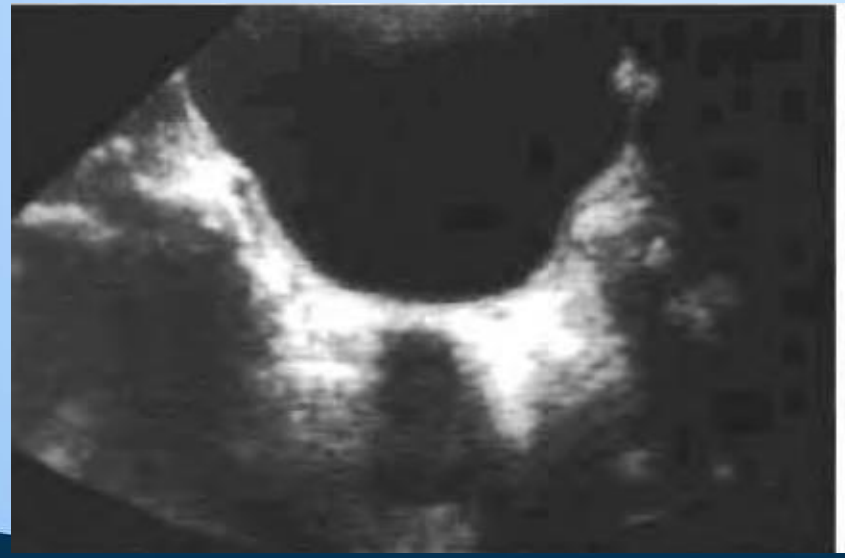

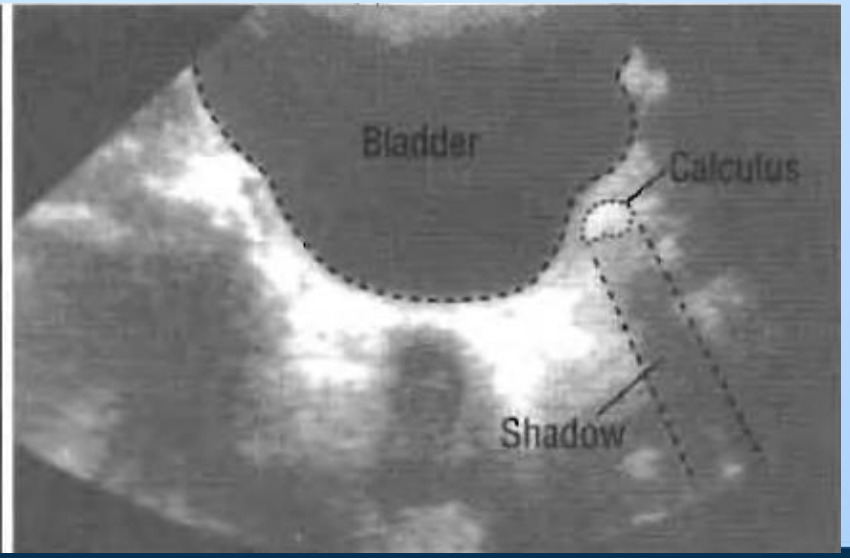

Transverse scan: a large calculus at the lower end of the ureter. Small ureteric calculi may be difficult to localize with ultrasound scanning.

Cortical changes



In acute nephropathies the cortex may swell and increase in thickness. The cortical reflectivity may be either reduced as in acute renal vein thrombosis, or markedly increased, as in some cases of acute glomerulonephritis and acute interstitial nephritis. Assessment of cortical reflectivity can be difficult. In the past it was compared to that of the adjacent liver or spleen assuming that these were normal and an estimate made of whether the reflectivity was less than, equal to or greater than the liver or spleen. In extreme cases of disease the reflectivity of the cortex can be similar to the renal sinus. Normal cortex is generally less reflective than the liver or spleen. However, some modern ultrasound machines may not demonstrate much difference between the kidney and the adjacent liver in normal patients. This is a feature of the equipment pre and post processing characteristics and these should be optimised to enhance display of subtle contrasts between low amplitude echoes.

Cortical changes



In chronic disease the reflectivity of the cortex is also variable. While the cortex may show no apparent change in appearance in some patients with severely impaired function, there is a tendency for cortical thinning to occur. This is usually proportional to the overall decrease in renal length but there is no consistent correlation with the underlying renal disease.

Calcification in the cortex may b e apparent following acute cortical necrosis and rarely in some cases of chronic glomerulonephritis.

Medullary changes and corticomedullary differentiation



The medullary pyramids may be more prominent in many cases of parenchymal disease as the increased cortical reflectivity increases contrast with the echo poor medullary tissue. In other cases there may be a decrease in the degree of corticomedullary differentiation so that the pyramids are poorly defined or even indistinguishable as separate structures (as shown in Figure below) However, as with cortical reflectivity, there is no correlation with the aetiology of the renal disease.

In acute conditions involving primarily the medulla, such as acute tubular necrosis, the pyramids can be enlarged due to oedema. Increased medullary reflectivity can be detected in nephrocalcinosis of any aetiology and also in some other conditions such as gout.

Medullary changes and corticomedullary differentiation



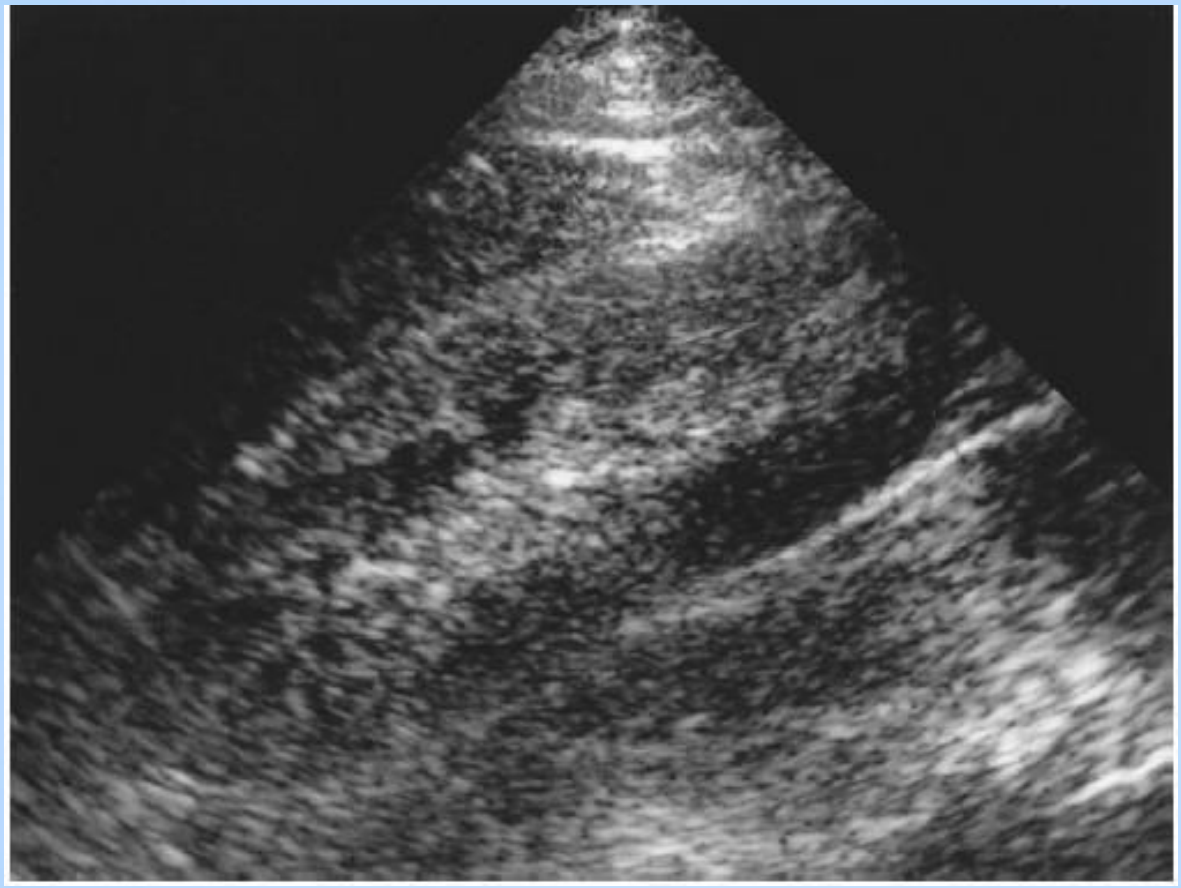

Acute glomerulonephritis. Loss of corticomedullary differentiation in a patient with acute glomerulonephritis.

Vascular disorders



Renal vein thrombosis

Renal vein thrombosis may be seen in up to 40% of septic or dehydrated infants. Acute presentation with renal vein thrombosis is rare in adults. When it does occur it is generally unilateral or restricted to one segment and clinical renal failure does not occur, but it may occasionally be bilateral. It is most commonly associated with the nephrotic syndrome, which it is often considered to cause; however, it usually occurs on a back ground of pre existing renal disease, most commonly membranous nephropathy producing the nephrotic syndrome, so that the venous thrombosis is a result of the underlying renal pathology rather than being the cause. It is also associated with systemic lupus erythematosus, diabetes, glomerulonephritis, hypovolaemic shock and renal transplantation.

Vascular disorders



Renal vein thrombosis

In some patients various abnormalities of coagulation, involving clotting factors, the fibrinolytic system and platelets, can be demonstrated. Other conditions which are associated with the development of renal vein thrombosis in the adult are trauma, oral contraceptives and steroid administration. Dehydration is more commonly associated with renal vein thrombosis in infants, although it may occur in adults, particularly in hot climates. Renal cell carcinoma may invade the renal vein and produce a tumour thrombus which can, like ordinary thrombus, extend into the inferior vena cava (IVC) and provide a source of emboli Left renal vein occlusion in males may present in itially as an acute left varicocele, however, this is extremely rare.

Vascular disorders



On ultrasound the appearances depend on the degree of venous obstruction, the speed with which it has developed and the amount of collateral flow. Sudden complete occlusion of the main renal vein produces an enlarged, echo poor kidney.

The changes develop over the initial 24 hours and are due to swelling of the parenchyma. Echo free areas of haemorrhagic infarcts can be distinguished within the generally echo poor tissue and the renal sinus echoes may be markedly compressed by the swollen parenchyma. After 10 14 days the kidney starts to shrink and over a period of **1-2 months** this results in a small kidney with abnormally high reflectivity. Corticomedullary differentiation is initially preserved but is lost after 3- 4 weeks as the kidney contracts. The renal veins can appear larger than normal and thrombus may be demonstrated within them with extension into the IVC in some patients. In patients with intrarenal segmental vein occlusion, focal areas of oedema and reduced reflectivity may be seen.

Renal artery occlusion



Sudden renal infarction can occur from various causes including atheromatous plaque haemorrhage, aortic dissection, emboli and traumatic avulsion. Unilateral renal artery occlusion does not produce renal failure and without Doppler may be difficult to detect with ultrasound. In the immediate acute stage following complete arterial occlusion the affected kidney may be normal in size and have normal reflectivity but a small increase in size compared with the perfused contralateral kidney may be demonstrated. In some patients a subcapsular ‘ or rim of echo poor tissue can be seen which is thought to correspond to oedematous perfused tissue fed by capsular collateral vessels. In the longer term the affected kidney slowly shrinks with smooth margins and no dilatation of the collecting system. Colour or power Doppler ultrasound fails to show any arterial flow within the kidney; echo enhancing agents will increase diagnostic certainty if there is any doubt over the diagnosis.

Renal artery stenosis



Narrowing of the renal arteries can cause hypertension and may be implicated in up to 5% of patients with hypertension. In one study with patients selected for ultrasound and Doppler assessment for possible renal artery stenosis, there was a prevalence of 22% for renal artery stenosis of > 60% diameter reduction. The commonest causes are atheroma and fibromuscular dysplasia of the vessel wall; other causes include aortic aneurysm, arteritis, emboli, neurofibromatosis and trauma. It is important to make the diagnosis since correction of the stenosis may allow cessation of drug therapy, or at least make therapeutic control easier.

In a patient with unilateral renal artery stenosis the affected kidney is usually of normal shape and size unless the stenosis is greater than 60%, when a small decrease in size may be found.


Thank you