

# Normal and abnormal Urinary bladder

*Dr. Hayder Jasim Taher*

*PhD of Medical Imaging*



# Outline of my presentation

- ✓ Indications.
- ✓ Preparation.
- ✓ Normal bladder.
- ✓ Abnormal bladder.
  - ✓ Generalized thickening of the bladder wall Attenuation
  - ✓ Localized thickening of the bladder wall Boundaries
    - ✓ Differential diagnosis of localized bladder wall thickening
- ✓ Density within the bladder.

# Indications



1. Dysuria or frequency of micturition.

2. Haematuria (wait until bleeding has stopped).

3. Recurrent infection (cystitis) in adults; acute infection in children.

4. Pelvic mass.

5. Retention of urine.

6. Pelvic pain

**Always scan both kidneys when examining the bladder.**

# Preparation of the patient



The bladder must be full. Give 4 or 5 glasses of fluid and examine after one hour (do not allow the patient to micturate). Alternatively, fill the bladder through a urethral catheter with sterile normal saline: stop when the patient feels uncomfortable. Avoid catheterization if possible because of the risk of infection.

**Normal bladder**

The full urinary bladder appears as a large. echo-free area arising out of the pelvis. Start by assessing the smoothness of the interior wall of the bladder and its symmetry in transverse section. The thickness of the bladder wall will vary with the degree of distention but should always be approximately the same all around the bladder. Any local area of thickening is abnormal. Look also for trabeculation. When distended. the normal bladder wall is less than 4 mm thick.

# Normal bladder



After scanning. the patient should empty the bladder (Fig. 120c). Normally. there should be no residual urine: if there is. the quantity should be estimated. Measure the transverse diameter (T) of the bladder in centimetres. multiply it by the longitudinal diameter (L) in centimetres and then by the AP diameter in centimetres. Multiply the total by 0.52. This measures the residual urine in millilitres (cubic centimetres).

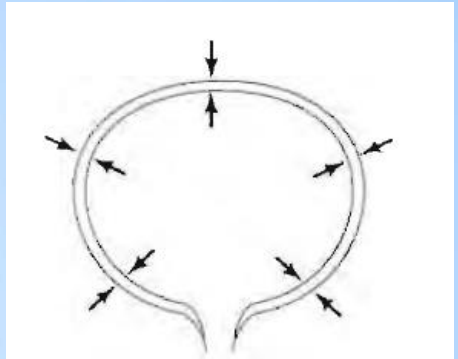

full bladder: wall less than 4 mm thick

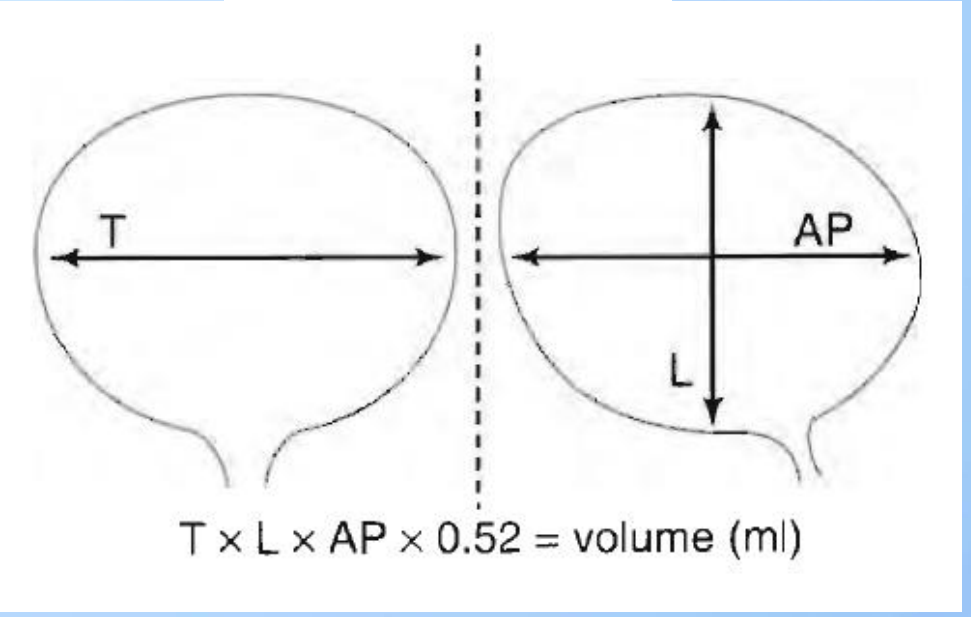

# Normal bladder



When the bladder has been thoroughly examined. scan the kidneys and the ureters

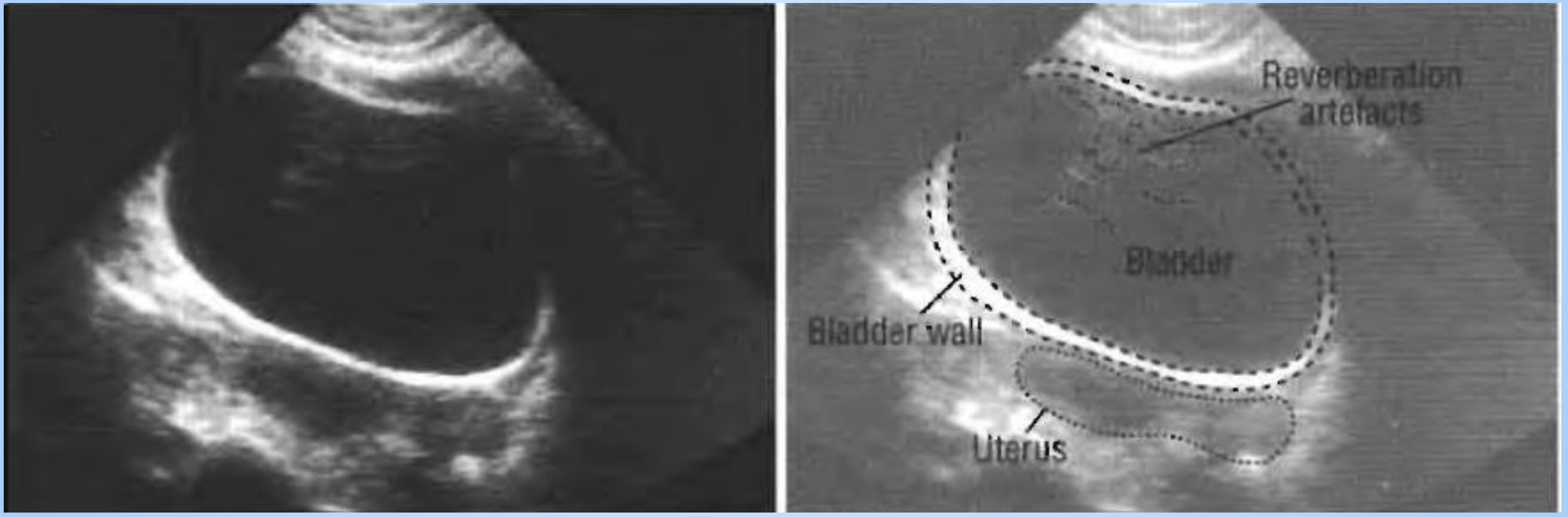


**Longitudinal scan: normal full bladder.**

# Normal bladder



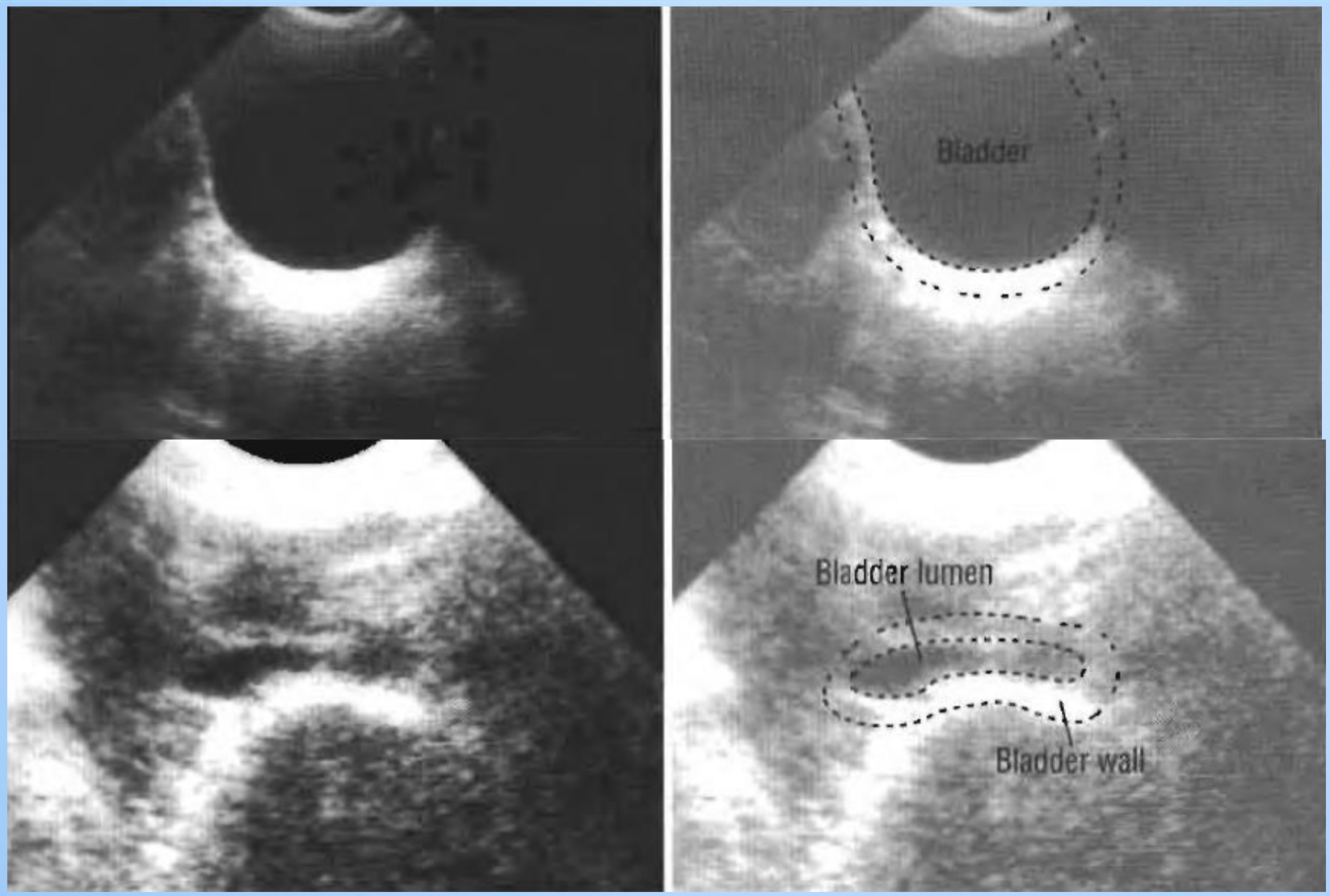


**Transverse scan: normal full bladder.**

**Transverse scan: normal empty bladder.**

# Abnormal bladder



**It is important to scan for:**

1. Variation of the bladder wall thickness and trabeculation.
2. Asymmetry of the bladder.
3. Cystic masses in or outside the bladder (ureterocele or diverticulum).
4. Solid masses within the bladder or at the base of the bladder.

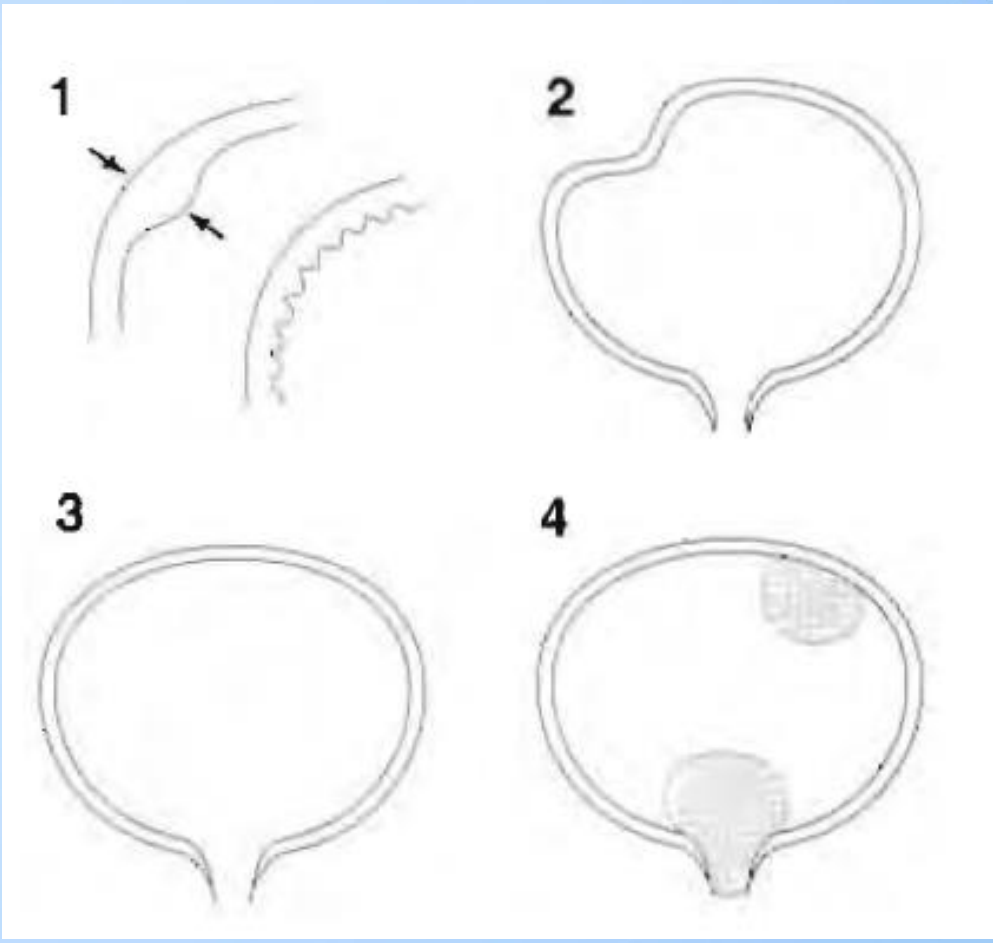

# Generalized thickening of the bladder wall



1. In men, bladder wall thickening is usually the result of prostatic obstruction . If suspected, check the prostate : exclude hydronephrosis by scanning the ureter and the kidneys. Search for associated diverticula: these project outwards but are only visible if over 1 cm in diameter. Diverticula are usually echo-free with good sound transmission . Sometimes the opening of a diverticulum can be demonstrated: diverticula may collapse or increase in size after micturition.

# Generalized thickening of the bladder wall



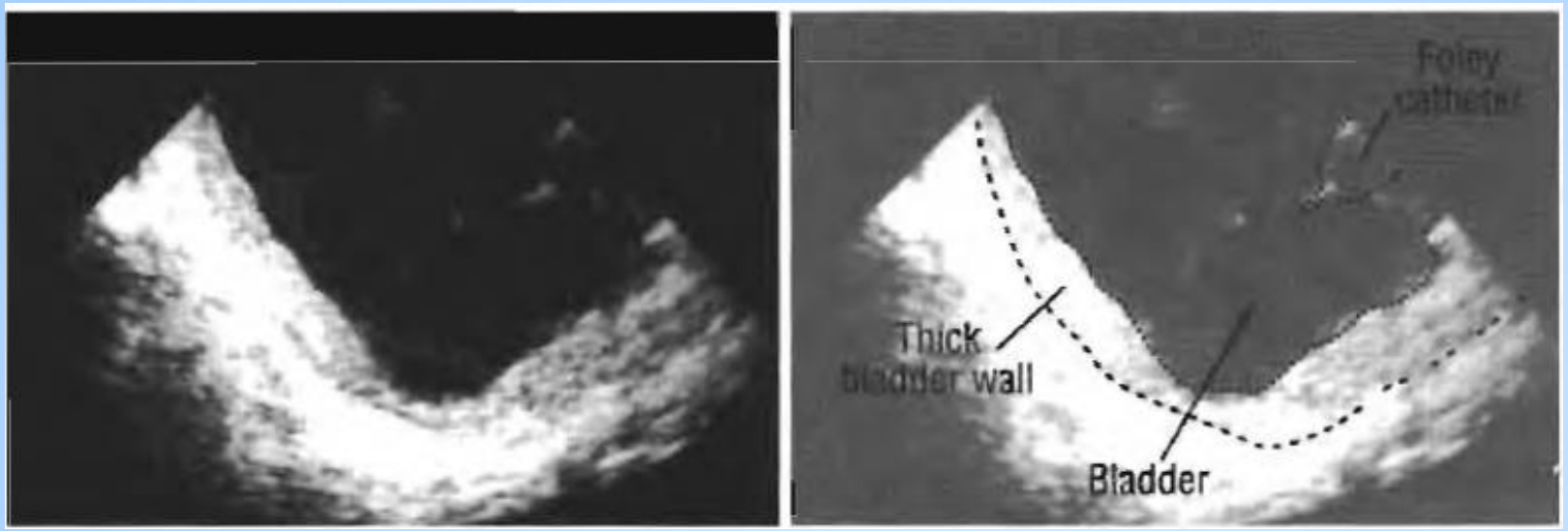


Hypertrophy of the wall of the bladder.

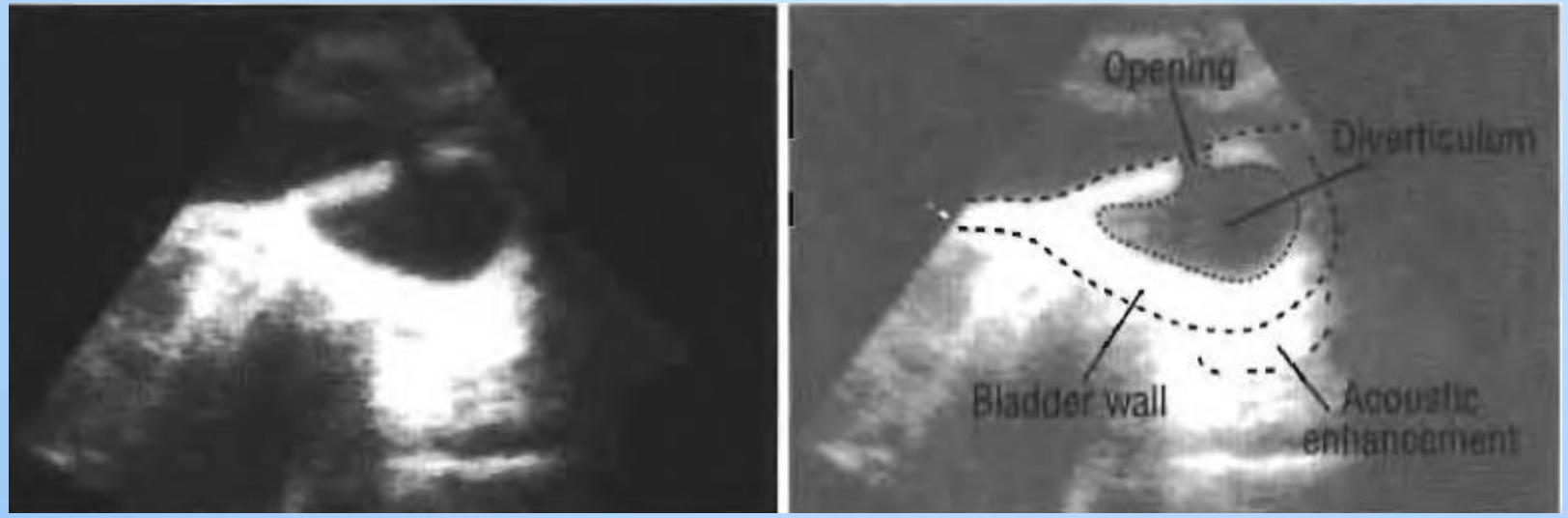


Longitudinal scan: diverticulum of the bladder.

# Generalized thickening of the bladder wall



2. Severe, chronic infection/ cystitis. The inner wall of the bladder may be thickened and irregular . Check the rest of the renal tract for dilatation.

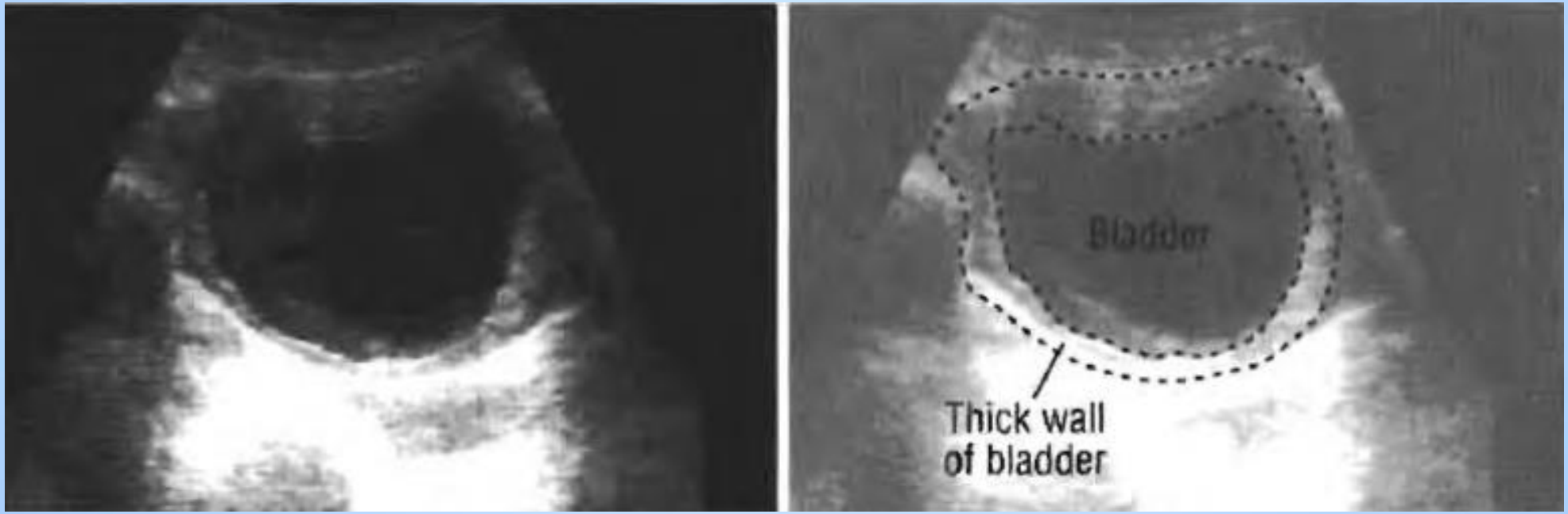


**Chronic bladder infection (chronic cystitis).**

# Generalized thickening of the bladder wall



3 . Schistosomiasis. The bladder walls may be thickened. with increased echogenicity and scattered dense (bright) areas due to calcification.

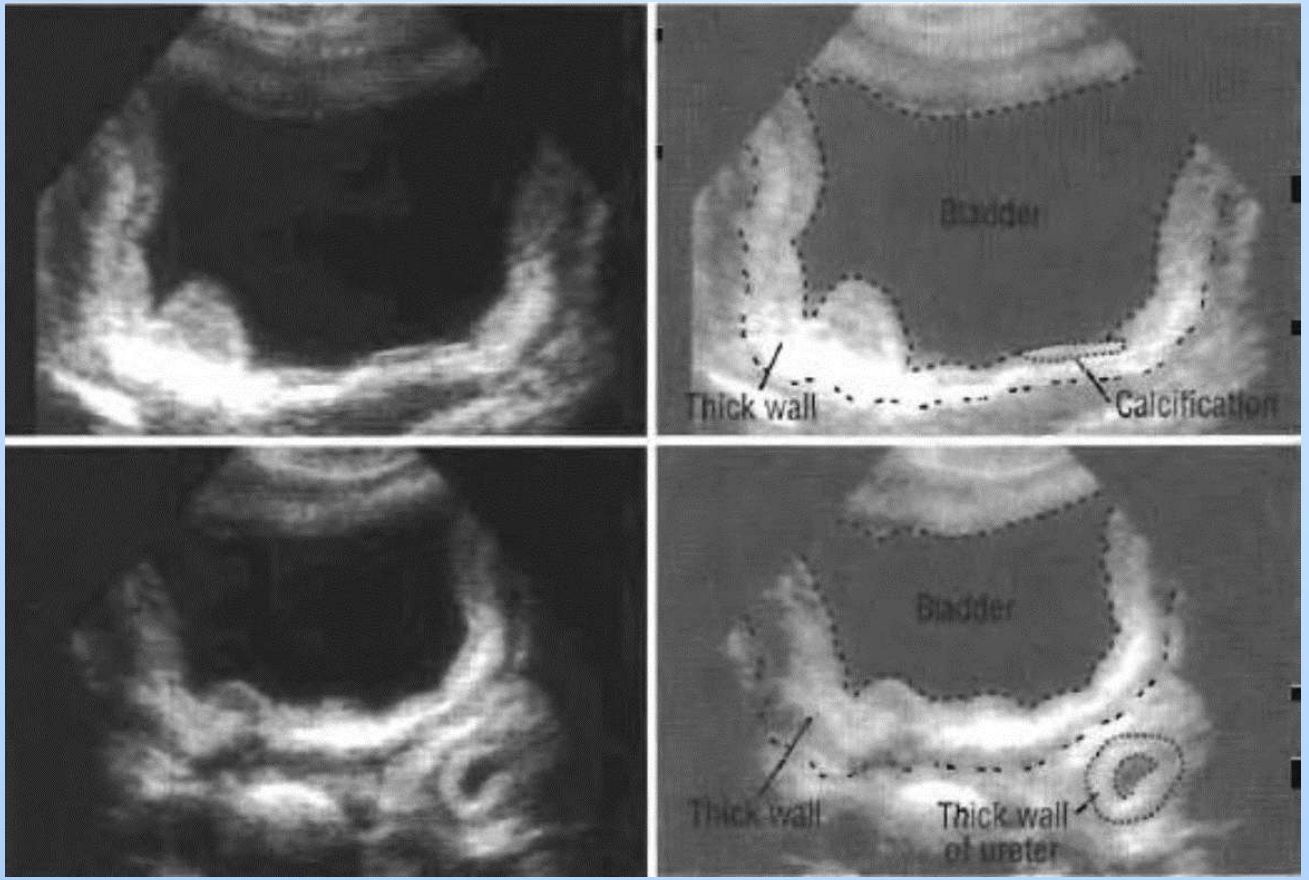


**Two transverse scans showing thickening and irregularity of the bladder wall of a 12-year-old child with schistosomiasis. The left ureter is also thickened (lower).**

# Generalized thickening of the bladder wall



4. Very thick trabeculated bladder walls in children may result from outlet obstruction caused by urethral valves or urogenital diaphragm.

5. A thickened bladder wall may occur in a neurogenic bladder and will usually be associated with uretero-hydronephrosis.

# Localized thickening of the bladder wall



Whenever localized bladder wall thickening is suspected, multidirectional scans are needed, particularly to exclude a polyp. Moving the patient or increasing the volume of fluid in the bladder will help to identify bladder folds. (Folds will disappear as the bladder distends.)

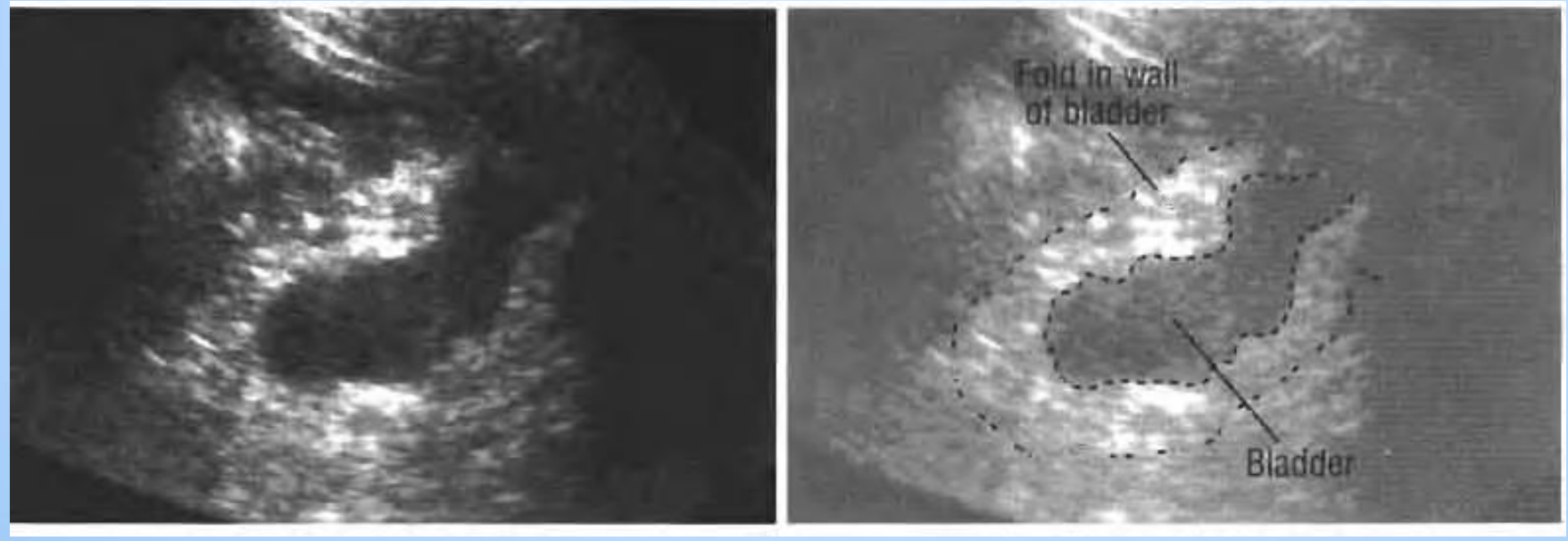


**Longitudinal scan: apparent thickening with folds in the wall of a partially filled bladder.**

# Localized thickening may be due to:



1. Bladder fold due to incomplete filling .

2. Tumour: sessile or polypoid, single or multiple .

3. Localized infection due to tuberculosiS or to schistosomal plaques (granulomas) .

4. Acute reaction to schistosomal infection in children.

5. Haematoma following trauma .

# Differential diagnosis of localized bladder wall thickening



1. Most bladder neoplasms are multiple but located in one area. Some only thicken the bladder wall, but most are also polypoid. It is essential to recognize when the tumour has spread through the bladder wall. Calcification in the tumour or wall due to associated schistosomiasis may cause bright echoes
2. Bladder polyps are often mobile on a stalk.
3. Granulomas (e. tuberculous) cause multifocal but localized.
4. Trauma. If there is localized thickening following trauma, scan the pelvist to exclude fluid (blood or urine) outside the bladder.
5. Schistosomiasis. Children who are reinfected.

# Differential diagnosis of localized bladder wall thickening



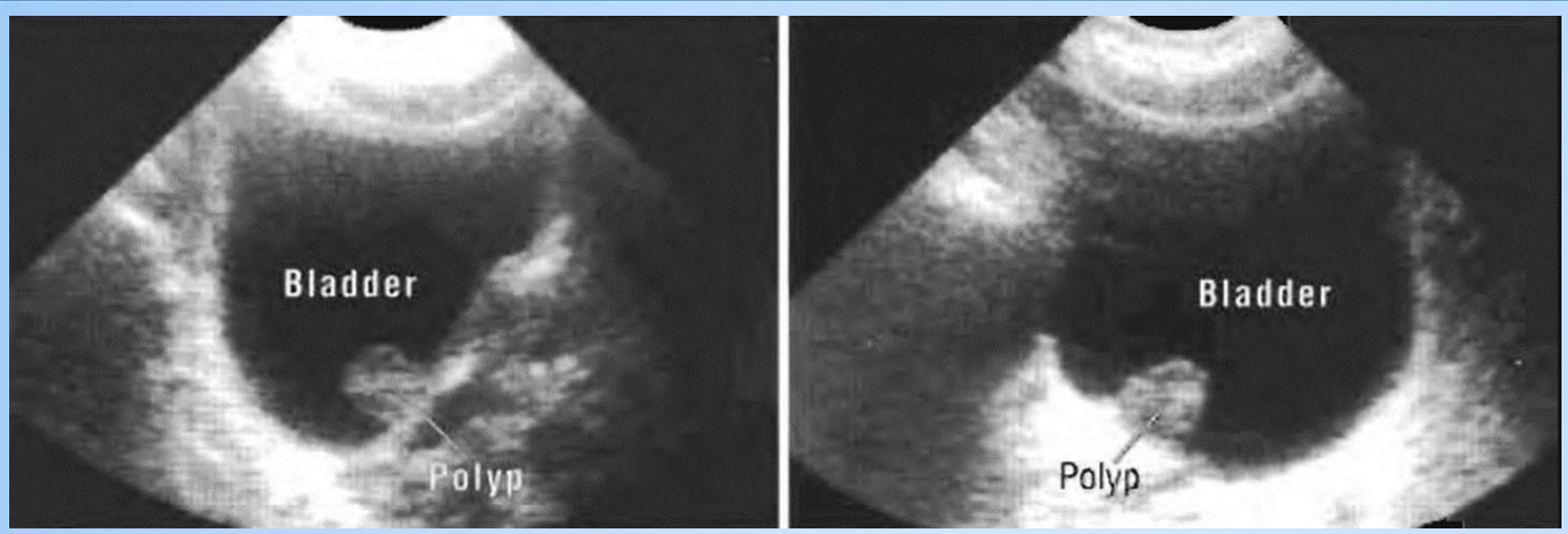





A sessile polyp in the bladder: longitudinal (left) and transverse (right) scans.

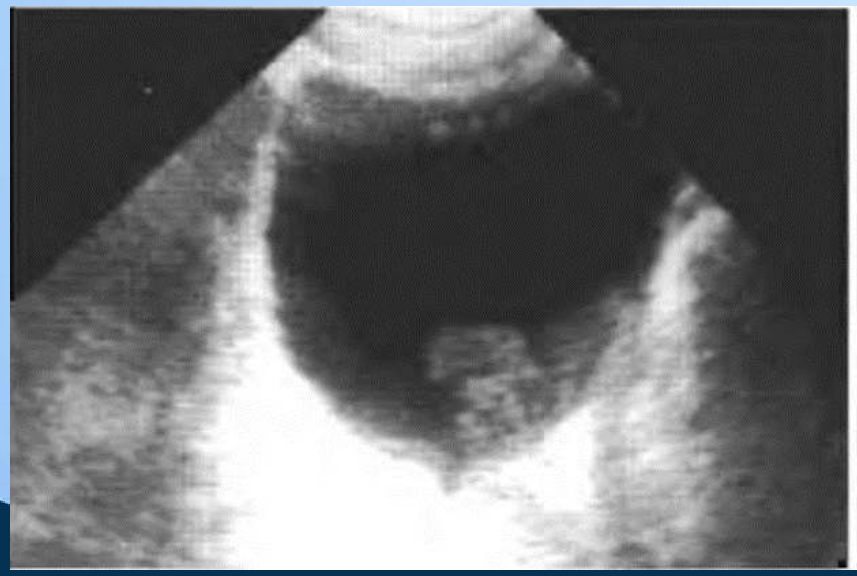

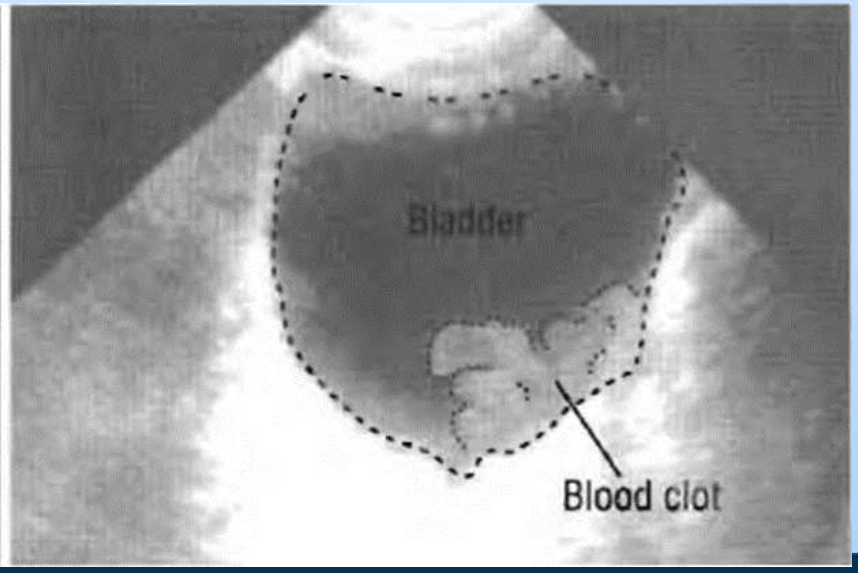


Transverse scan: pseudotumour in the bladder, caused by blood clots.

# Differential diagnosis of localized bladder wall thickening



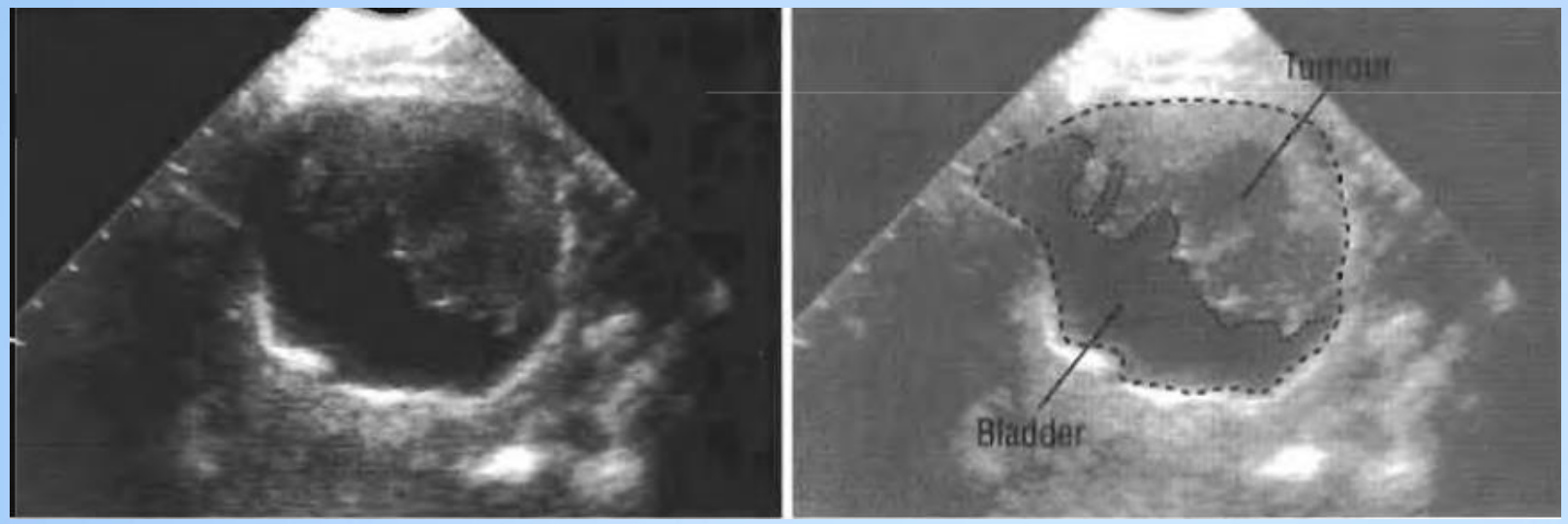


Transverse scan: a large malignant tumour arising from the bladder wall.

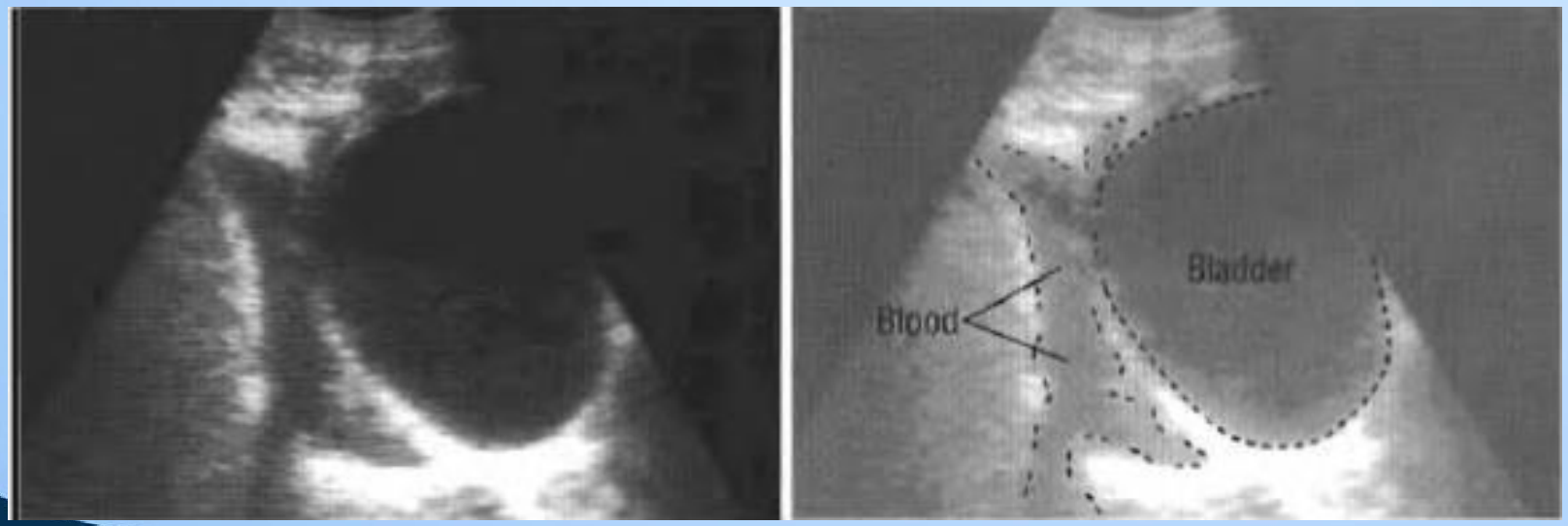


Transverse scan: following injury, there is blood lateral to the bladder, distorting and apparently thickening the bladder wall.

# Density within the bladder



1. **Attached to the wall**
   - **Polyp.** A polyp on a long stalk may appear freely mobile. Change the patient's position and rescan.
   - **Adherent calculus.** Calculi can be single or multiple, small or large: they usually have acoustic shadowing. Some may become adherent to the bladder mucosa, especially when there is infection: scan with the patient in different positions to assess movement.
   - **Ureterocele.** A ureterocele presents as a cystic mass within the bladder, near a ureteric orifice. It will change in size fi scanned at different times. In children, the ureterocele may be so large that the opposite ureter is also obstructed. Ureteroceles are sometimes bilateral but are seldom symmetrical. If suspected, scan the kidneys and the ureters for asymmetrical hydronephrosis and hydroureter, and for duplication of the ureters.
   - **Enlarged prostate.** An-echogenic, non mobile mass located centrally at the base of the bladder in a male patient is most likely an enlarged prostate. In women, an enlarged uterus can also distort the bladder.

# Density within the bladder



**2. Mobile density within the bladder**

- **Calculus.** Unless they are very large. most calculi move within the bladder . However. calculi may be trapped in a diverticulum
- **Foreign body.** Catheters must be recognized . Very rarely a foreign body is introduced into the bladder. If this is suspected. a careful history is necessary: X-rays may be helpful.
- **Blood clot.** A thrombus can resemble a calculus or a foreign body: not all blood clots are freely mobile .
- **Air.** Introduced into the bladder either through a catheter or by infection or through a fistula. air appears as an echogenic. mobile. non-dependent (floating) area.

# Large (overdistended) bladder



When distended, the bladder walls will be smooth and evenly stretched, with or without diverticula Use measurements to confirm suspected overdistension .
Always look at the ureters and check the kidneys for hydronephrosis. Ask the patient to empty the bladder and rescan to see if it is completely empty .
Common causes of bladder distention are:

1. Enlargement of the prostate.
2. Urethral stricture in the male.
3. Urethral calculus in the male.
4. Bruising of the urethra in the female ("honeymoon urethritis").
5. A neurogenic bladder from damage to the spinal cord.
6. Urethral valves or diaphragm in newborn infants.
7. Cystocele in some patients.

# Small bladder



A bladder may be small because of cystitis which prevents the patient from holding urine and causes a clinical history of frequent and painful micturition. The bladder may also be small because the walls have been damaged or fibrosed, reducing the bladder capacity. Micturition will then be frequent but not painful.

**A small bladder may be due to:**

1. Late schistosomiasis. There may be bright echoes due to calcification.
2. Recurrent cystitis. particularly due to tuberculosis. Bladder wall thickening is likely.
3. The rare infiltrating neoplasm. When there is a tumour. the bladder wall is nearly always asymmetrical.
4. Radiotherapy or surgery for malignancy. Check the clinical history.


Thank you