

Normal and abnormal thyroid gland

Dr. Hayder Jasim Taher

PhD of Medical Imaging



Outline of my presentation

- ✓ Indications.
- ✓ Normal anatomy.
- ✓ Abnormal thyroid.
- ✓ Other masses in the neck.
- ✓ Vascular abnormalities.

Indications



- A palpable mass in the neck.
- Abnormalities in the carotid arteries (a bruit or symptoms of carotid insufficiency).

  Doppler ultrasound is needed for a complete assessment.

Ultrasound is *not* a reliable way to exclude a parathyroid tumour.

Normal anatomy



Ultrasound
can demonstrate the following normal structures in the neck:

- Carotid arteries.
- Jugular veins.
- Thyroid gland.
- Trachea.
- Surrounding muscles.

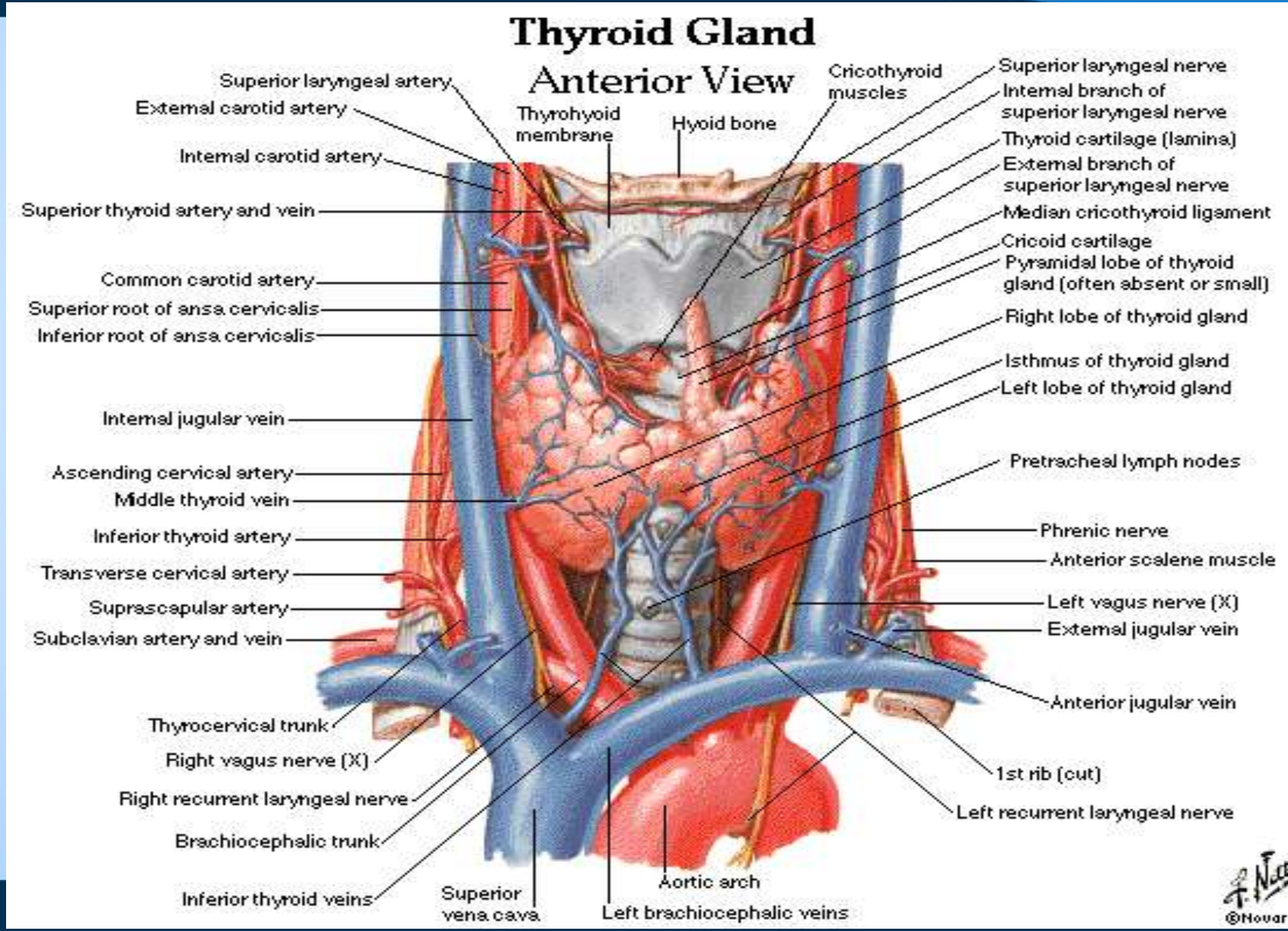

Normal anatomy



It is important that all of these structures are located when scanning the neck.

• **Vessels.** The vascular bundle (the carotid artery and the jugular vein) is behind and between the sternocleidomastoid muscle and lateral to the thyroid gland. These vessels are very accessible for ultrasonography.

The carotid artery, bifurcating into the internal and external branches, will be seen as a tubular structure with hyperechogenic walls and an echo free Centre:

the walls are smooth and difficult to compress with the transducer. The jugular vein is lateral to the carotid artery and the walls are more easily compressed. The veins vary in diameter during the different phases of respiration and the Valsalva manoeuvre.

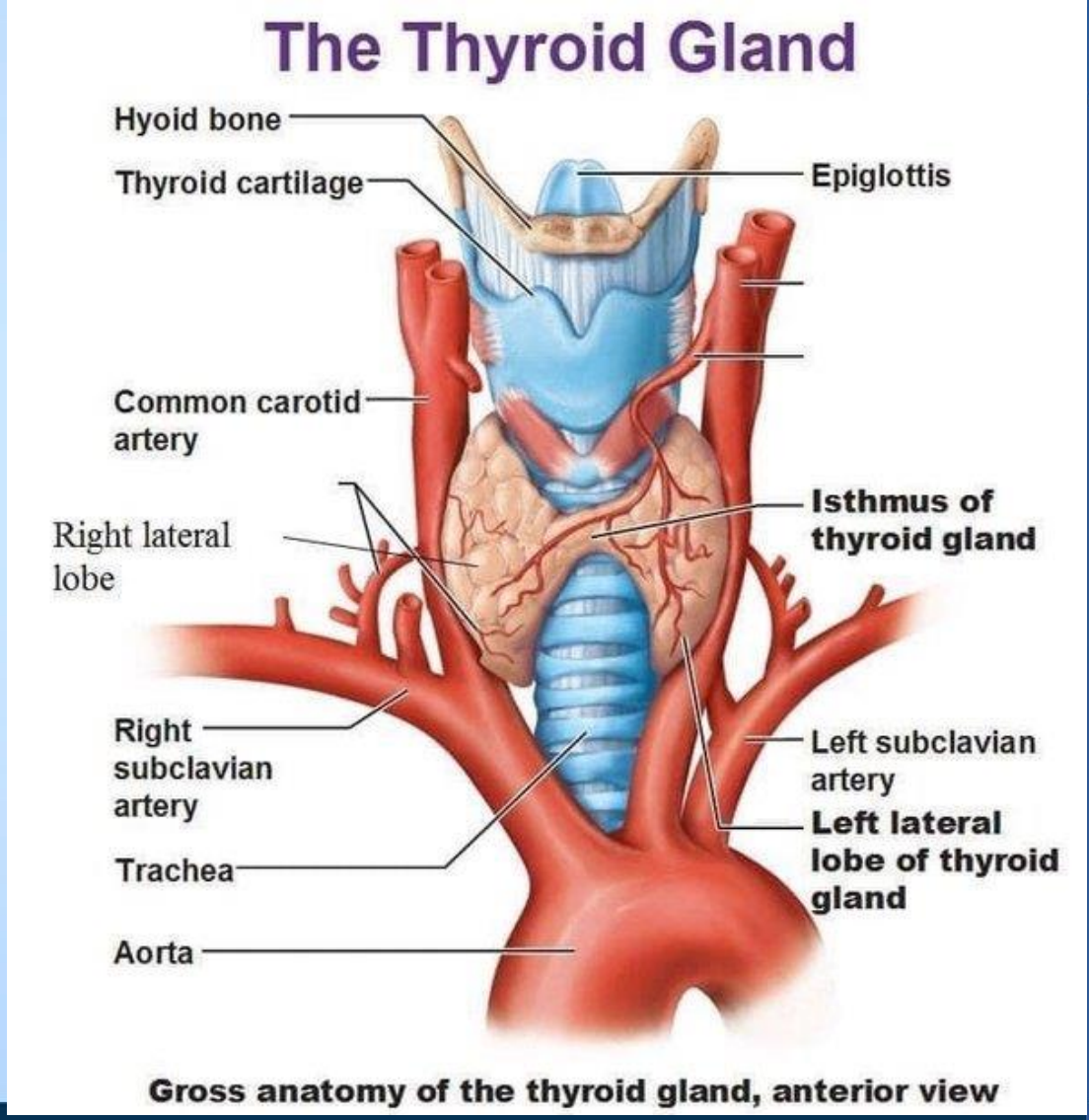

Gross anatomy of the thyroid gland, anterior view

Normal anatomy



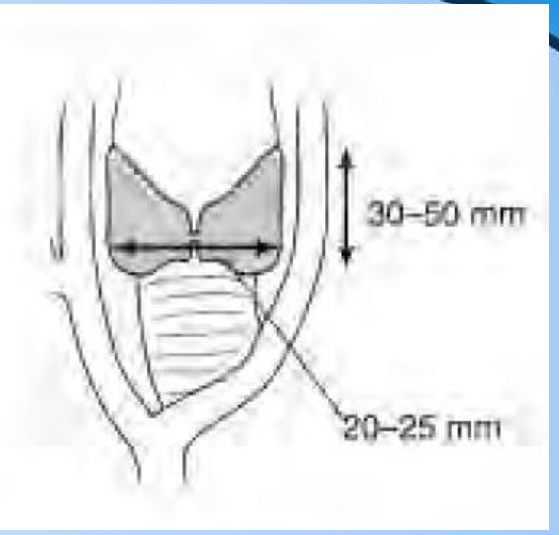

• **Thyroid.** The thyroid consists of two lobes, one on either side of the trachea joined in the midline by an isthmus. The thyroid gland and the isthmus have the same homogeneous echo texture, and the lobes should be equal in size. On transverse scans, the section is usually triangular; on longitudinal scans, it is oval. The outline should be smooth and regular .

The thyroid gland is normally 15-20 mm thick, 20-25 mm in width, and 30-50 mm in length.

• **Muscles.** The sternocleidomastoid muscle is the only muscle of particular importance in pediatric patients. The muscles are band like structures which are less echogenic than the thyroid. On transverse scans, the outline is well defined but varies from circular to ovoid in section.

• **Lymph nodes.** Normal lymph nodes can sometimes be seen as hypoechogenic structures less than 1 cm in diameter.

Normal anatomy



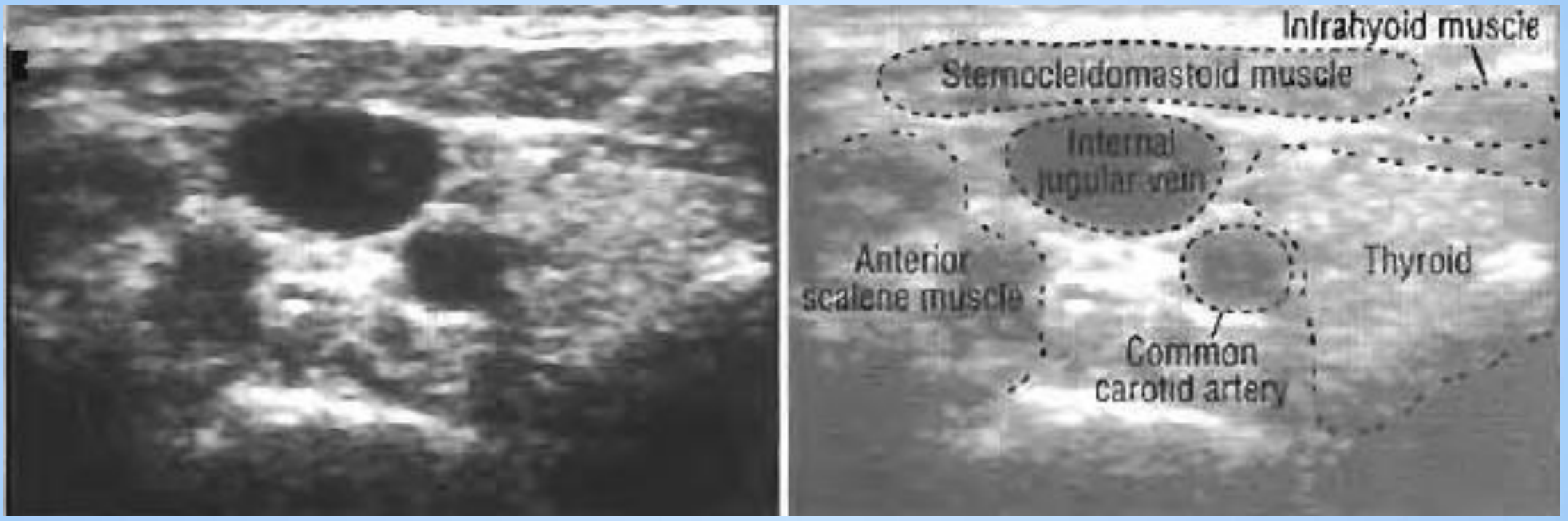

Transverse scan: the common carotid artery, jugular vein, thyroid gland and sternocleidomastoid muscle.

Normal anatomy



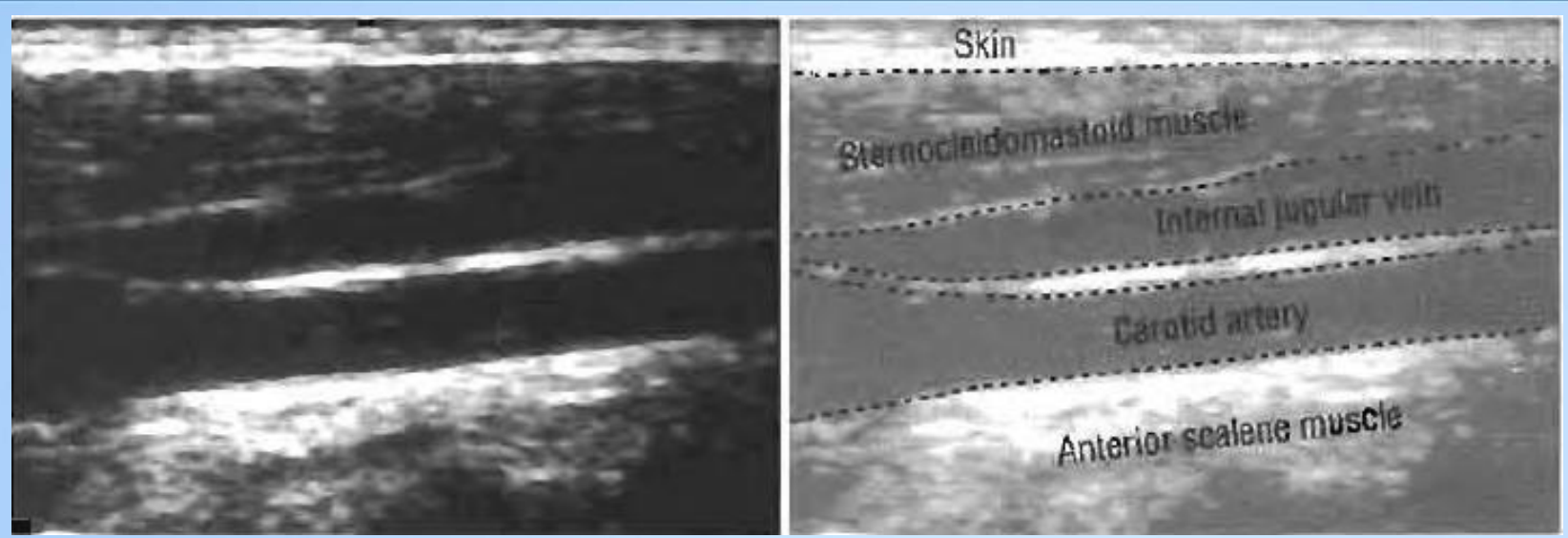

Transverse scan: the common carotid artery, jugular vein, and sternocleidomastoid muscle.

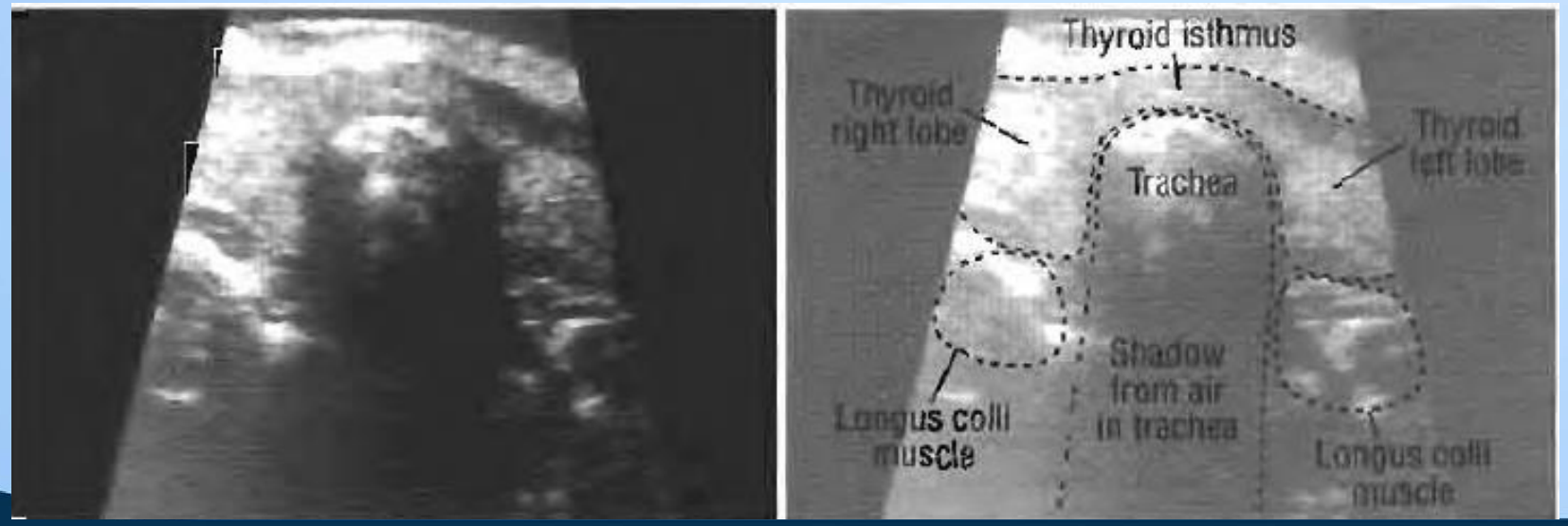

Transverse scan: the normal thyroid gland, including the isthmus

Abnormal thyroid



Thyroid abnormalities may be local or diffuse, single or multiple.

Focal masses

1. Solid. About 70% of focal lesions are thyroid nodules and over 90% of these will be adenomas, which are very **seldom malignant**. The ultrasound appearance of an adenoma is variable, and it may be impossible to differentiate between a benign thyroid adenoma and a malignant tumour: the ultrasound characteristics are similar, and size is not important. Both benign and malignant tumours can be hypo or hyperechogenic; both may contain cystic components. However, if the massis well circumscribed, with a surrounding thin, hypochogenic halo, there is a 95% probability that it is a benign adenoma. When thereis central necrosis, the possibility of malignancy should be considered.

Abnormal thyroid



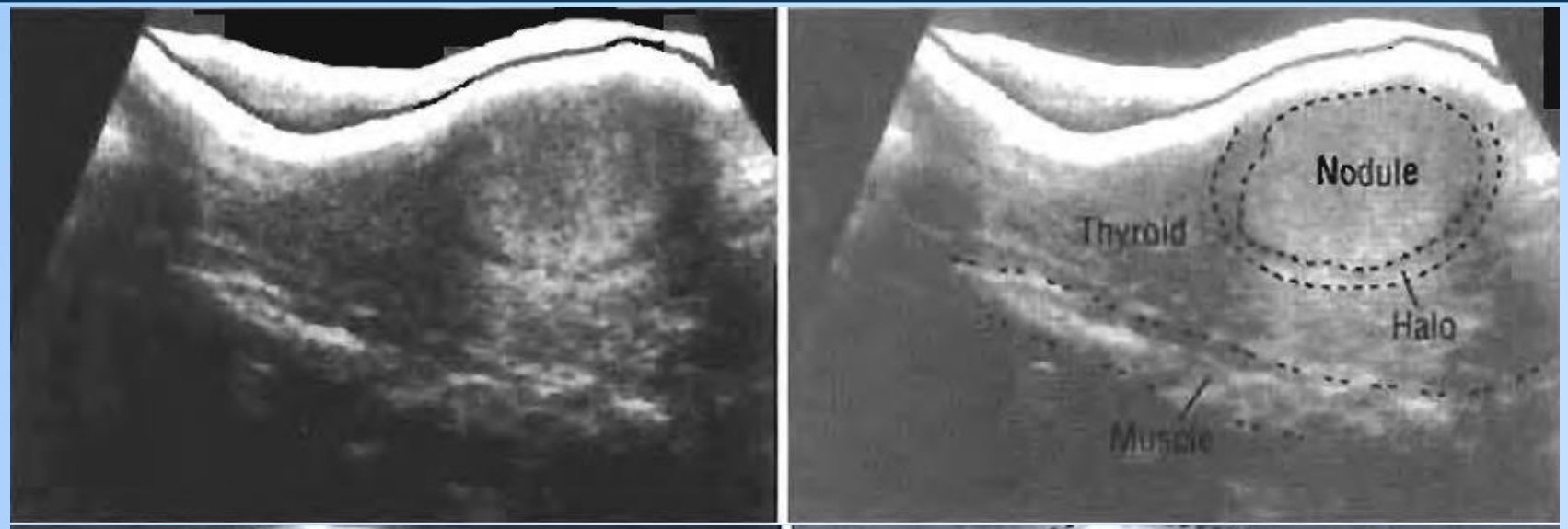

Longitudinal scan: an isodense nodule in the thyroid. surrounded by a hypoechogenic halo.

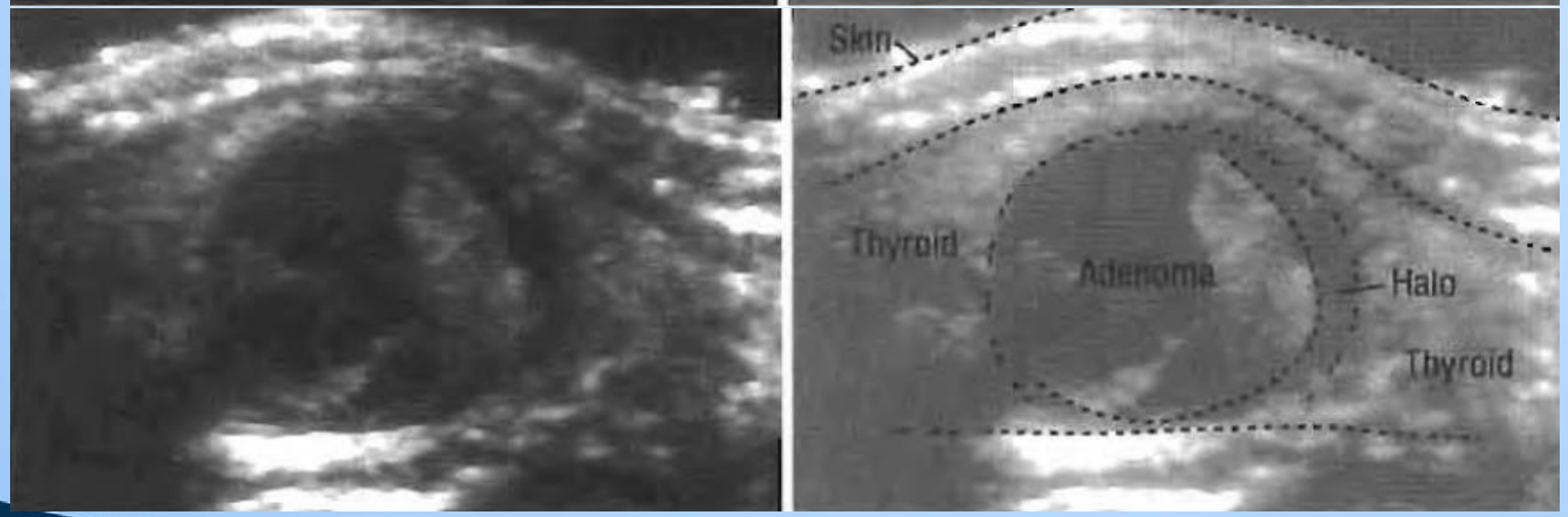

Longitudinal scan: a benign thyroid adenoma with cystic changes

Abnormal thyroid



2. Cystic True cysts of the thyroid are rare. Characteristically, they are well circumscribed, with smooth walls, and are echo free, unless there has been haemorrhage into the cyst.

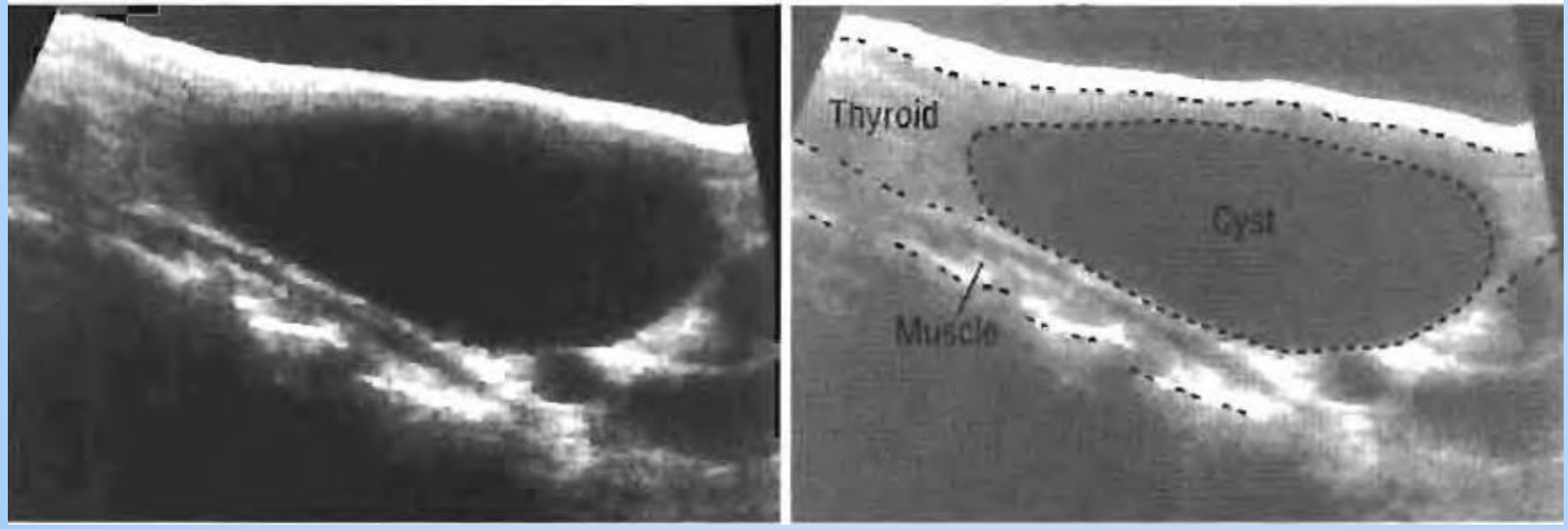

Longitudinal scan: a cyst in the thyroid.

Abnormal thyroid



3. Haemorrhage or an abscess may occur in the thyroid, appearing as a cystic or complex pattern with ill defined edges.

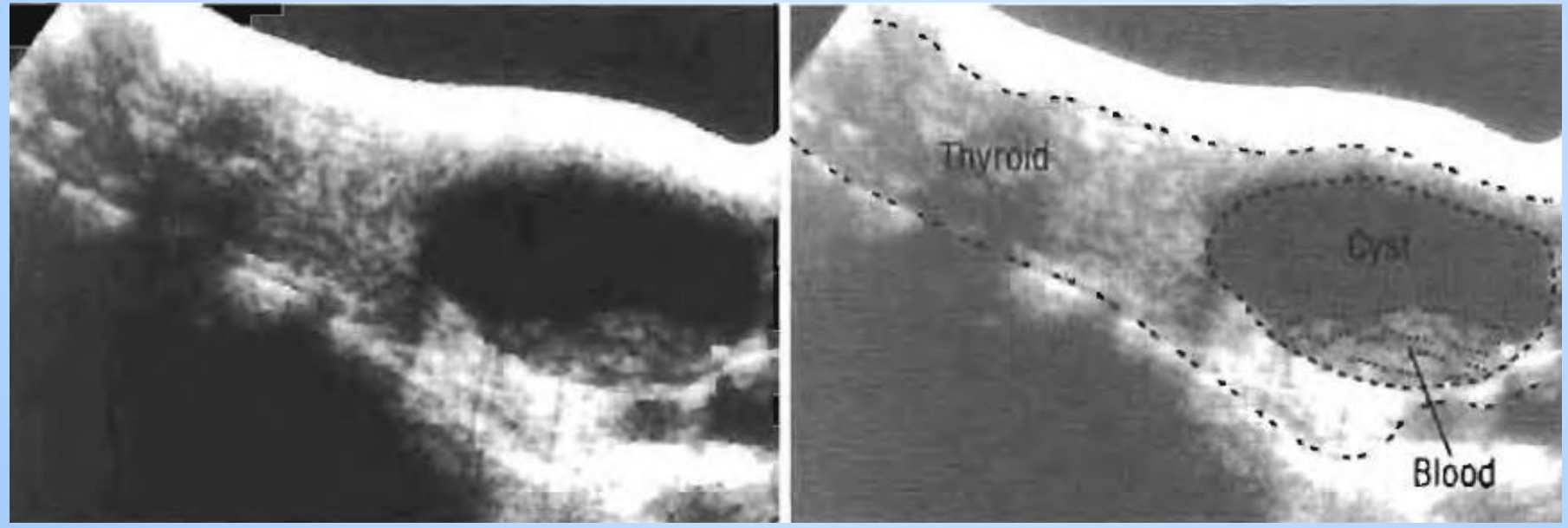

Longitudinal scan: a thyroid cyst partially filled with blood.

Abnormal thyroid



4. Calcification Ultrasound shows hyperechogenic areas with distal acoustic shadowing. Thyroid calcification is commonly seen in adenomas, but may occur in malignant tumours. The calcification can be isolated or in clusters, in groups or in chains. It is important to remember that the size of the thyroid nodule and the presence or absence of calcification are **not evidence** for or against malignancy.

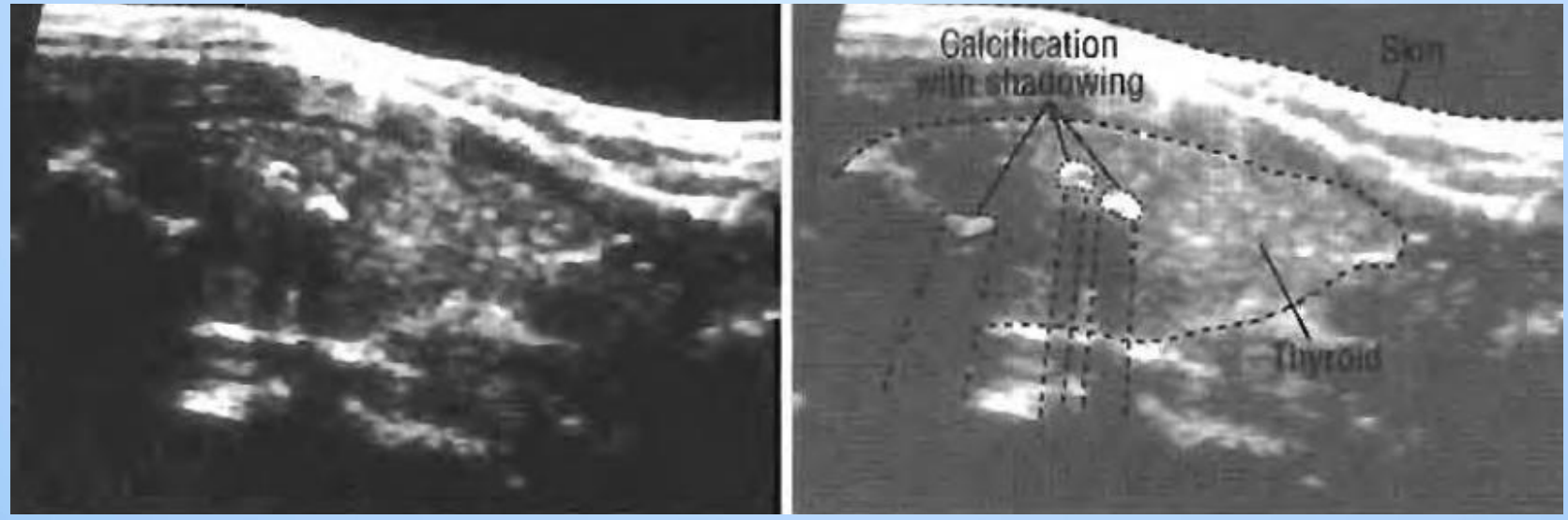

Longitudinal scan: calcification in the thyroid gland.

Diffuse thyroid lesions



- **Homogeneous enlargement** The thyroid may be enlarged, sometimes extending retrosternally. Enlargement may affect only part of a lobe, a whole lobe, the isthmus or both lobes. Enlargement is usually hyperplastic and is ultrasonically homogeneous. It may be due to endemicgoitre, lack of iodine, puberty, hyperthyroidism or hyperplasia following partial thyroidectomy. Asmall, homogeneous, hypochogenic thyroid may indicate acute thyroiditis.

Diffuse thyroid lesions



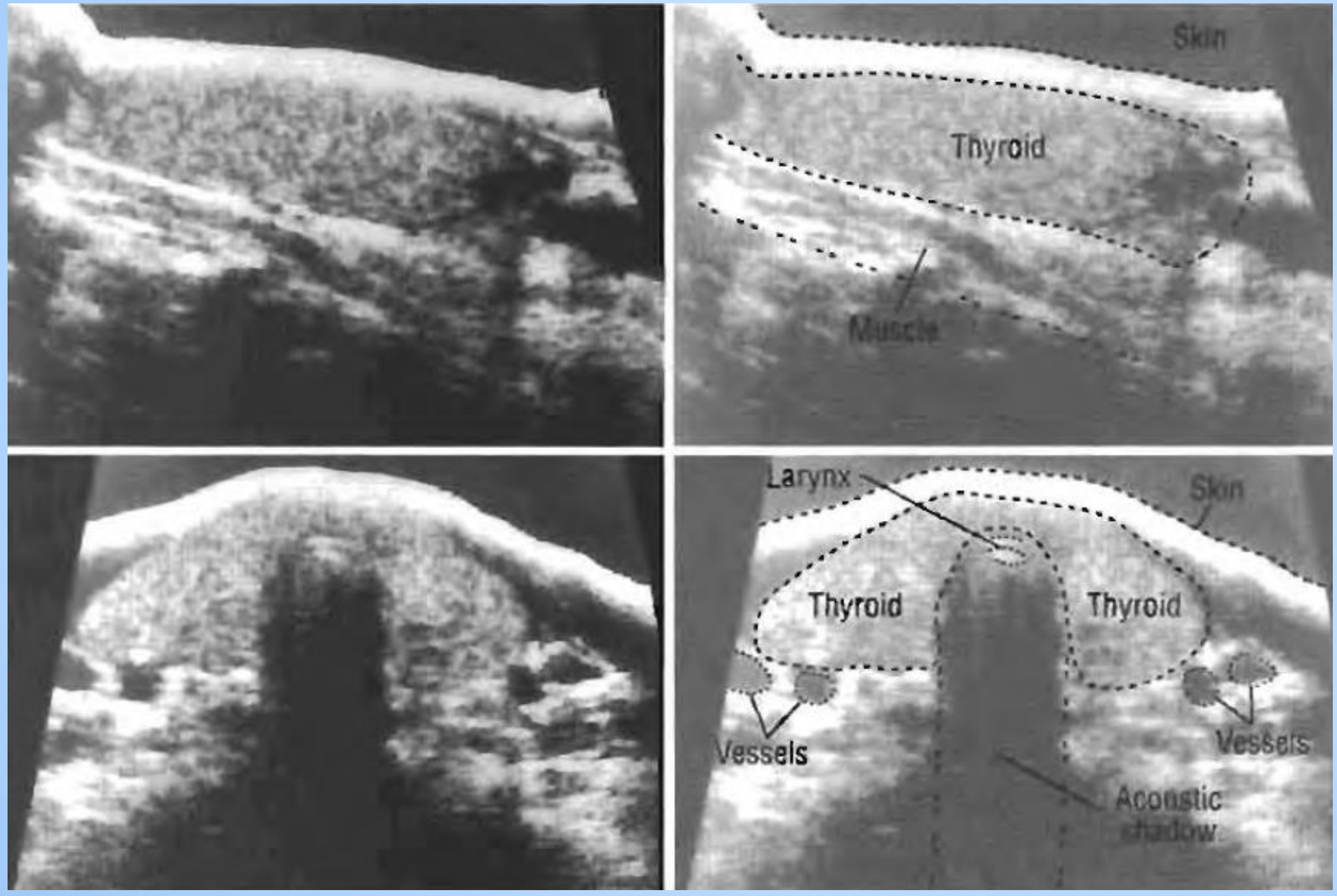

Longitudinal (upper) and transverse (lower) scans of homogeneous thyroid hyperplasia. The gland is hyperechogenic because of iodine deficiency.

Diffuse thyroid lesions



- **Heterogeneous enlargement** If the ultrasound density of the thyroid is heterogeneous, there are usually multiple nodules (a multinodular goitre); the nodules may be solid o rcomplex onultrasound. I nautoimmune thyroiditis, the thyroid becomes heterogeneous and may resemble a multinodular goitre.

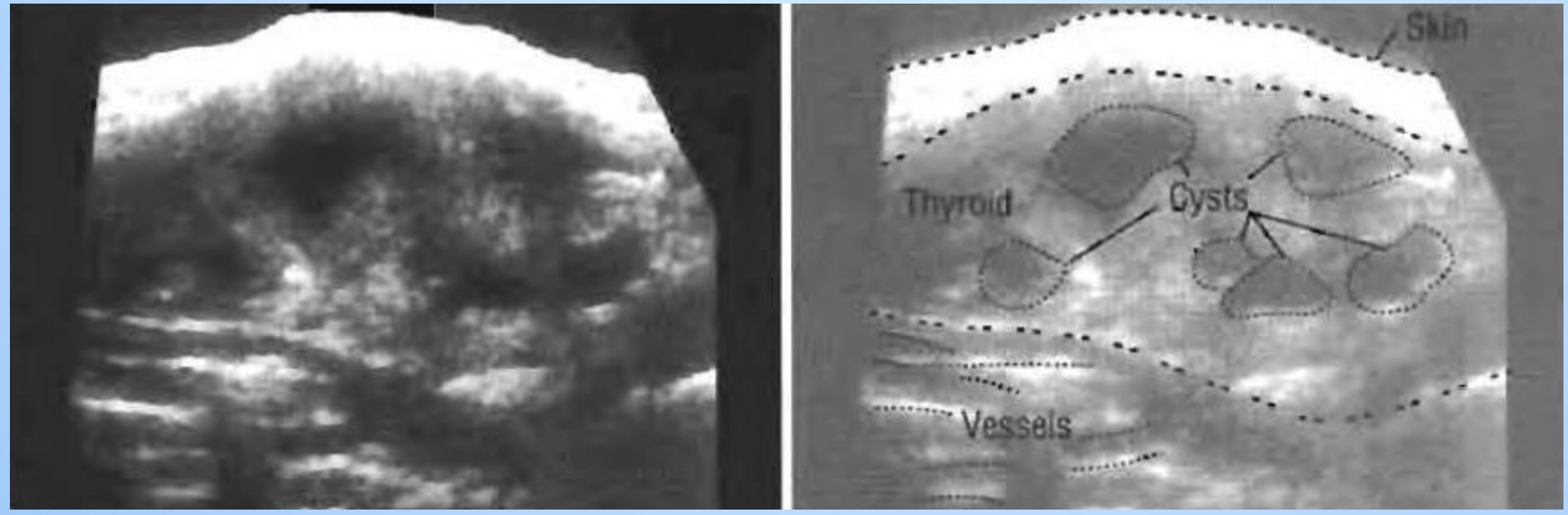

Heterogeneous enlarged thyroid with multiple nodules, some of which have undergone cystic degeneration.

Other masses in the neck



- **Abscess** The size and shape of a cervical abscess are very variable, and the outline is often very irregular and unclear. On ultrasound, there are usually internal echoes. In children, abscesses are most commonly in the retropharyngeal region.

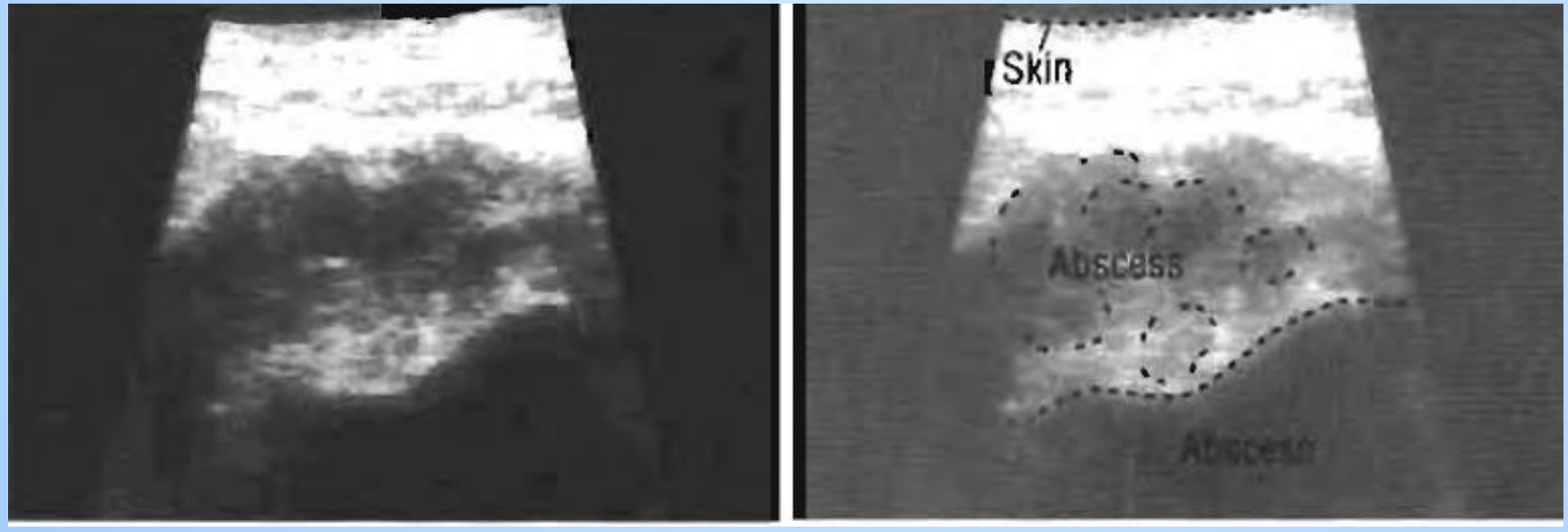

Longitudinal scan: a retropharyngeal abscess in a 4-year-old girl.

Other masses in the neck



- **Adenopathy** The diagnosis of enlarged lymph nodes in the neck is usually made clinically, but ultrasound is a satisfactory method of follow up. On ultrasound, lymph nodes will appear as hypoechogenic masses with regular outlines, solitary or multiple, nodular, oval or round, and variable in size from 1 cm upwards. Ultrasound cannot determine the cause of the lymph node enlargement.

Other masses in the neck



Adenopathy

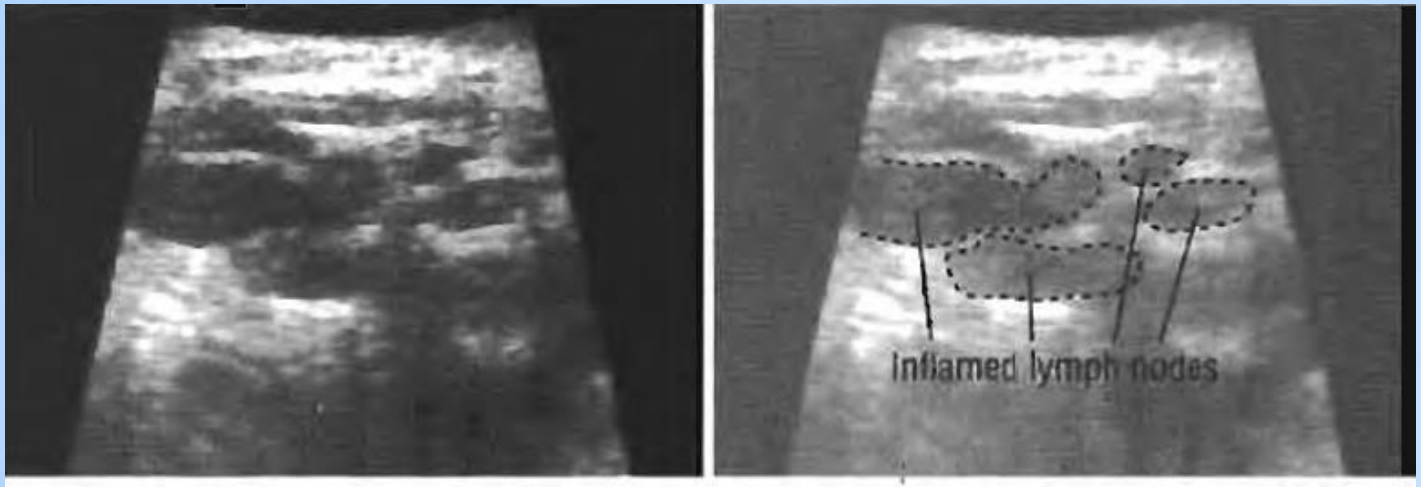

Multiple inflamed cervical lymph nodes.



Enlarged inflamed lymph nodes near the carotid artery.

Other masses in the neck



- **Cystic hygromas (lymphangiomas)** These are of variable size, are usually situated laterally in the neck, and may extend to the thorax or axilla. On ultrasound they are fluid filled, often with septa.

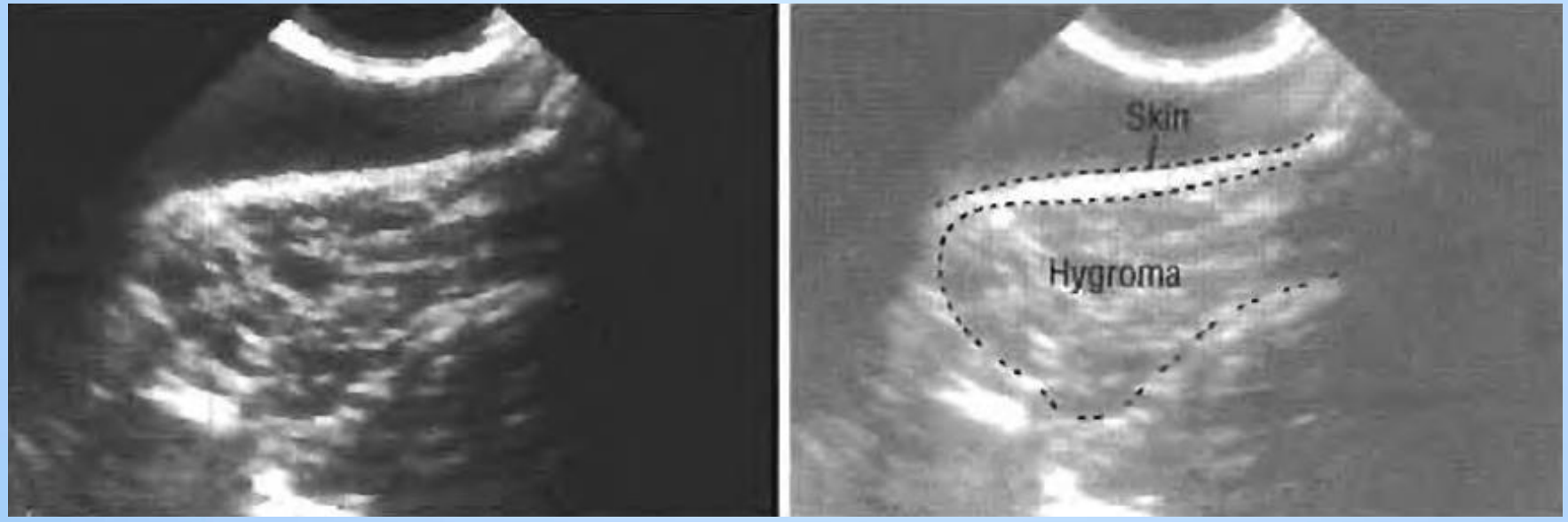

A cystic hygroma in the neck of a child, with multiple fluid-filled spaces

Other masses in the neck



Less common neck masses

In children, echogenic masses may be due to haematoma. In the cervical muscles, a cystic or complex mass may be a thyroglossal cyst (in the midline), a branchial cleft cyst (in the lateral neck) or a dermoid.

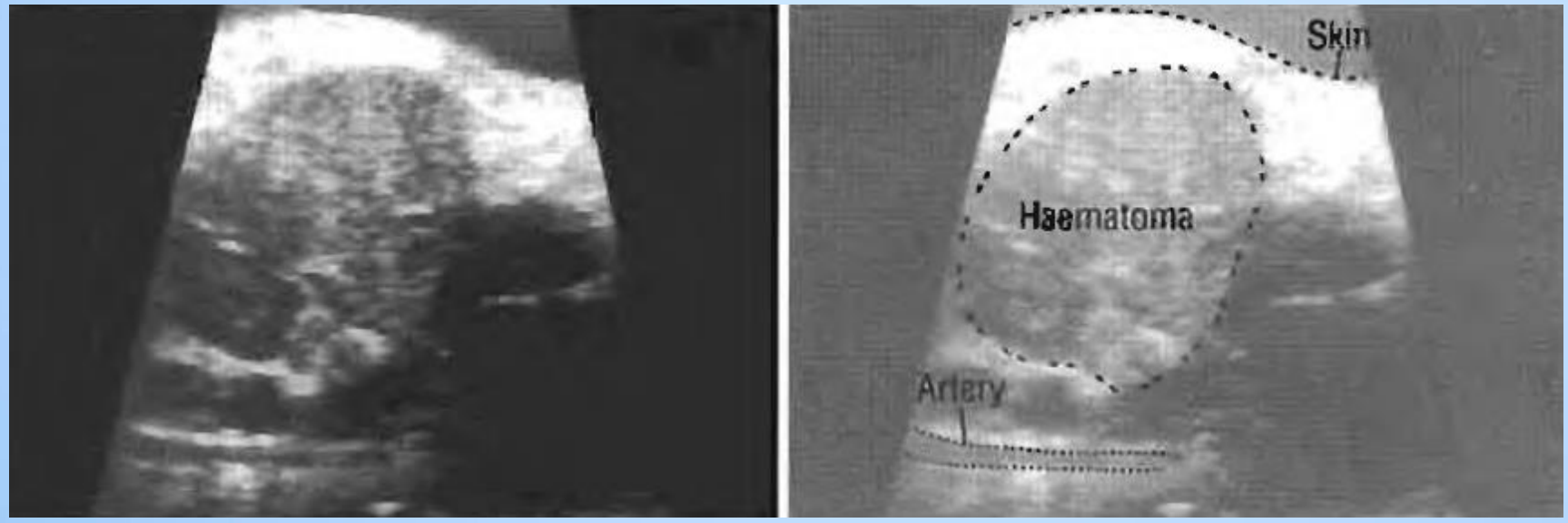

A haematoma in a child's neck

Vascular abnormalities



Vascular abnormalities

It is possible with ultrasound to demonstrate atheromatous plaques and show stenosis in the carotid artery, but it is not possible to evaluate blood flow without Doppler ultrasound and, in many cases, angiography.

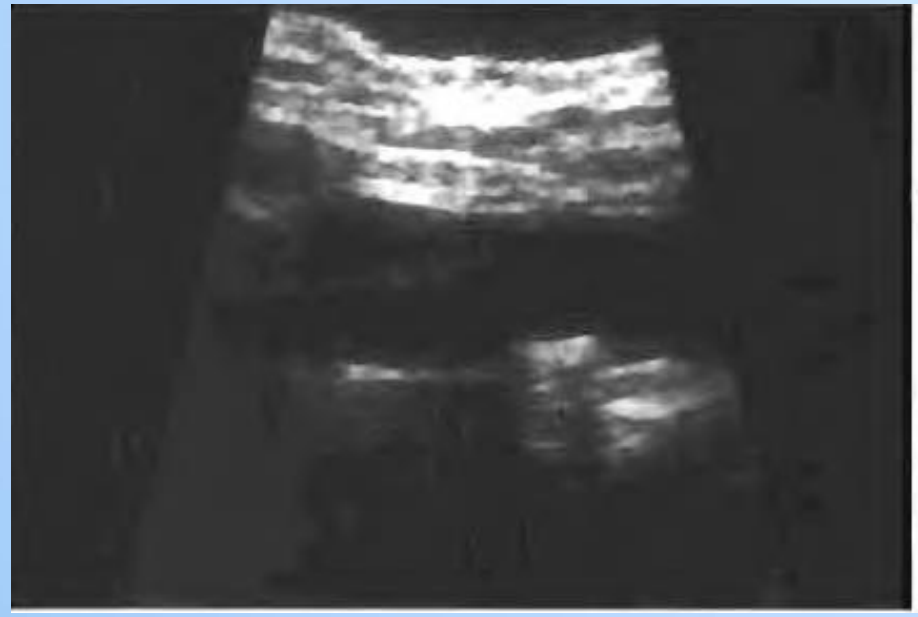

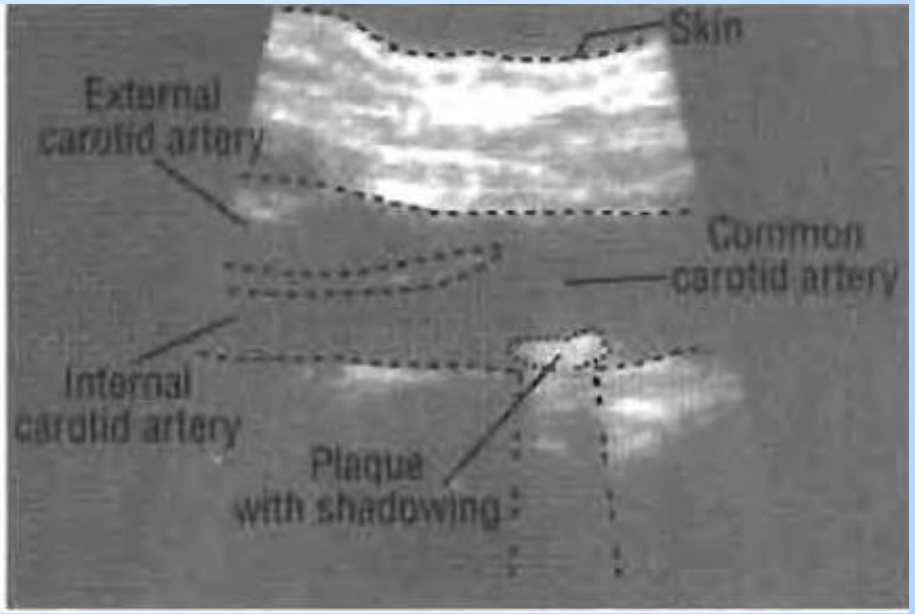

Longitudinal scan: a calcified atheromatous plaque just proximal to the bifurcation of the left common caroid artery.


Thank you