

Abnormal uterus

Dr.Hayder Jasim Taher

PhD of Medical Imaging



Outline of my presentation

- ✓ Abnormal uterus.
- ✓ Abnormal ovary.
- ✓ Pelvic inflammatory disease.
- ✓ Fluid in the pelvis (ascites).
- ✓ Pelvic abscess.
- ✓ Fallopian tubes.
- ✓ Pelvic varices
- ✓ Ectopic pregnancy

Abnormal uterus:



Uterine fibroids, also known as leiomyomas or myomas, are the commonest uterine neoplasms. They are benign tumors of smooth muscle origin, with varying amounts of fibrous connective tissue. Fibroids usually arise in the myometrium but may occasionally be found in the cervix, broad ligament or ovaries. They are multiple in up to 84% of women. Fibroids have been reported to occur in up to 70% of women by the age of 50 years and are especially common in black women, who also often have more severe disease. These benign tumors are hormone dependent, responding to both estrogen and progesterone; they often increase in size during pregnancy and usually decrease in size after menopause. Early age at menarche and obesity are risk factors for the development of fibroids, likely due to the increased exposure to estrogen.

The majority of women with fibroids are asymptomatic; however, 20–50% of them have symptoms such as menorrhagia, pelvic pain and infertility, or complications during pregnancy. A large fibroid can present as an abdominal mass or with symptoms secondary to mass effect, e.g., constipation and urinary frequency or retention. Rarely, the patient may present with hydronephrosis or bowel obstruction.

Abnormal uterus



Myomas (fibroids)

Myomas appear in various ways on ultrasound examination. Most will be seen as multiple, well defined, homogeneous, hypoechogenic, nodular masses, either subserosal, submucosal or interstitial. Older myomas become hyperechogenic and some will develop a complex echo pattern as a result of central necrosis. There may be bright echoes from calcification. Rapidly growing myomas, as may occur in pregnancy, may simulate hypoechogenic cysts. Multiple projections are needed to differentiate between myomas and tubo-ovarian masses. Some myomas are pedunculated. Uterine myomas can indent the posterior wall of the bladder

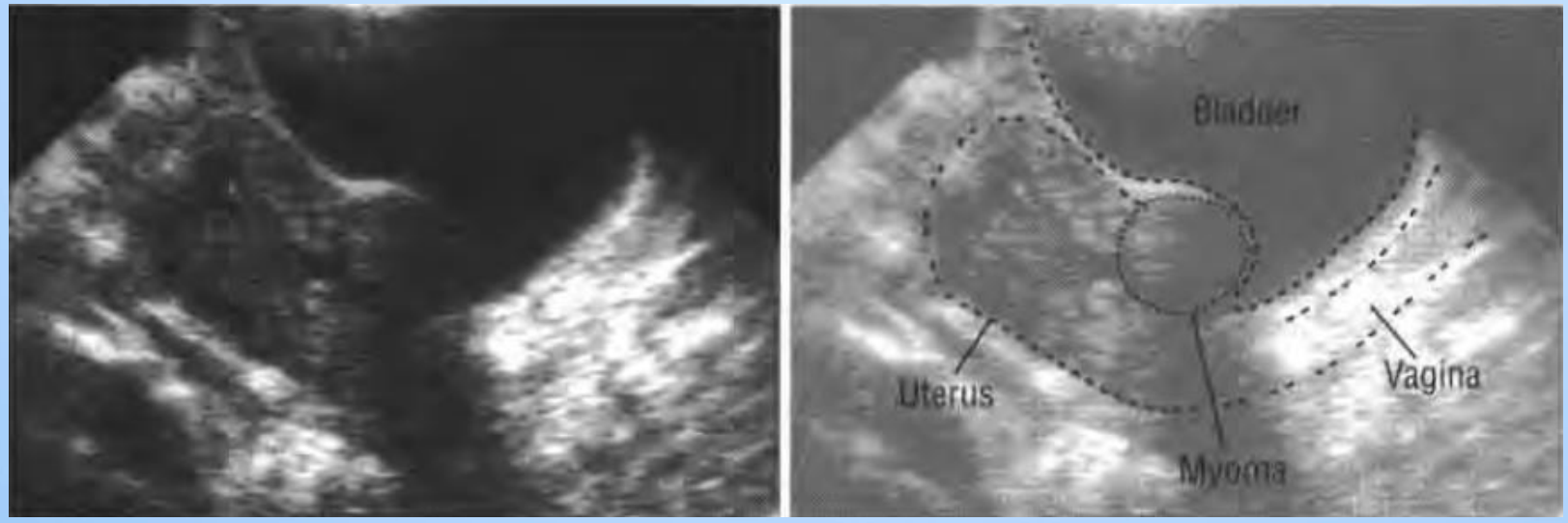

Longitudinal scan: a uterine myoma elevating the posterior wall of the bladder.

Abnormal uterus



Myomas may also contain calcium, which can present as hyperechogenic structures with distal shadowing. Myomas are almost always multiple and frequently distort the normal contours and the endometrial canal of the uterus.
Myomas can also originate in the cervical part of the uterus and may cause distortion or blockage of the cervical canal.



Longitudinal (left) and transverse (right) scans: a uterine myoma with peripheral calcification.

Abnormal uterus



The endometrium (lining of the uterus)

The normal pattern varies with the stage of the menstrual cycle. In the secretory phase (at the beginning of the cycle) the endometrium appears thin and hypoechogenic. In the proliferative phase (mid-cycle) the central part of the endometrium becomes hyperechogenic and is surrounded by a hypoechogenic rim. During the menstrual phase the endometrial cavity becomes totally hyperechogenic and thickened owing to sloughing endometrial tissue and blood clots.

The endometrial canal may be filled with pus from infection (pyometria) This will appear hypoechogenic with internal echoes. Fluid resulting from infection may also collect in the fallopian tubes (hydrosalpinx) and may spread to the cul-de-sac.



Longitudinal scan: the uterine endometrium at the proliferative mid-cycle phase.

Abnormal uterus



Malignant disease

A poorly defined mass within the uterus may be malignant and is usually an endometrial carcinoma. The endometrium becomes hyperplastic and the hypoechogenic tumour may spread into the myometrium. When the tumour is advanced, there may be necrosis, resulting in a complex ultrasound pattern: there may be distension of the endometrial cavity of the uterus.

Early carcinoma of the cervix is very difficult to recognize with ultrasound. Any ill-defined mass in the cervix is likely to be malignant (most myomas are well defined and the bright echoes of calcification may be seen). If the tumour is large, the echo pattern will be complex and very varied .



Longitudinal scan: an extensive choriocarcinoma, which was detected 14 months after a normal pregnancy and now distorts the uterus.

Abnormal uterus



Uterine endometriosis

Hypoechogenic spaces in the myometrium near the endometrium may represent adenomyosis (uterine endometriosis). The spaces will be more prominent during and immediately after menstruation. Small retention cysts (follicles) in the uterine cervix, close to the canal, should not be mistaken for endometriosis.

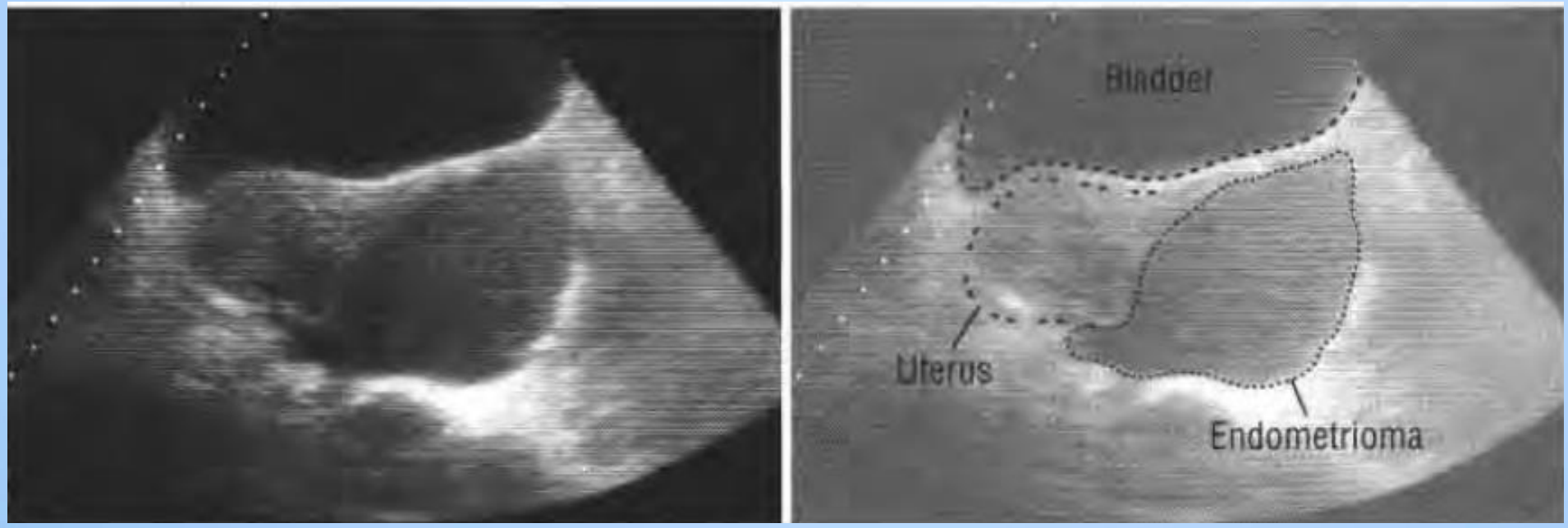

Transverse scan: endometrioma.

Ovarian cysts



Ultrasonography (US) is the primary imaging modality for identifying and characterizing ovarian masses. US is a relatively simple and noninvasive diagnostic method that provides clinicians with useful information relevant for determining the optimal management strategy for a given patient. Lots of data have demonstrated that US can accurately characterize about 90% of adnexal masses and the reported sensitivity and specificity of US for detecting ovarian malignancies is 88%-96% and 90%-96%, respectively.

The normal ovary is slightly less echogenic than the uterus and less homogeneous because of the presence of small follicles. Identification in postmenopausal women can be difficult, particularly after the age of 50.

Ovarian cysts



A follicle is a physiological ovarian cyst which normally disappears during the second half of the menstrual cycle . If the follicle fails to rupture in mid-cycle, it will become a follicular cyst, which is one cause of ovarian cysts; these may be over 3 cm in diameter. Immediately after rupture there may be a little fluid in the cul-de-sac .

A simple cyst has smooth walls, no internal echoes, good distal wall enhancement and is almost always benign . Vestigial embryonic structures in the pelvis can give rise to simple cysts.

Small or medium-sized ovarian cysts lying behind the uterus or bladder cannot be seen easily. particularly if the bladder is only partly filled. Large ovarian cysts often lie above the uterine fundus when the bladder is full. and may cause distortion of the bladder by external pressure. A very large cystic mass may be mistaken for the urinary bladder: both should be identified .

Ovarian cysts



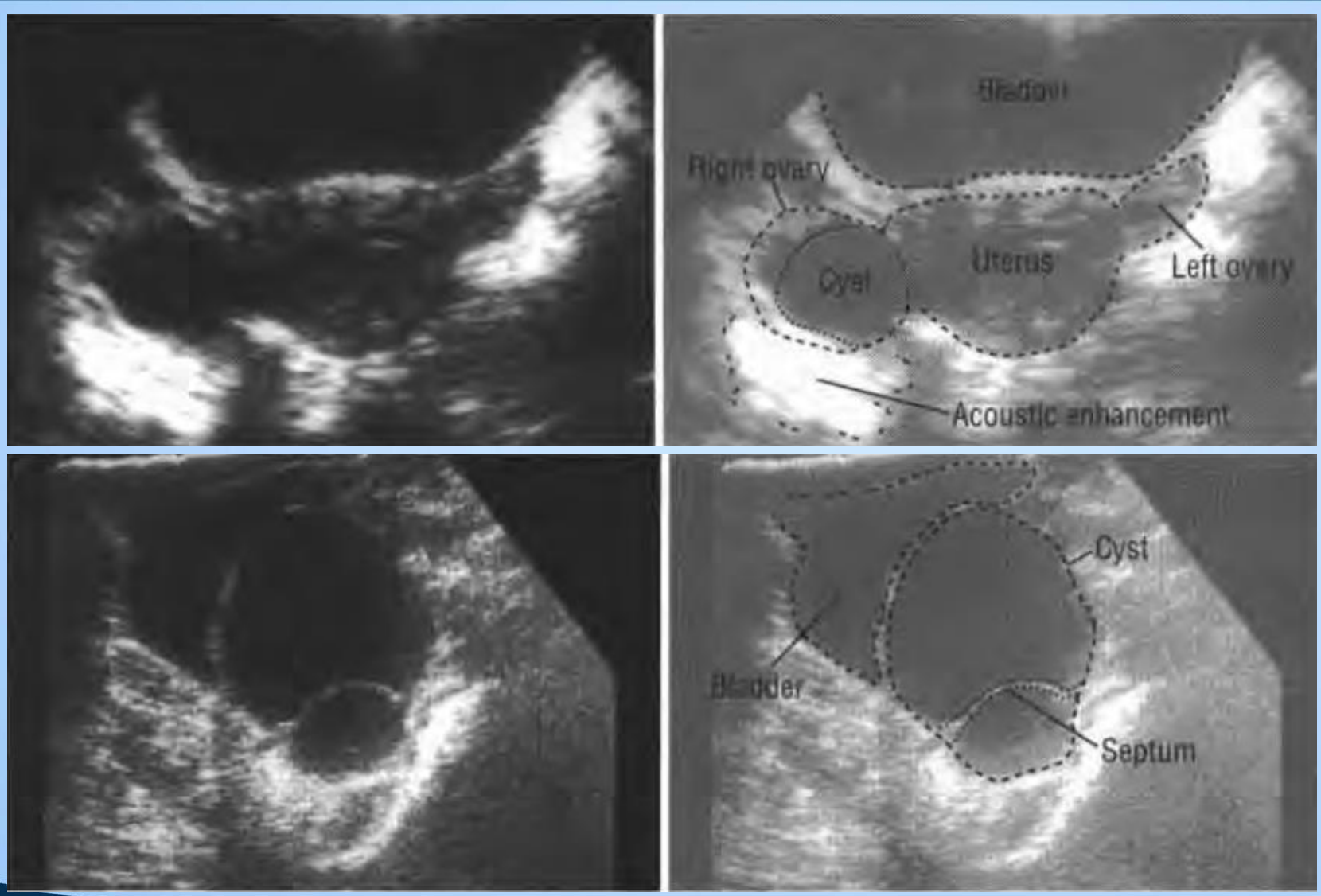

Transverse scan: an ovarian cyst with smooth walls.

Longitudinal scan: a septate ovarian cyst distorting the bladder.

Follicular cysts



The development of physiological follicles is a normal function of the ovary. Follicular cysts occur as aresult of failure of ovulation, or failure of involution of a mature follicle. They are commonly seen at ultrasound, although their true incidence is unknown, as they are often asymptomatic. Most follicles are small, but as they mature can reach sizes of 2.5 - 3.0 cm. The term follicular cyst should therefore be reserved for cystic structures greater than this size, which can become as large as 20 cm.

The typical appearance is of a unilocular cyst with no internal echoes, a thin smooth wall, and posterior acoustic enhancement. Follicular cysts are often detected incidentally and usually regress spontaneously.

Corpus luteal cysts



Following ovulation, the corpus luteum forms from the ovulatory follicle. Corpus luteal cysts result from failure of involution of the corpus luteum. They are prone to haemorrhage and rupture, tending to be more symptomatic than follicular cysts, and patients often present with pain. Complex luteal cysts can mimic malignant lesions and follow up may be required to ensure resolution.

Haemorrhagic cysts



Haemorrhage may occur in both types of functional cyst, although it is more common with corpus luteal cysts. Haemorrhagic cysts have a variety of appearances at ultrasound, related to the changes in blood products with time. These include clot formation, retraction and lysis. Acute haemorrhage may be purely echogenic and can sometimes appear as a solid mass, although the presence of posterior acoustic enhancement helps to confirm the cystic nature of the lesion.

As the haemorrhage evolves it tends to develop a reticular appearance or a fine network of interfaces, which are thought to correspond to fibrin strands. Fluid levels may be seen due to layering of the blood products. With further organisation, solid areas of clot may be seen which later show retraction.

Haemorrhagic cysts



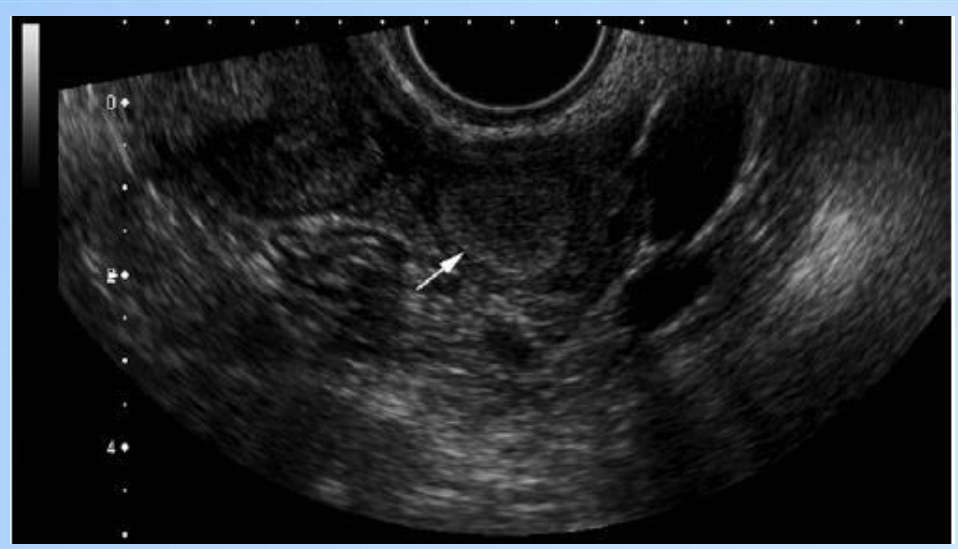

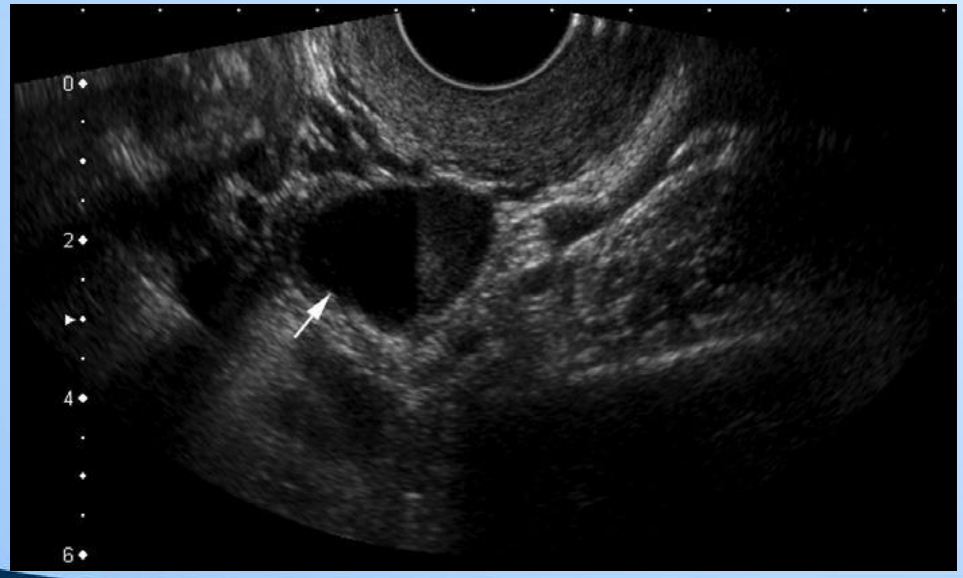

Haemorrhage. Transvaginal ultrasound image of an ovary containing an area of increased echogenicity (arrow), consistent with haemorrhage, which resolved on follow-up imaging.

Haemorrhagic cyst (arrow) with a fluid level. The hyperechoic component layers inferiorly as opposed to a dermoid where the hyperechoic component tends to be located superiorly.

Dermoid cysts



Dermoid cysts (cystic teratomas) appear as solid or complex masses with areas of acoustic shadowing due to calcification in bone or teeth If there is any doubt, X-ray the pelvis.

On ultrasound, ovarian cysts can appear cystic or almost solid or complex with internal echoes from haemorrhage, nodules or septations. Complex cysts have strong back wall enhancement and variable internal patterns and are more likely to be malignant.

Pelvic echinococcal (hydatid) cysts



Hydatid cysts are of different sizes, often multiple and in almost any position; some have

internal septa. If echinococcosis is suspected, scan the liver and X ray the chest for other cysts.

Solid ovarian masses



Solid masses are rare and have often undergone necrosis or internal haemorrhage by the time they can be recognized ultrasonically. Solid ovarian masses may be confused with pedunculated fibroids and a careful search for a uterine connection should be made .

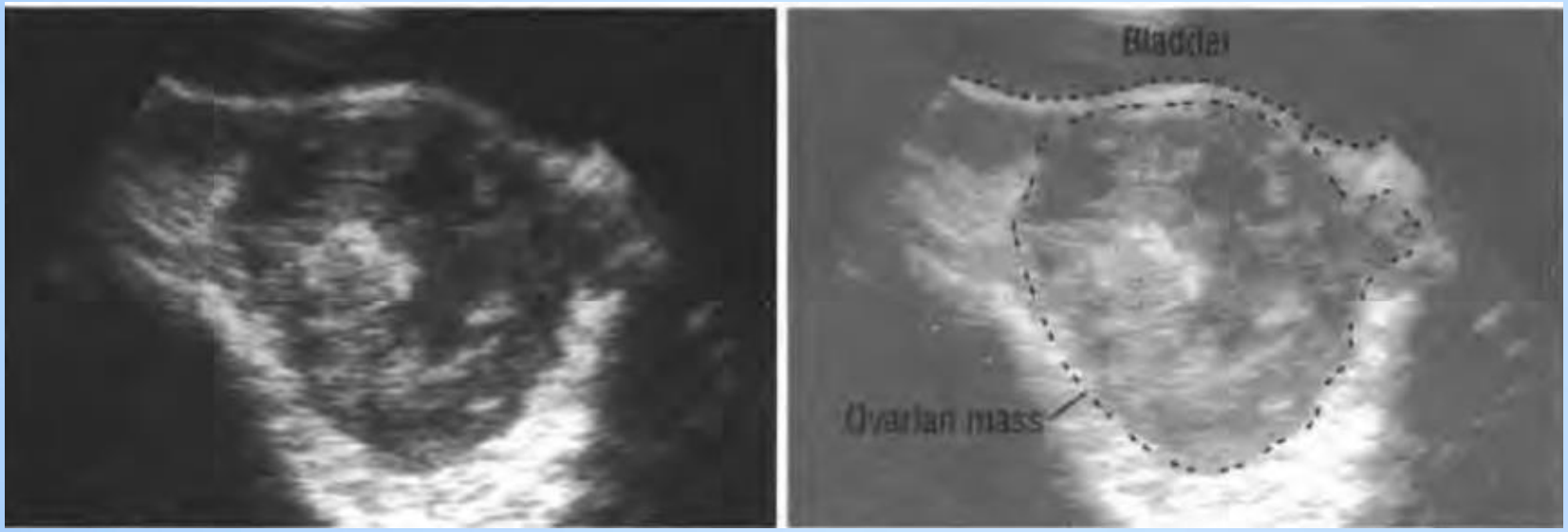

Transverse scan: a large, solid, non-homogeneous ovarian mass elevating the posterior wall of the bladder.

Cystic masses in the pelvis of postmenopausal women are probably malignant.

Pelvic inflammatory disease



In pelvic inflammatory disease, there may be adhesions, distortion of the tissues, displacement of the uterus or ovaries, flxation, and changes in the echogenicity of the parametrial tissues. However, ultrasound may be normal and clinical examination may be more accurate. Pelvic tuberculosis cannot be distinguished from other inflammatory processes. A mass may be an endometrioma, abscess or ectopic pregnancy; exact localization may be difficult less.

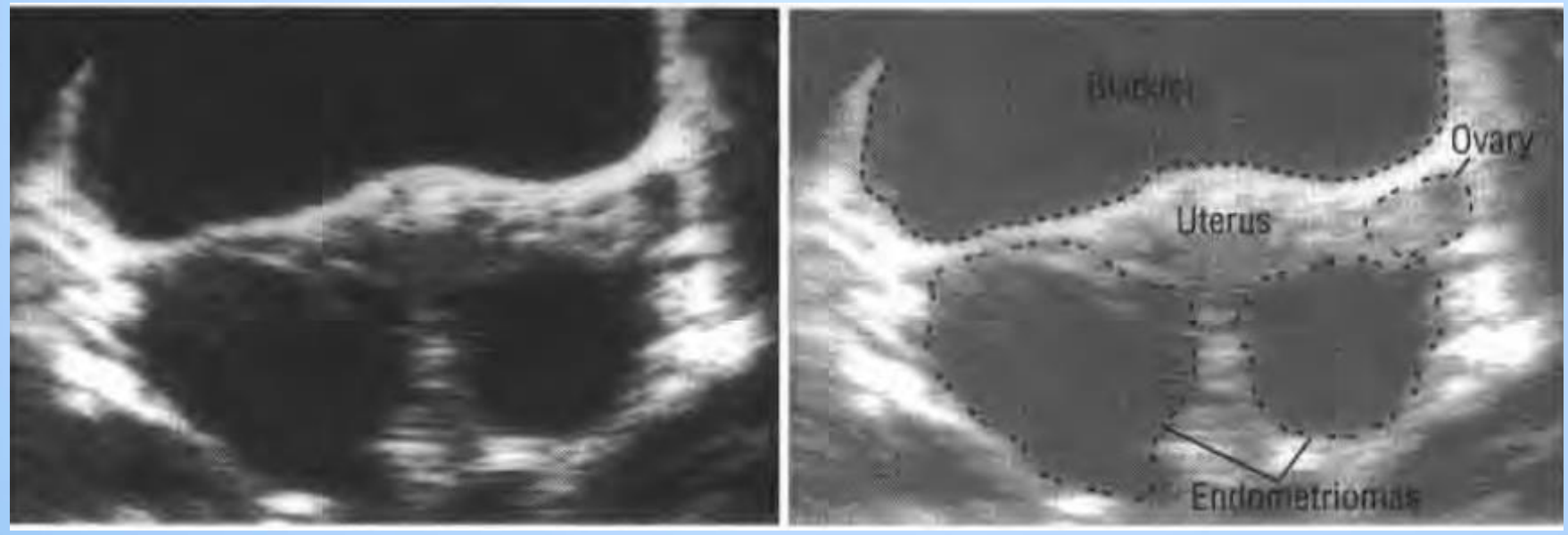

Transverse scan: bilateral, predominantly cystic, endometriomas.

Fluid in the pelvis (ascites)



If there is excess fluid, suspect ascites, blood, pus or the contents of a ruptured cyst. Multiple projections will help assessment.
The fluid may be echo-free or produce internal echoes as aresult of debris. Fluid collections may also be found in the vagina and in the endometrial canal .

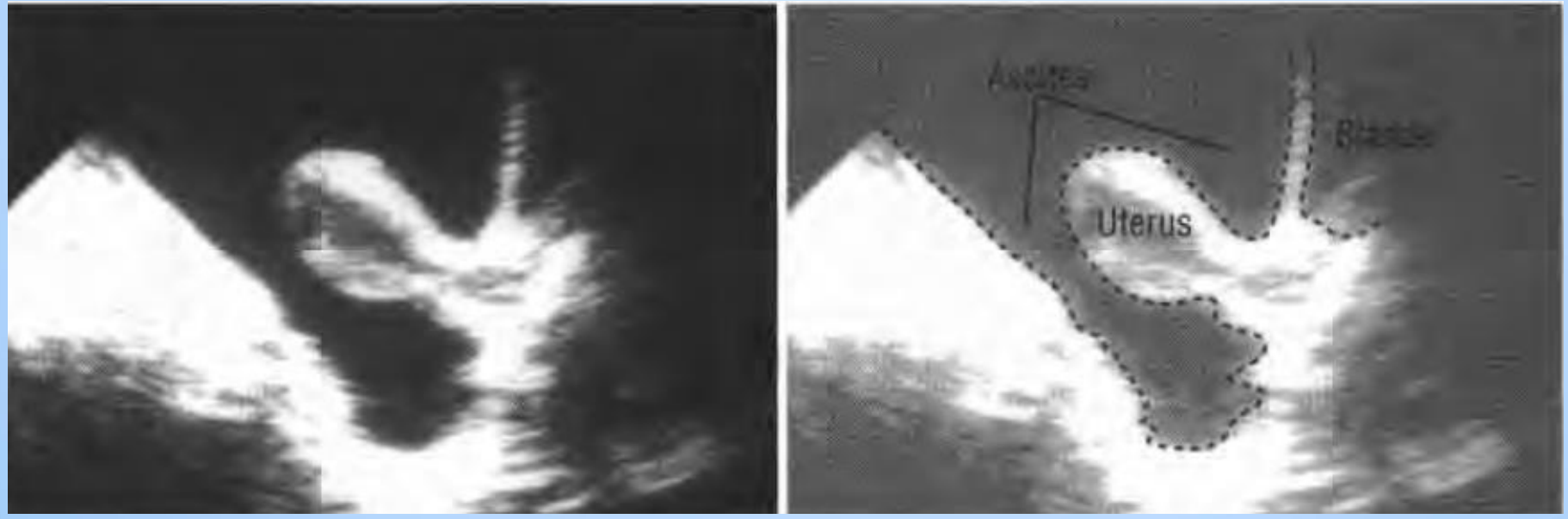

Longitudinal scan: the uterus appears to be floating in peritoneal fluid (ascites).

Pelvic abscess



Any localized, complex pelvic mass may be inflammatory, but pyogenic and tuberculous infections look the same. It is often impossible to be sure of the exact location or etiology of an inflammatory mass: clinical examination is very important .

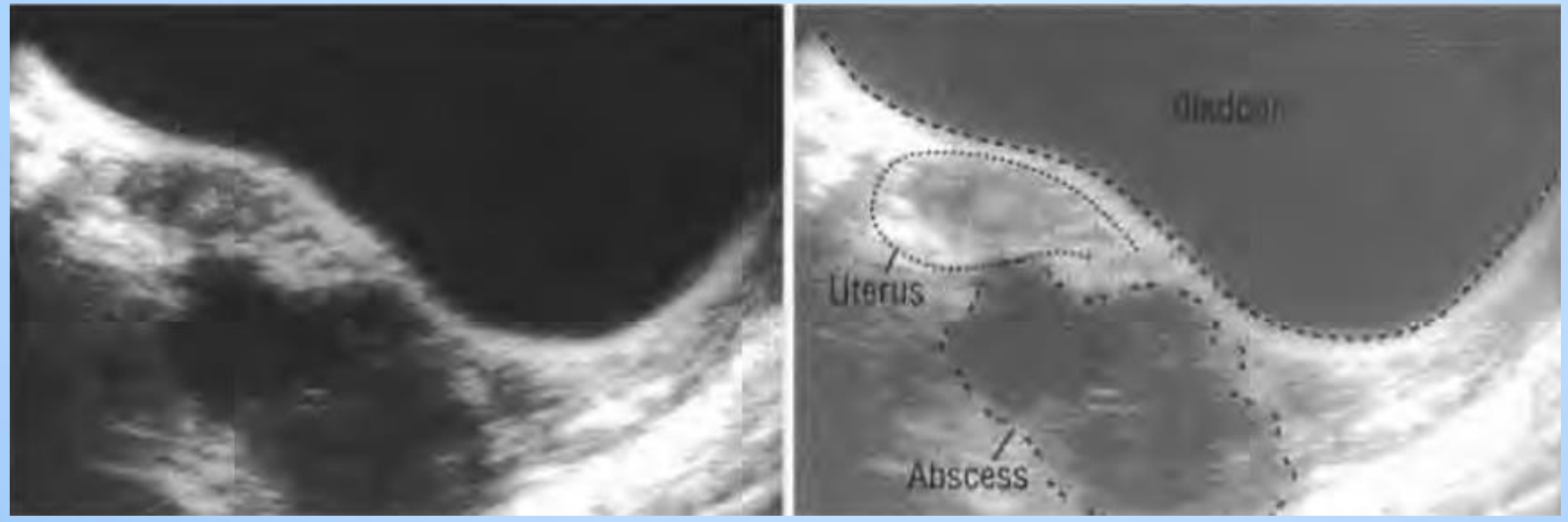

Longitudinal scan: the same pelvic abscess lying partly behind the uterus.

Fallopian tubes



It is not easy to demonstrate a normal fallopian tube with ultrasound. The fallopian tubes vary in both size and position, and it is difficult to be sure that there is an abnormality unless there is a significant local change, for example, partial enlargement of one tube. If the tubes are fluid-filled, it may be difficult to differentiate bowel, but bowel shows peristalsis whereas the fallopian tubes will not alter significantly over a period of a few hours. Tubal obstruction cannot be recognized with ultrasound unless there is tubal swelling above it.

Enlargement of part of one fallopian tube may be due to an ectopic pregnancy which will cause a tubular, fluid-filled, echo-free (or mixed) mass near to the uterus. However, any pyosalpinx (tuberculous or pyogenic) will appear very similar. Clinical signs are the only way to differentiate a hydrosalpinx from a pyosalpinx .

Pelvic varices



Dilated pelvic veins can be painful, particularly in the premenstrual phase. Ultrasound will demonstrate multiple echo-free, tubular structures around the uterus and occasionally between the uterus and the bladder. There may be only a single dilated vein, which may be mistaken for a hydrosalpinx. Differentiation can be made by examining the patient tilted head downwards. A dilated vein will empty in this position, whereas a hydrosalpinx will not change.

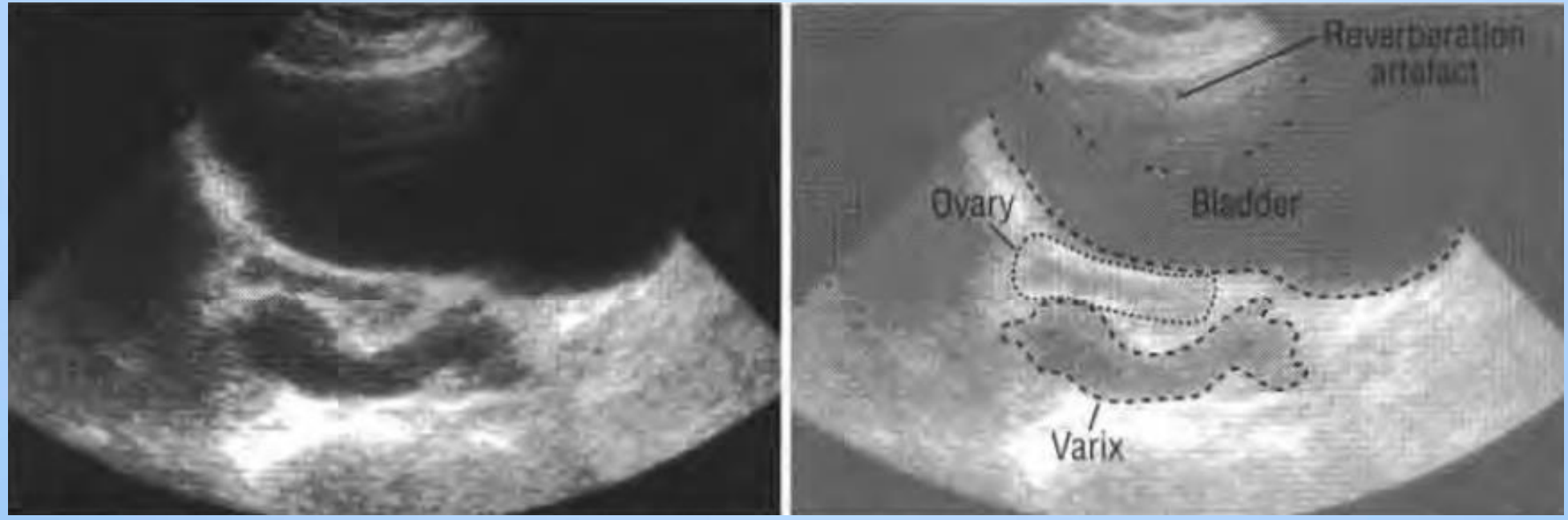

Ectopic pregnancy



A pelvic mass in a woman of childbearing age may be an ectopic pregnancy. Although ultrasound may be useful, it is not an entirely reliable method of diagnosing ectopic pregnancy. It is sometimes possible to demonstrate the ectopic sac and an embryo , but more commonly there is pooled blood in the pelvic cul-de-sac and an enlarged fluid-filled fallopian tube.

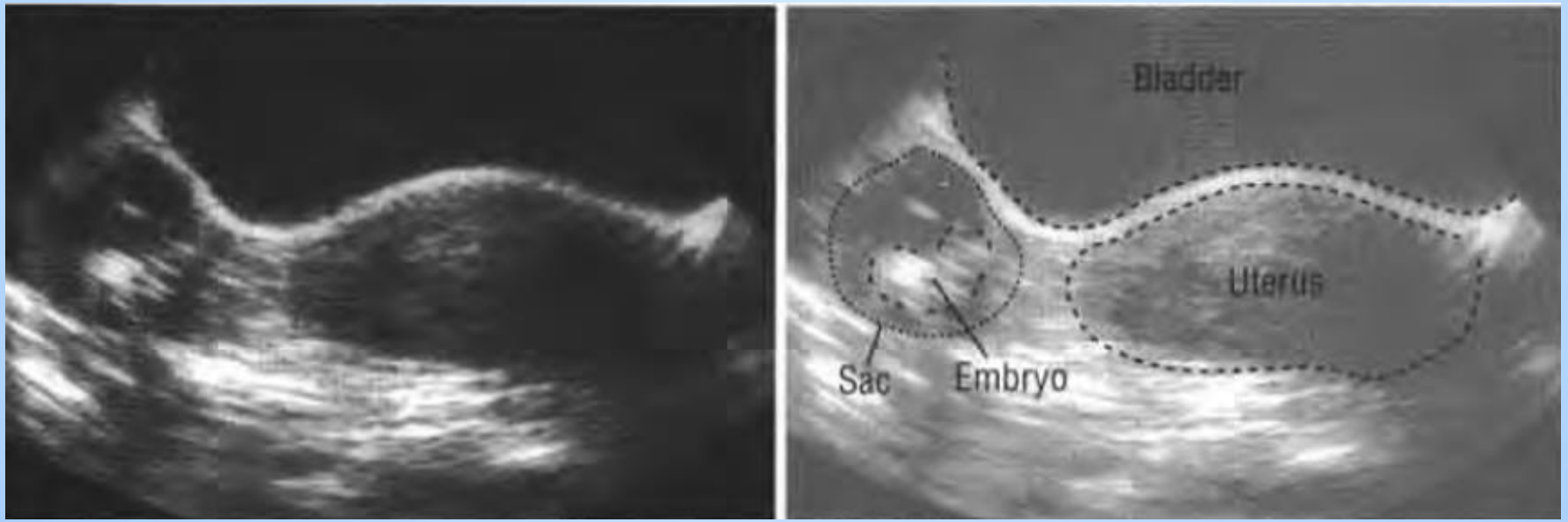

Transverse scan of an ectopic pregnancy, showing a small embryo. Movement of the embryo's heart could be seen.


Thank you