

Basics of ultrasound

Hayder Jasim Taher

PhD of Medical Imaging



Outline of my presentation

- ✓ What is ultrasound?
- ✓ Ultrasound generators.
- ✓ Different modes of ultrasound.
- ✓ Doppler ultrasound.
- ✓ Wave propagation.
  - ✓ Focusing
  - ✓ Attenuation
  - ✓ Amplification
  - ✓ Boundaries
- ✓ Transducers (scanning probes)

What is ultrasound?



- **Ultrasound** is the name given to high-frequency sound waves, over 20000 cycles per second (20 kHz). These waves, inaudible to humans, can be transmitted in beams and are used to scan the tissues of the body.
- The technique is similar to the echolocation used by bats, whales and dolphins, as well as SONAR used by submarines etc.
- **SONAR**: **So**und **N**avaigation **A**nd **R**anging



Ultrasound generators



- The ultrasound waves are generated by a piezoelectric transducer which is capable of changing electrical signals into mechanical (ultrasound) waves.
- The same transducer can also receive the reflected ultrasound and change it back into electrical Signals. Transducers are both transmitters and receivers of ultrasound.

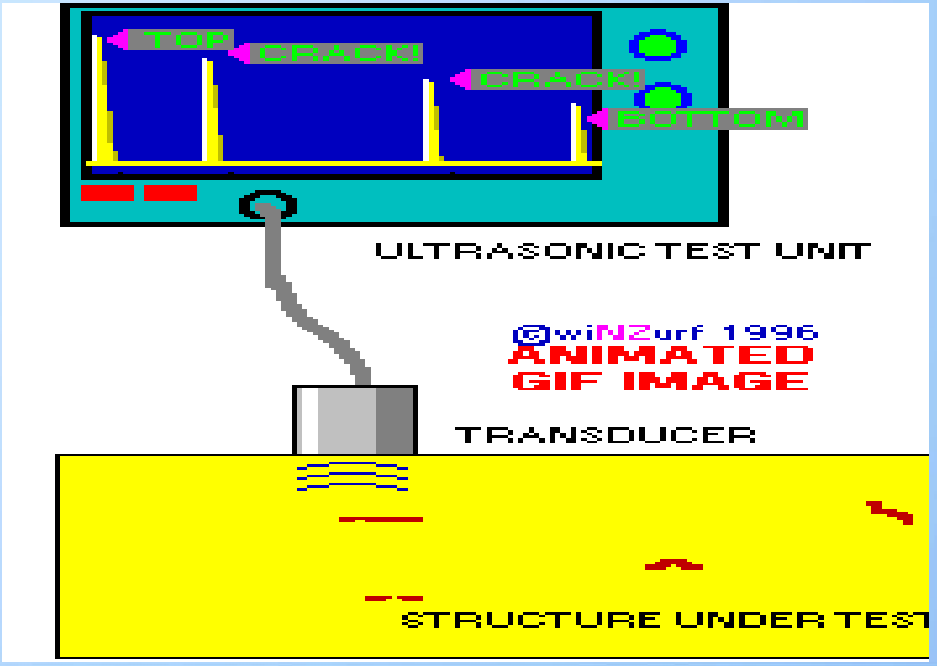

Different modes of ultrasound



- **GREY SCALE IMAGING**
  - A-Mode
  - B-Mode
  - Real-time.
  - M-Mode
- **DOPPLER IMAGING**

Different modes of ultrasound



The various modes show the returning echoes in different ways.

1. A-mode. With this type of ultrasound unit, the echoes are shown as peaks, and the distances between the various structures can be measured .

This pattern is not usually displayed but similar information is used to build the two-dimensional B-mode image.

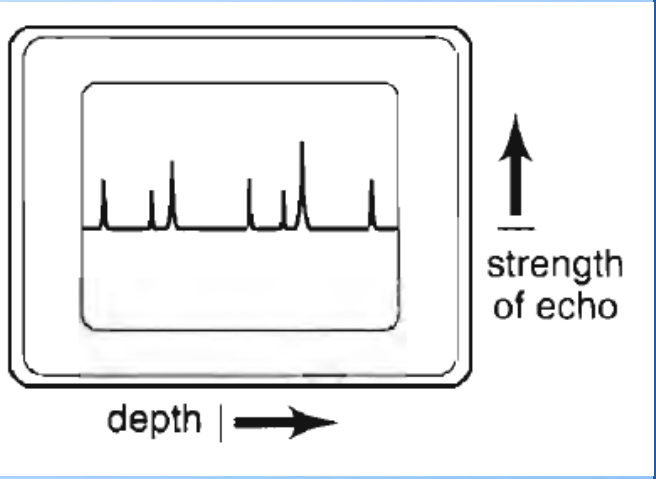

Different modes of ultrasound



2. B-mode. This type of image shows all the tissue traversed by the ultrasound scan.

The images are two-dimensional and are known as B-mode images or B-mode sections .If multiple B-mode images are watched in rapid sequence, they become real-time images.

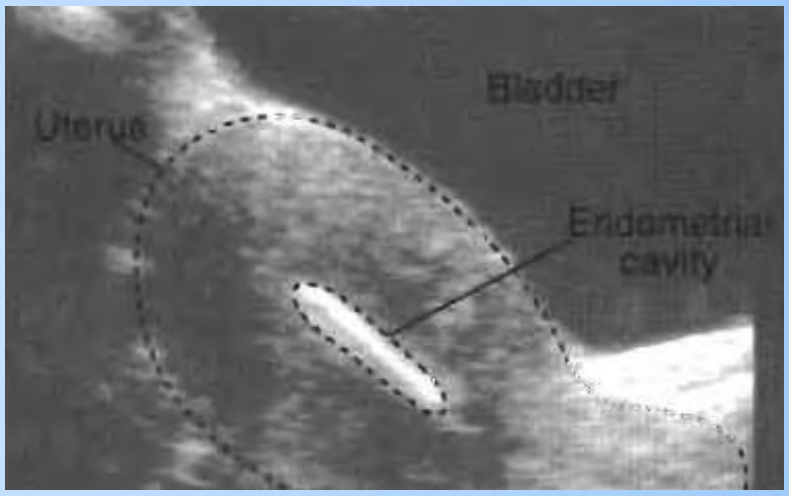

Different modes of ultrasound



3. Real-time. This mode displays motion by showing the images of the part of the body under the transducer as it is being scanned.

The images change with each movement of the transducer or if any part of the body is moving (for example, a moving fetus or pulsating artery).

The movement is shown on the monitor in real time, as it occurs. In most real-time units, it is possible to "freeze" the displayed image, holding it stationary so that it can be studied and measured if necessary.

Different modes of ultrasound



4. M-mode is another way of displaying motion. The result is a wavy line. This mode is most commonly used for cardiac ultrasound

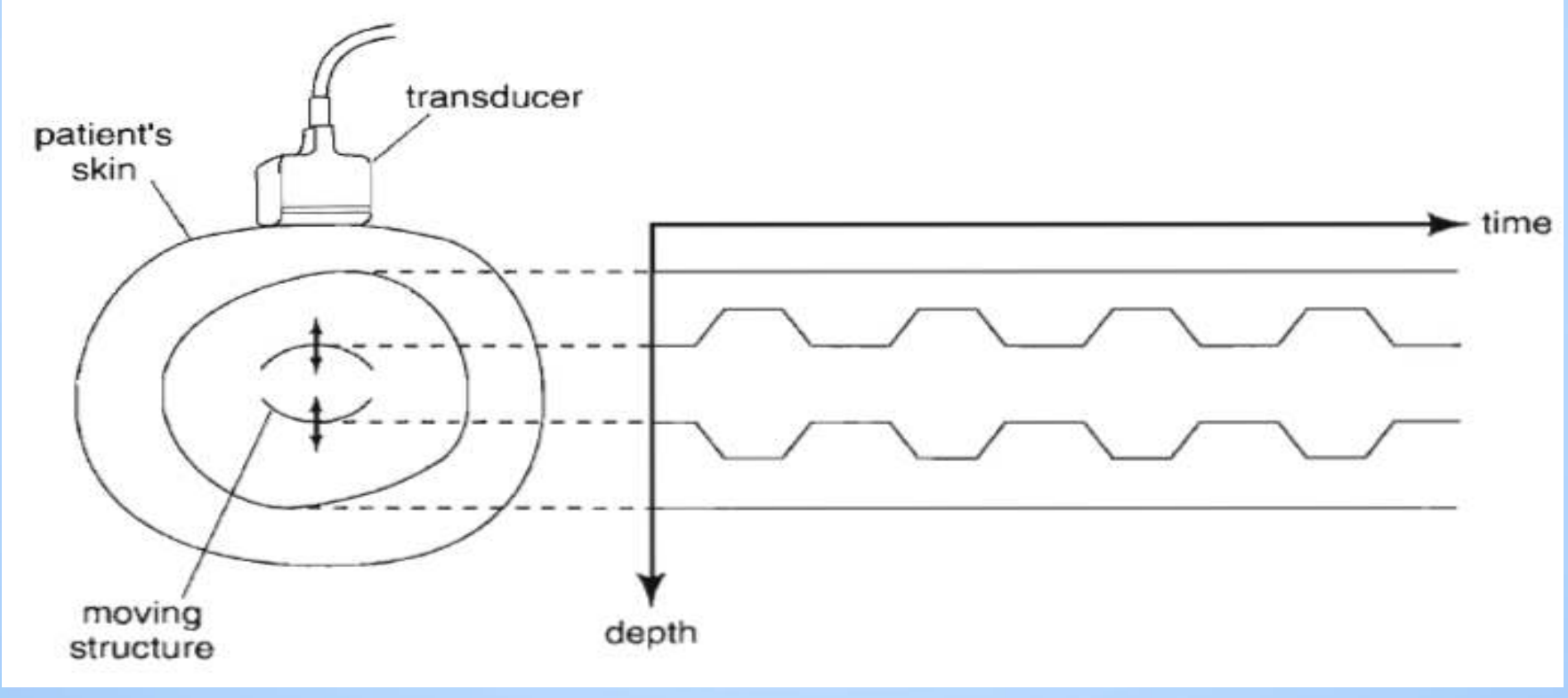

Different modes of ultrasound



Doppler ultrasound

- Doppler ultrasound evaluates blood velocity as it flows through a blood vessel.
- Blood flow through the heart and large vessels has certain characteristics that can be measured using Doppler instruments.



Doppler Effect



- Apparent change in received frequency due to a relative motion between a sound source and sound receiver
- Sound TOWARD receiver = increased frequency
- Sound AWAY from receiver = decreased frequency

Doppler Effect



Doppler equation

$$\Delta F = 2 F_0 V \cos \Theta / C$$

ΔF	Doppler shift frequency (kHz)
F_0	Ultrasound transmission frequency (MHz)
V	Blood cell velocity (cm/sec)
$\cos \Theta$	Cos of angle between US & flow direction
C	Speed of sound in soft tissue (1 540 m/sec)



Summary

A-mode:	peaks and distances. Not often used.
B-mode:	two-dimensional images in which the echo amplitude is depicted as dots of different brightness.
Real time:	shows movement as it occurs.
M-mode:	shows movement as a function of time. Used in cardiac scanning.
Doppler:	demonstrates and measures blood flow.
Colour Doppler:	shows different flow-velocities in different colours.

Wave propagation



Wave propagation describes the transmission and spread of ultrasound waves to different tissues. The differences in the ways in which ultrasound interacts with tissues influence the design of an ultrasound unit, affect the interpretation of the images and impose limitations on the usefulness of the method.

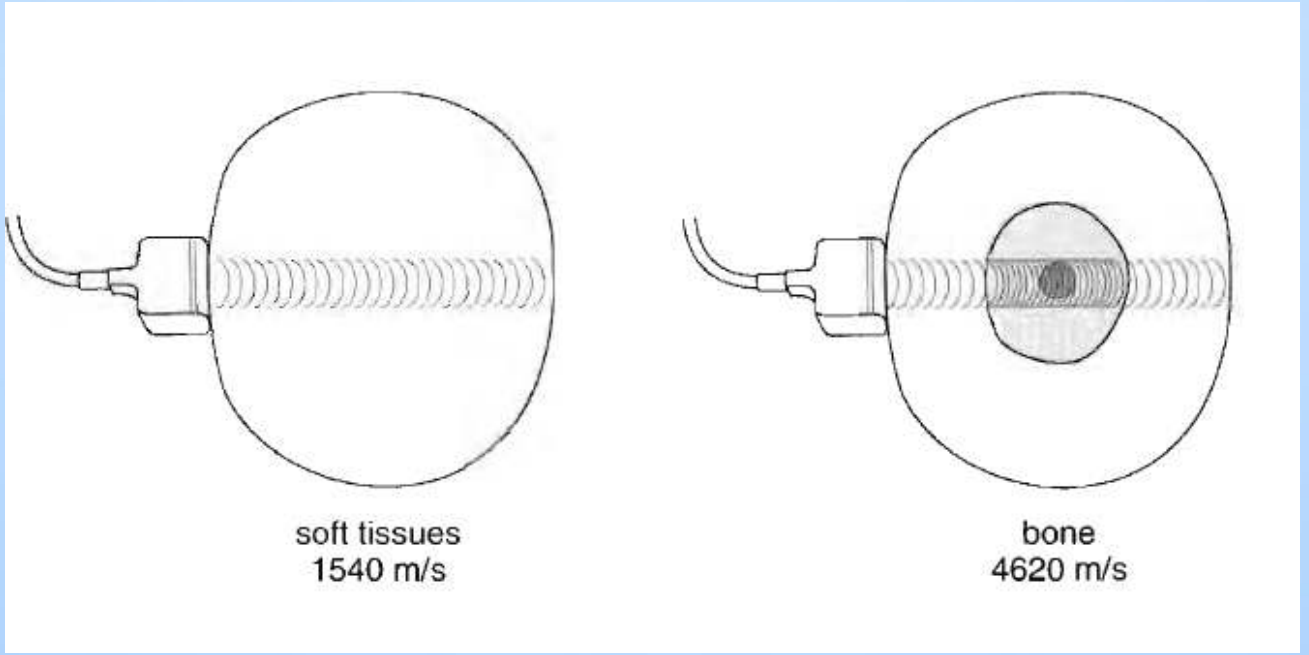

Wavelength



- The wavelength of ultrasound is inversely proportional to its frequency.
- The higher the frequency, the shorter the wavelength.
- For example, ultrasound of 3 MHz has a wavelength of 0.5 mm in soft tissue, whereas ultrasound of 6 MHz has a wavelength of 0.25 mm.
- The shorter the wavelength, the better the resolution, giving a clearer image and more details on the screen.

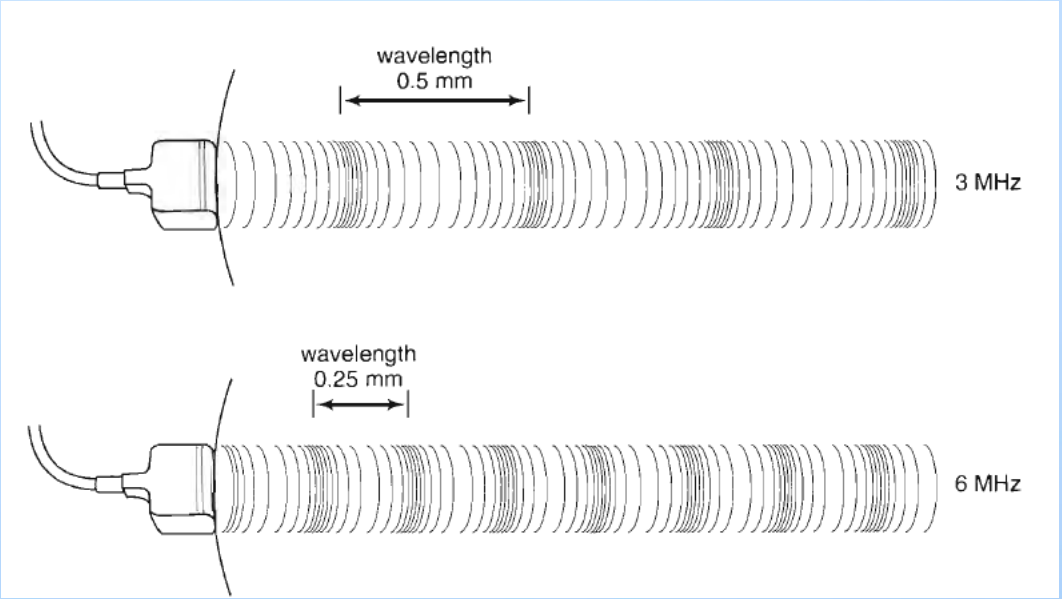

Focusing



Ultrasound waves can be focused either by lenses and mirrors or electronically in composite transducers. In the same way that a thin beam of light shows an object more clearly than a widely scattered.

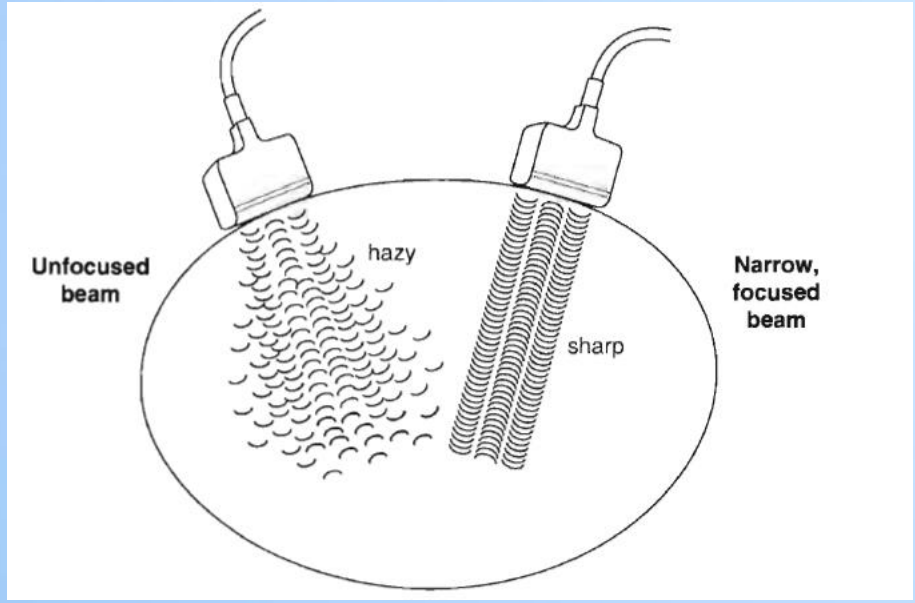

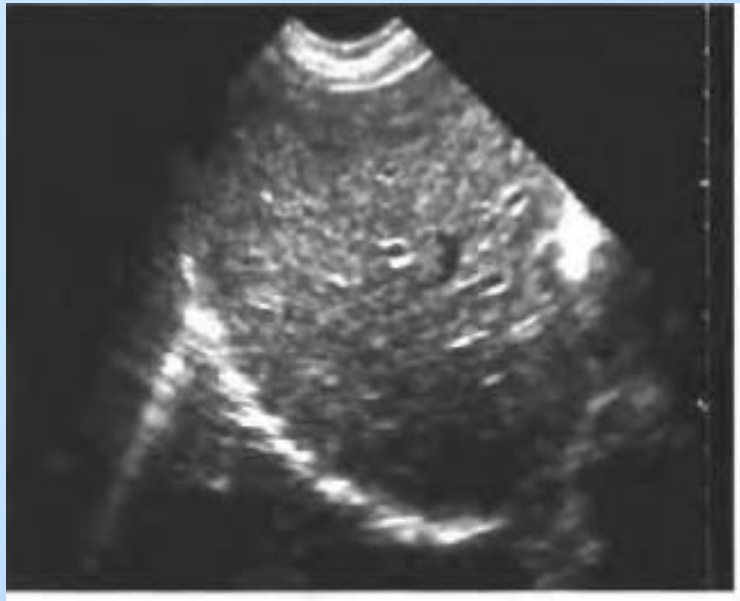

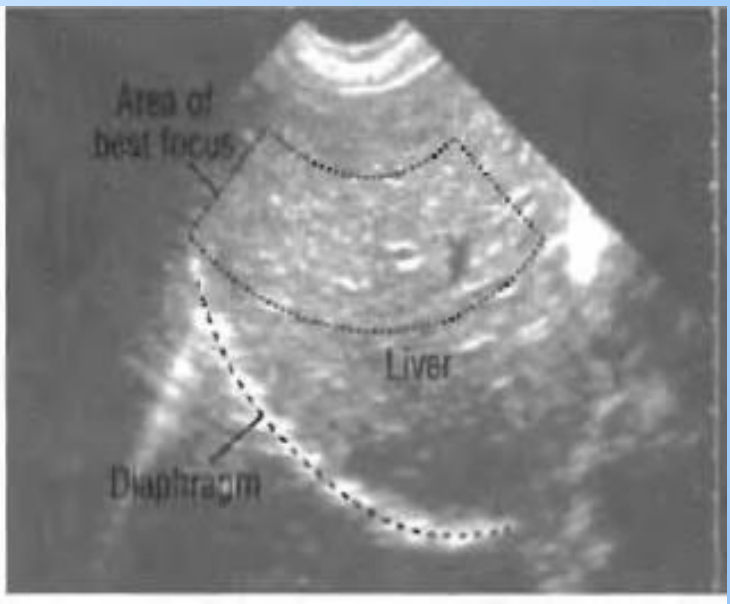

Attenuation



Tissues in the body absorb and scatter ultrasound in different ways. Higher frequencies are more readily absorbed and scattered (attenuated) than lower frequencies. Thus, to reach deeper tissues, it is necessary to use lower frequencies becallse the waves are less likely to be diverted as they traverse intervening structures. In practice, it is better to use about 3.5 MHz for deep scanning in adults and 5 MHz or higher if available for scanning the thinner bodies of children. 5 MHz or greater is also best for scanning superficial organs in adults.

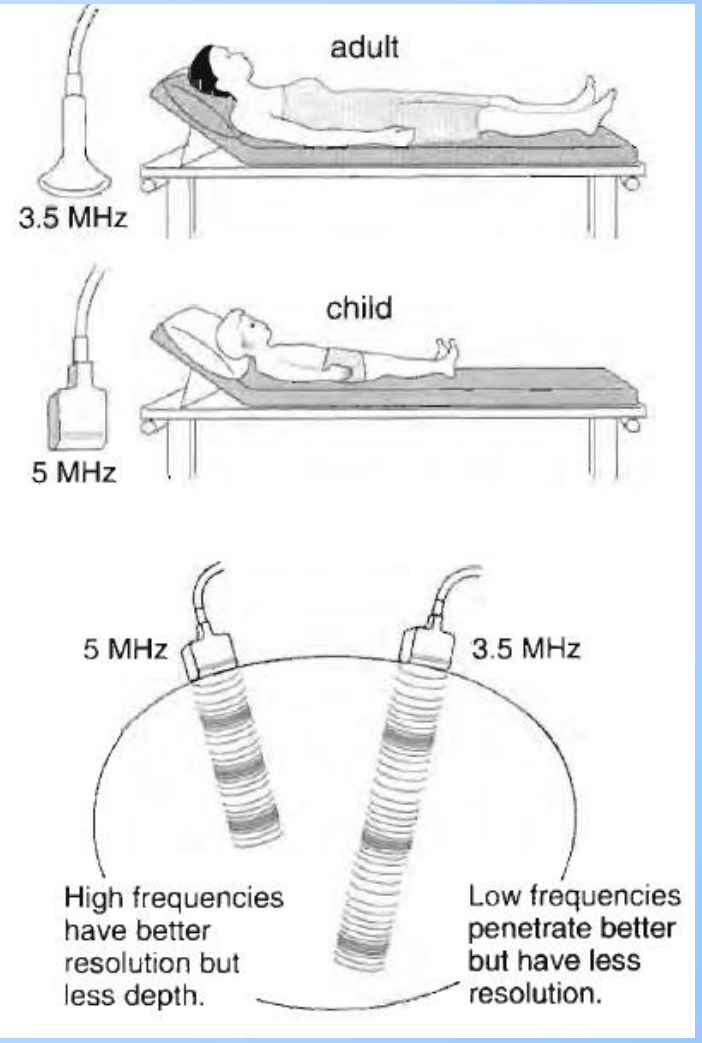

Amplification



The echoes that return from deeper structures are not as strong as those that come from tissues nearer the surface; they must, therefore, be amplified and in the ultrasound unit this is done by the time-gain-compensation (TGC) amplifier. In all ultrasound units it is possible to vary the degree of amplification to compensate for ultrasound attenuation in any part of the body and improve the quality of the final image

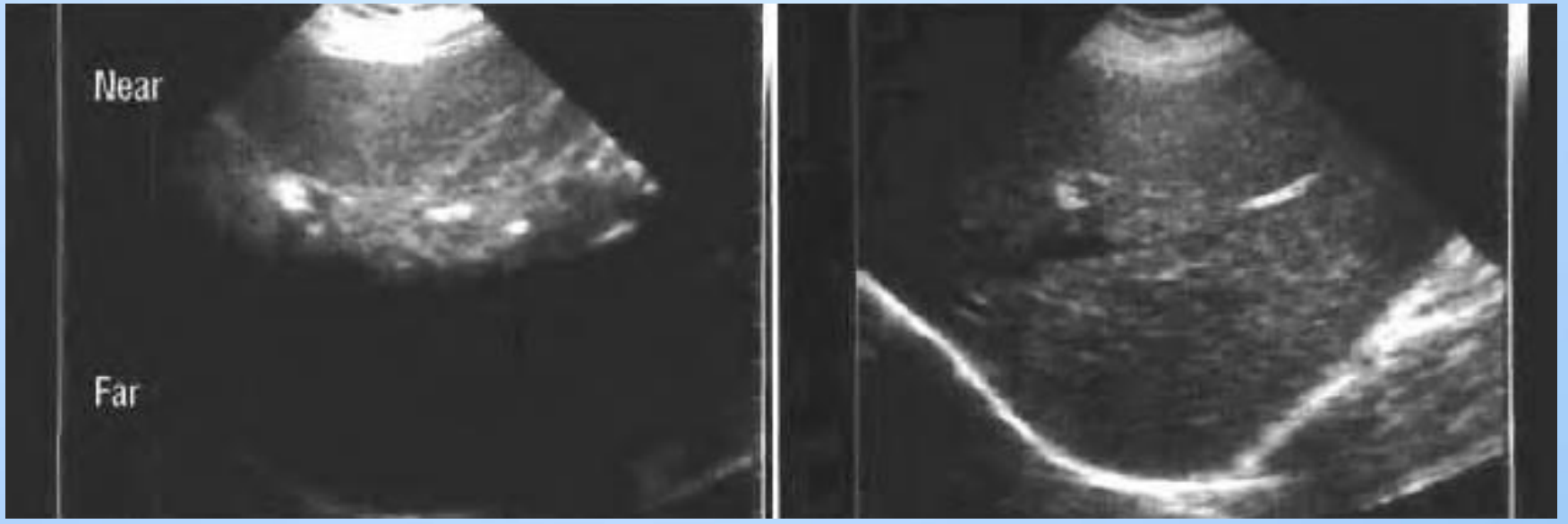

Boundaries



Ultrasound may be reflected or refracted (bent) when it meets the boundary between two different types of tissue: reflection means the waves are thrown back and refraction means they change in direction and are not necessarily reflected

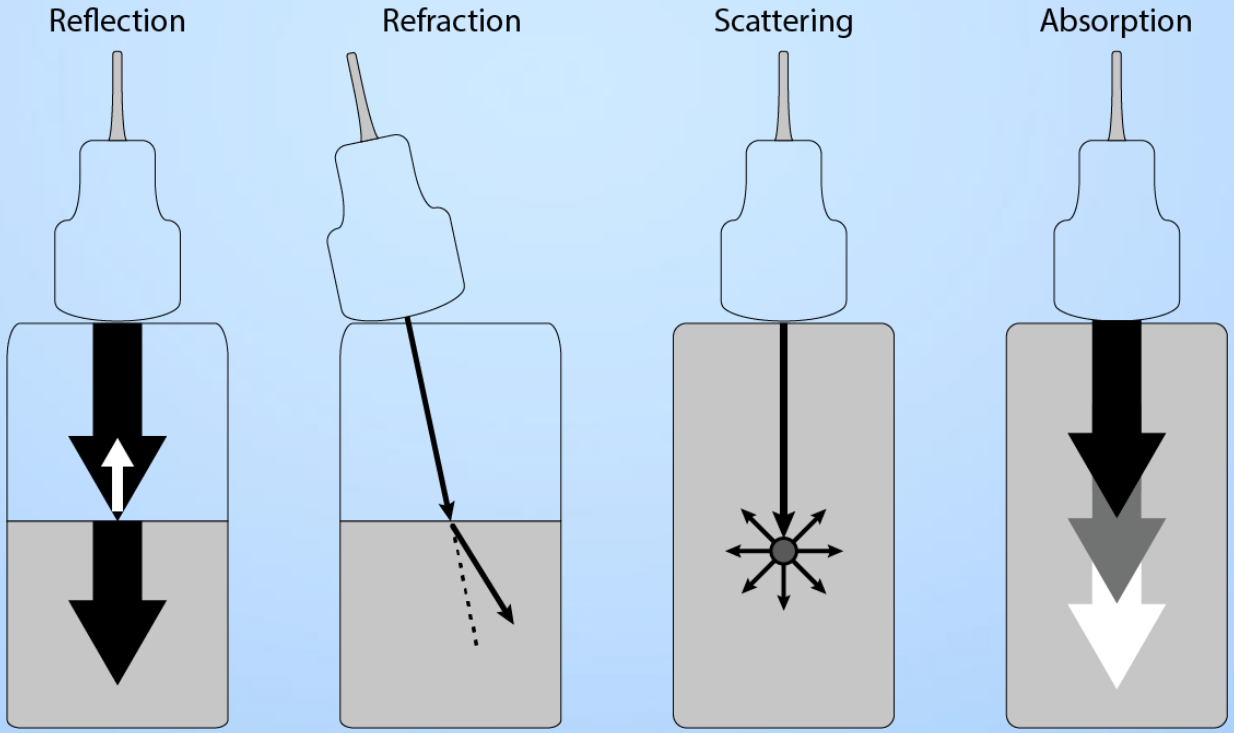

The shape of the scans from different transducers



1. **Linear array.** Scans from this type of transducer are rectangular.They are most useful in obstetrics and for scanning the breast and the thyroid
2. **Sector scanner.** These scans are fan-shaped, almost triangular, and originate through a very small acoustic window. These scanners can be used whenever there is only a small space available for scanning. They are most useful in the upper abdomen and for gynaecological and cardiological examinations



	Linear Array	Sector (Phased) Array	Curved Linear Array
	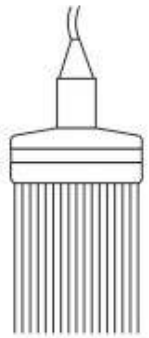	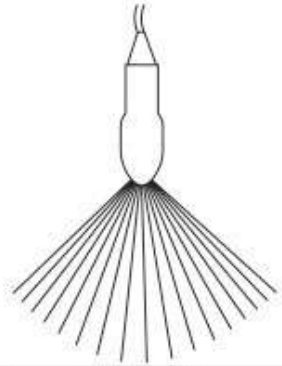	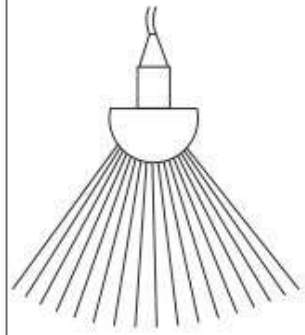
Frequency range	Higher (8–15 MHz)	Lower (2–6 MHz)	Higher (2–12 MHz)
Depth of imaging	Superficial (1–4 cm)	Deeper (4–8 cm)	Intermediate (2–6 cm)
Field of view	Linear, limited (depends on footprint)	Trapezoidal, wider at depth, narrow at the surface	Trapezoidal , wide at surface and depth

The shape of the scans from different transducers



3. Convex transducer. This produces a scan somewhere between those of the linear and the sector scanners and is therefore useful for all parts of the body except for specialized echo cardiography

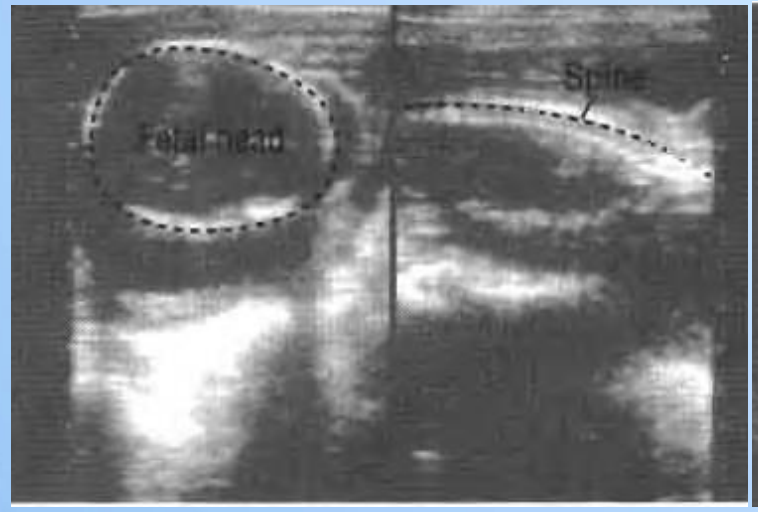

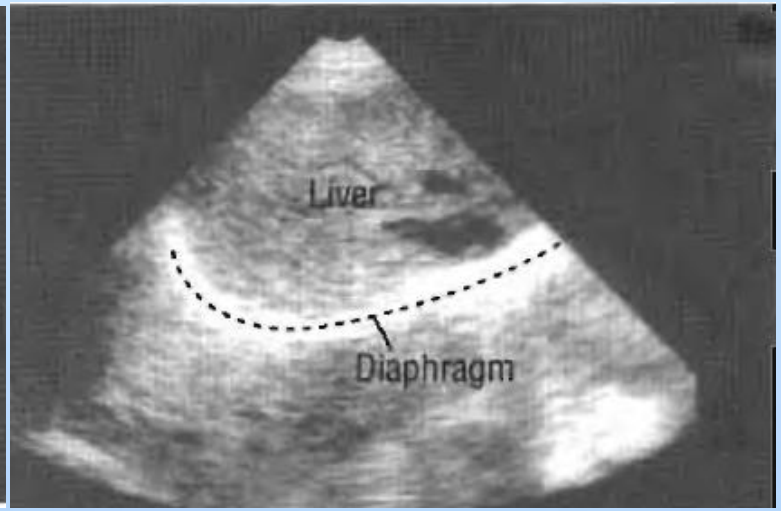



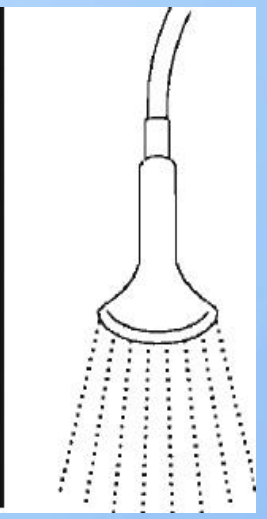

The shape of the scans from different transducers



Probe Name	Probe Frequency	Scanning Depth	Probe Picture
Convex	Frequency=3.5 MHz , R=60,	≥170 mm	
Transvainal	Frequency=6.5 MHz , R=13	≥60 mm	
Linear	Frequency=7.5 MHz , L=40	≥40 mm	
Rectal-Human	Frequency=7.5 MHz , L=40	≥40 mm	
Micro-convex	Frequency=5.0 MHz , R=20	≥60 mm	
Rectal-Veterinary	Frequency=6.5 MHz , L=64	≥40 mm	


Thank you