

Obstetrics

Dr.Hayder Jasim Taher

PhD of Medical Imaging



Outline of my presentation

- ✓ Introduction.
- ✓ Preparation.
- ✓ Early pregnancy.
- ✓ Ectopic pregnancy

Introduction:



Obstetrical ultrasound provides pictures of an embryo or fetus within a woman's uterus, as well as the mother's uterus and ovaries.

Preparation



Preparation of the patient. The bladder must be full. Give 4 or 5 glasses of fluid and examine after one hour (do not allow the patient to micturate). Alternatively. fill the bladder through a urethral catheter with sterile normal saline: stop when the patient feels uncomfortable. Avoid catheterization if possible because of the risk of infection.

Position of the patient. The patient is usually scanned while lying comfortably on her back (supine). It may be necessary to rotate the patient after the preliminary scans. Apply coupling agent liberally to the lower abdomen: it is not usually necessary to cover the pubic hair but. if required. Apply freely.

Choice of transducer. Use a 3.5 MHz transducer. Use a 5 MHz transducer for thin women.

Setting the correct gain. Position the transducer longitudinally over the full bladder and adjust the gain to produce the best image.

Introduction



Is ultrasound safe during pregnancy?

Yes, as far as is known. However, it should be used only when there is a good clinical reason.

Is a clinically normal pregnancy a good reason for using ultrasound?

This is controversial and is still being investigated. However, there is agreement that there are two stages during a normal pregnancy when ultrasound scans will be the most useful and provide the most information.

These stages are:

1. At 18 -22 weeks after the first day of the woman's last menstrual period.
2. At 32 - 36 weeks after the first day of the woman's last menstrual period.

Introduction





Introduction



When is ultrasound not recommended?

There is no indication for an ultrasound examination in the first trimester of pregnancy unless there is a clinical abnormality.

Why is a scan not recommended at the mother's first visit?

Some physicians do recommend an ultrasound examination at the time of the mother's first visit, but there is no reason to do this provided the clinical examination is normal. When considered necessary, scanning during weeks 18-22 of pregnancy will provide much more important information.

Introduction



Why consider scanning during a normal pregnancy?

Many physicians consider that scanning is unnecessary during a clinically normal pregnancy. Others recommend scanning because many obstetric abnormalities cannot be detected by clinical examination.

1. 90% of developmental fetal abnormalities occur without any family history and very few of the mothers show any obvious risk factors.
2. There can be significant fetal abnormalities even in a clinically normal pregnancy.
3. Neither clinical examination nor a family history is an entirely reliable way to detect multiple pregnancy.
4. A signlificant number of mothers with a low-lying placenta (placenta praevla) show no evidence until bleeding starts at the onset of labour. The situation can then be extremely dangerous. especially if the patient is a long way from the nearest hospital.
5. Up to 50% of mothers who claim to know their obstetric dates with certainty are in fact more than two weeks in error when gestational age is calculated with ultrasound. A discrepancy of two weeks can be critical for the survival of an infant who has to be delivered early because of some antenatal complication.

Introduction



What is important in the 18-22 week scan?

This is the best time during pregnancy to:

1. establish the gestational age accurately;
2. diagnose multiple pregnancy;
3. diagnose fetal abnormalities;
4. locate the placenta and identify patients in whom there is a risk of placenta praevia;
5. recognize myomas or any other unexpected pelvic mass that may interfere with pregnancy or delivery.

Introduction



What is important in the 32-36 week scan?

This is the best time during pregnancy to:

1. recognize intrauterine growth retardation;
2. recognize fetal anomalies that were not detected at the first scan;
3. confirm the presentation and position of the fetus;
4. locate the placenta accurately;
5. assess the amount of amniotic fluid;
6. exclude possible complications, e.g. myoma, ovarian tumour.

Introduction



What can be learned from an early scan (before 18 weeks)?

Ultrasound in the early weeks of pregnancy can:

1. confirm the pregnancy;
2. accurately estimate gestational age;
3. locate the pregnancy (intra- or extrauterine);
4. recognize single or multiple pregnancy;
5. exclude molar pregnancy;
6. exclude pseudo-pregnancy due to a pelvic mass or hormone-secreting ovarian tumour;
7. diagnose myomas or ovarian masses which might interfere with normal delivery.

Introduction: Early pregnancy



In the first trimester, doctors usually use a transvaginal rather than abdominal ultrasound. The transvaginal ultrasound provides the most accurate information, this point. A transvaginal ultrasound can get closer to the developing pregnancy.

In a transvaginal ultrasound, the doctor or technician inserts a thin probe into the vagina. During the ultrasound, they take a series of measurements, including the size of the gestational sac, the size of the yolk sac, the length of the fetal pole, and the heart rate.

In an abdominal ultrasound, the woman will be asked to come to the scan with a full bladder, because this positions the uterus in a way that makes it easier to obtain measurements. The doctor or technician then spreads a gel over the lower abdomen and uses a transceiver to take measurements from several angles.

Early pregnancy



Location of the gestational sac is the first evidence of pregnancy. It can often be recognized in the uterus after five weeks of amenorrhoea. and may be located asymmetrically.

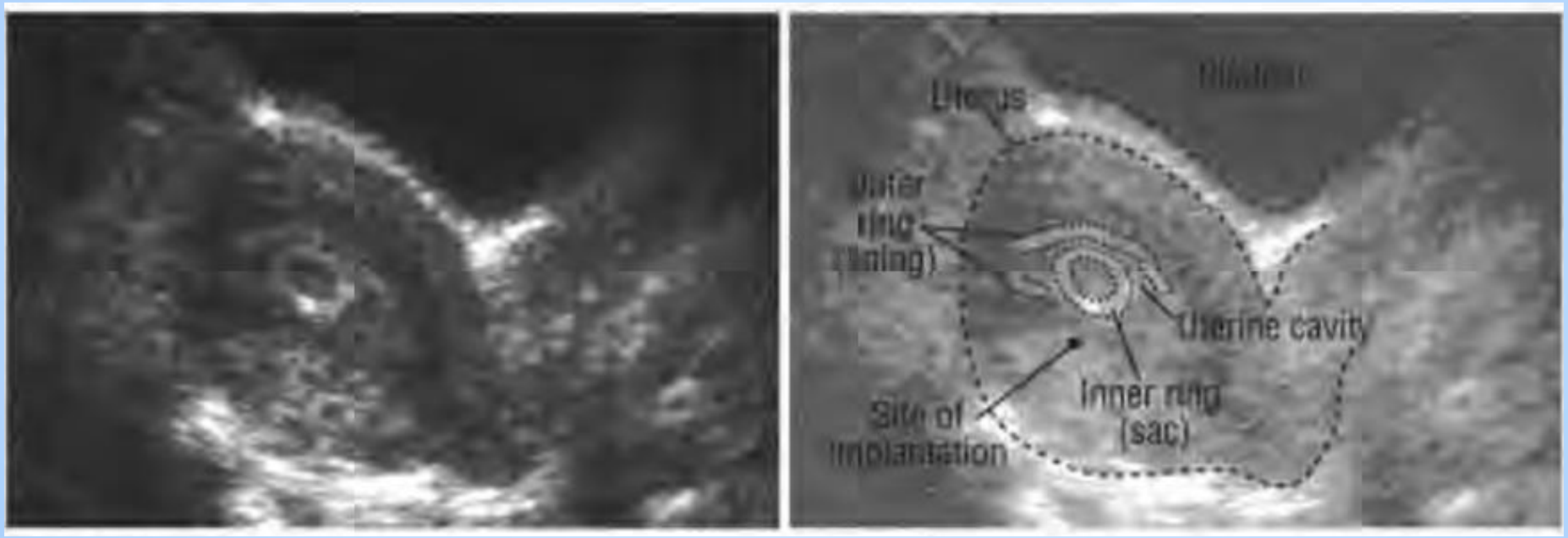

The gestational sac at 5-6 weeks. The centre is hypoechogenic. surrounded by a double echogenic ring. The inner ring is complete and is the gestational sac. The outer ring is incomplete and is the lining of the uterus. These two rings are separated by the anechogenic space of the residual endometrial (uterine) cavity.

Early pregnancy



All normal pregnancies should be recognizable after 6 weeks as a well defined "double echogenic ring" in the uterus. The inner ring is of uniform echogenicity and is 2 mm or more thick. Around it is a thin echogenic ring, which does not encircle the entire gestational sac. Between the two rings is the anechogenic residual uterine cavity.

At 5-6 weeks, the greatest diameter of the gestational sac is approximately 1-2 cm.

At 8 weeks the sac should occupy half the uterus; at 9 weeks it should take up two-thirds of the uterus, and at 10 weeks it should fill the uterus.

Early pregnancy



The gestational age can be estimated to within one week from the mean dimension of the sac. Using a longitudinal scan, measure the maximum dimensions of the sac in the long axis (length), and at 90° to this in the antero-posterior (AP) dimension (upper scan). Make a transverse scan at right angles to the longitudinal scan plane and measure the greatest width of the sac (lower scan). The mean dimension of the sac is the sum of these three measurements divided by 3.

$$\text{Mean gestational sac dimension} = \frac{\text{Length} + \text{AP} + \text{Width}}{3}$$

The gestational age of the fetus can be estimated by reference to local standard development tables

Early pregnancy

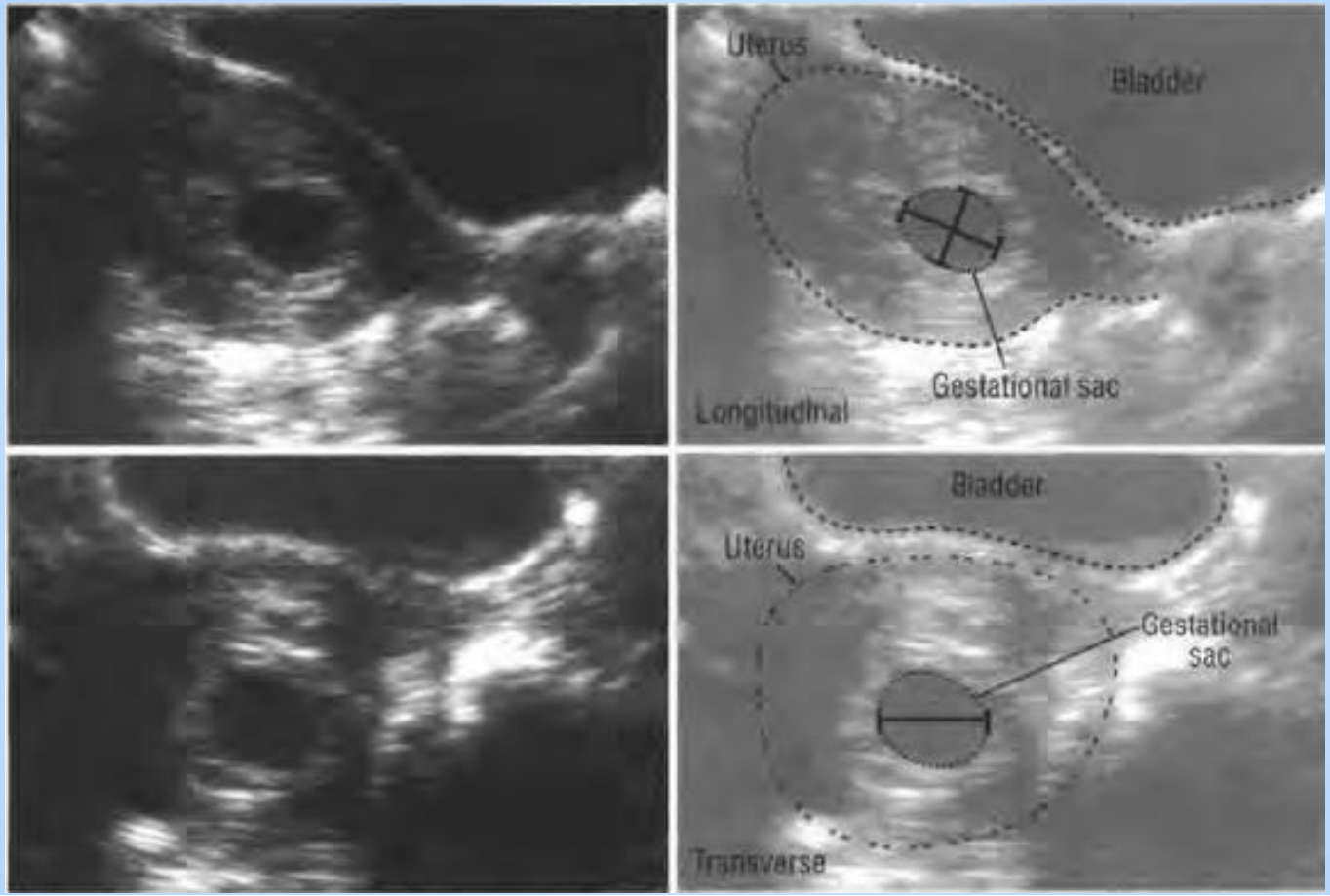

Fig-17: Measurement of the gestational sac. The length is the longest internal dimension in the longitudinal plane (upper). The antero-posterior measurement is the widest part of the sac at right angles to the length (upper). The width is the widest part in a transverse scan (lower).

IUD and normal pregnancy



If the IUD is located well away from the implantation site of the embryo, pregnancy can be allowed to progress without interference .
If the IUD is partially expelled, the pregnancy can be allowed to progress without interference.
If the IUD strings can be seen in the vagina, the device can be carefully removed.
In all other cases, spontaneous abortion is likely to occur, and the patient should be warned of this possibility.

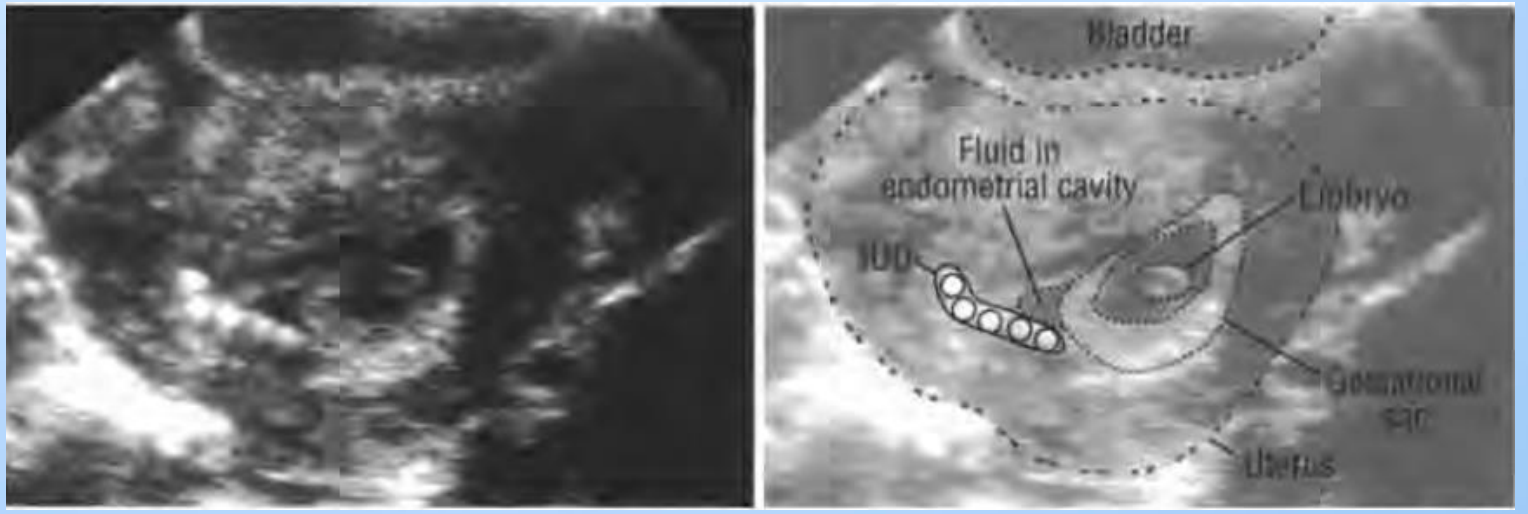

Ectopic pregnancy



If there is an ectopic pregnancy, a gestational sac may be seen outside the uterus. Sometimes there is a sac-like structure in the uterus despite the pregnancy being ectopic (Fig. 168). The real sac can be distinguished from the "pseudosac" by the presence of fetal parts, a yolk sac within the real sac or by a single ring around the pseudosac instead of a double ring

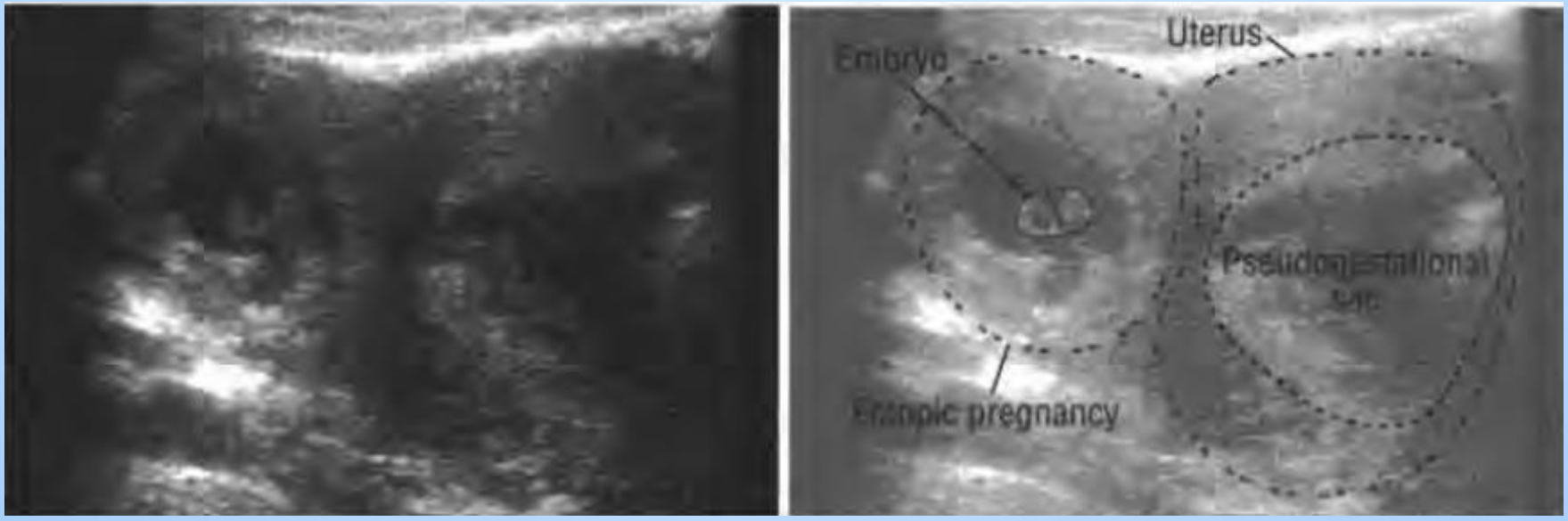


Thank you