

The embryo, The yolk sac, multiple pregnancy

Dr.Hayder Jasim Taher

PhD of Medical Imaging



Outline of my presentation

- ✓ The embryo.
- ✓ The yolk sac.
- ✓ Multiple pregnancy.
- ✓ Doppler ultrasound.

Introduction:



At 8 weeks of pregnancy, the placenta and fetus have been developing for 6 weeks. The placenta forms tiny hairlike projections (villi) that extend into the wall of the uterus. Blood vessels from the embryo, which pass through the umbilical cord to the placenta, develop in the villi.

Yolk sac is the first anatomical structure identified within the gestational sac. It plays a critical role in embryonal development by providing nutrients, serving as the site of initial hematopoiesis, providing endocrine, metabolic and immunological functions and contributing to the development of fetal gastrointestinal and reproductive systems . As the pregnancy advances, the yolk sac progressively increases from the 5th to end of the 10th gestational week, following which the yolk sac gradually disappears and is often sonographically undetectable after 14-20 weeks.

The embryo



Although the gestational sac can be recognized at 5 weeks in some patients and at 6 weeks in the majority, the embryo does not become visible until the eighth gestational week (Fig.). It will then be shown as a focal area of echoes, often lying eccentrically within the gestational sac. If the fetus is alive, the heart will be recognized lying in mid-embryo, usually seeming to lie anterior to the rest of the thorax.



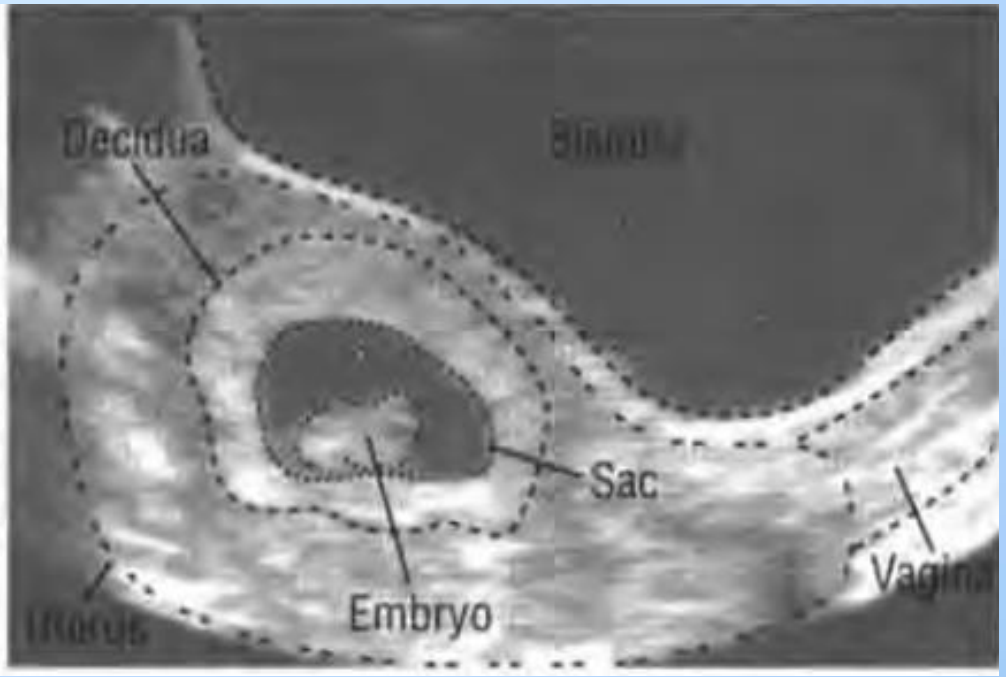

The embryo



after the ninth or tenth week, the fetal head can be distinguished from the body and movements can be seen. At 10 weeks the fetus becomes more human in appearance (Fig.). after the twelfth week, the skull becomes visible.

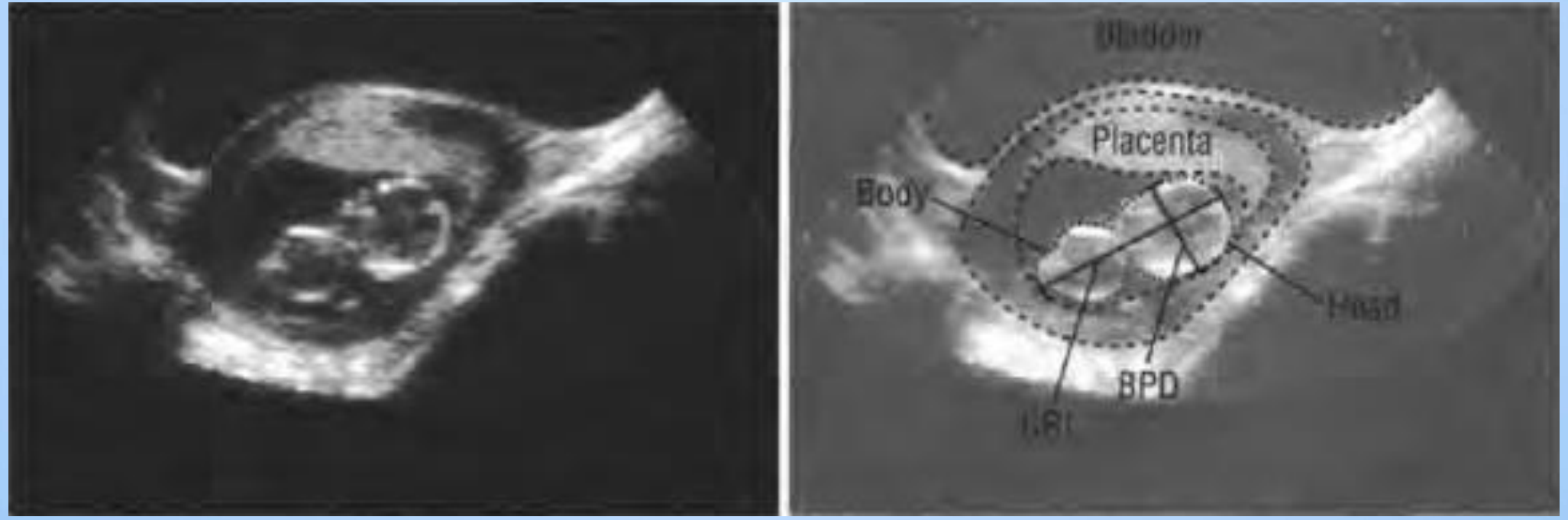

A normal 12 week pregnancy. The crown rump length (and biparietal diameter are shown)

The yolk sac



From about 7 weeks onwards. it is usually possible to see a round cystic structure about 4-5 mm in diameter adjacent to the fetus. This is the yolk sac. the site of the earliest blood cell formation. It disappears at about the eleventh week. The yolk sac may not be seen in all pregnancies. even when quite normal.
It is important to recognize that this cystic shadow is the yolk sac and not mistake it for a second. twin embryo (Fig.). (The yolk sac is not included in crown-rump measurements.)

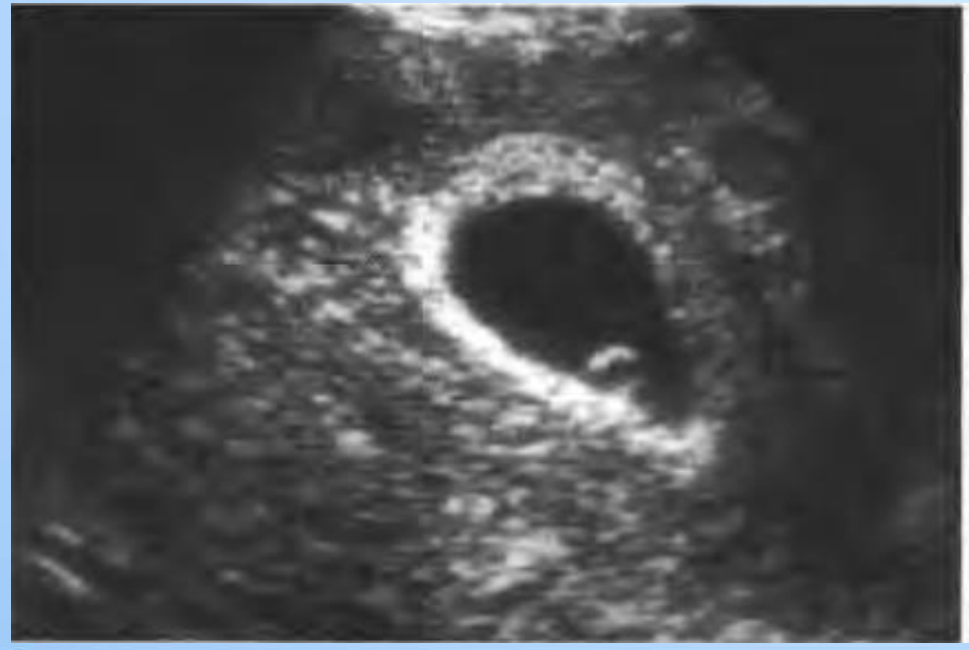

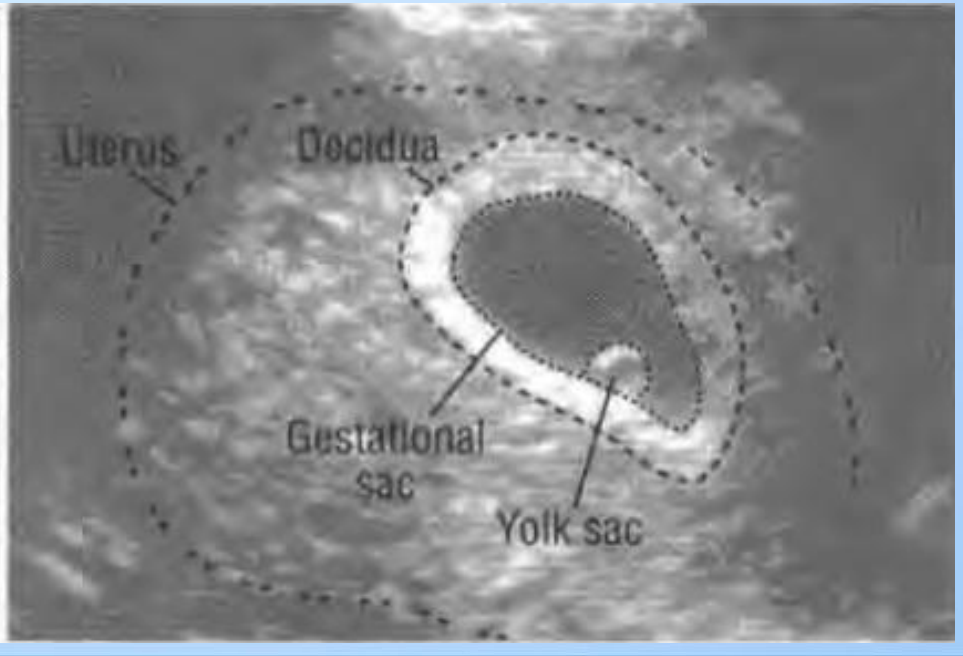

Multiple pregnancy



The earliest it is possible to diagnose multiple pregnancy is at about 8 weeks' gestation; however. not all gestational sacs go on to contain a viable fetus. Never tell a patient that she has a multiple pregnancy until more than one viable fetus is recognized and each is growing normally.
This is usually after about 14 weeks. and is best seen between 18 and 22 weeks (Fig.).

Multiple pregnancy can usually be recognized at about 8 weeks, but do not tell the patient until confirmed by a scan after 14 weeks.

Multiple pregnancy



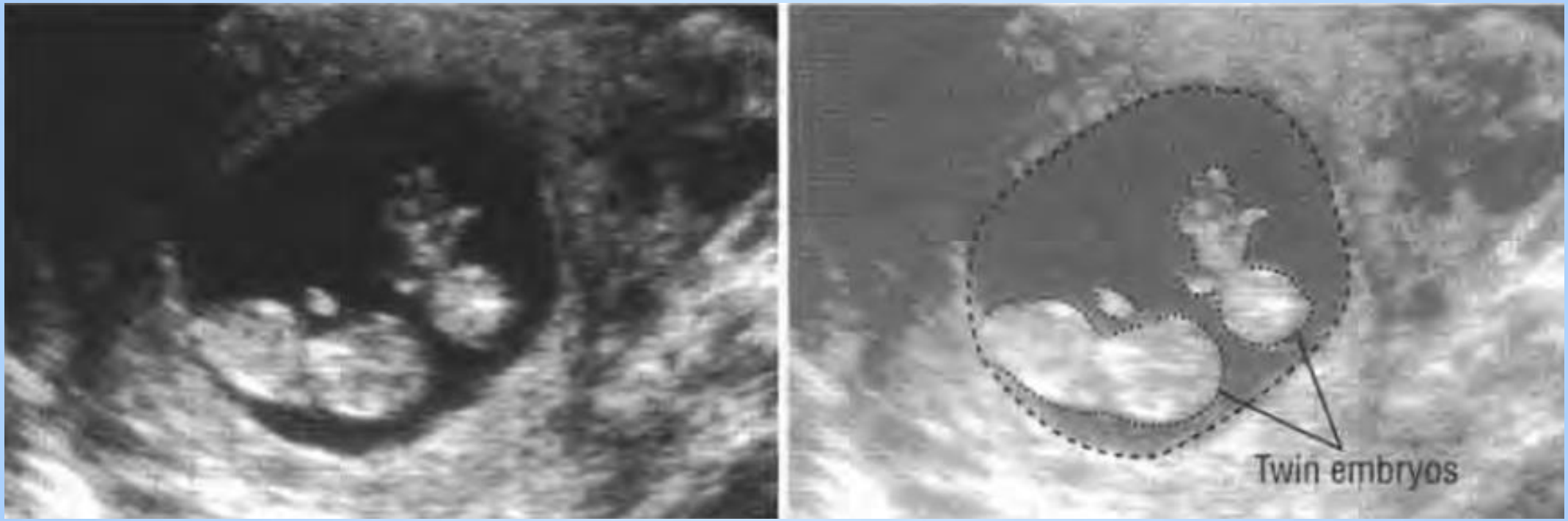

Twin pregnancy: each embryo must be measured separately. usually requiring scans at different angles.

Abnormalities in the first three months of pregnancy



Introduction:

First-trimester sonography is used extensively for dating pregnancy and in conjunction with chorionic villus sampling. It is crucial to examine the fetus carefully, even at this early stage, since some fetal abnormalities are detectable in the first trimester. First-trimester ultrasound was introduced in order to more accurately estimate gestational age and identify multiple pregnancies and diagnose non-viable pregnancies

Abnormalities in the first three months of pregnancy



Small gestational sac

A small gestational sac is usually due to a blighted ovum (anembryonic gestation) and is a fairly common finding. On ultrasound examination the gestational sac is found to be smaller than expected for the gestational age. and the fetus cannot be demonstrated (Fig.).

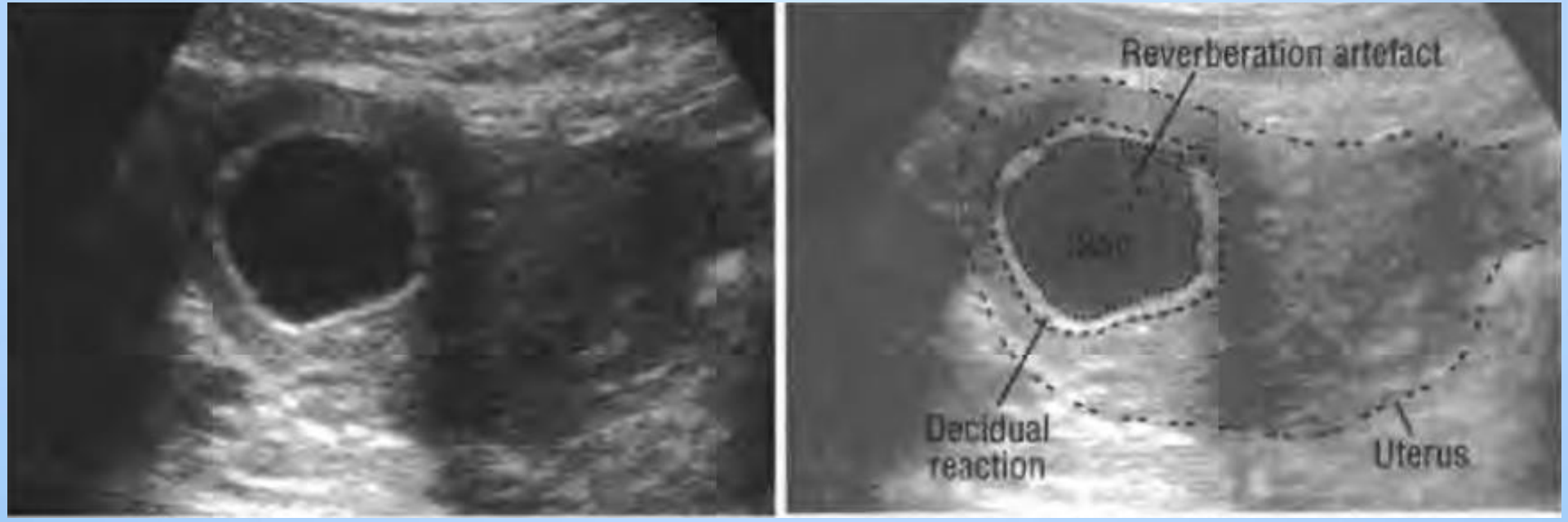

Abnormalities in the first three months of pregnancy



Small gestational sac

If an early pregnancy is clinically normal, but an ultrasound scan shows an enlarged uterus. an anembryonic gestation should be suspected: repeat the examination after 7 days. If the pregnancy is normal. the sac should have grown. and the fetus and the heart activity should be clearly seen at the second examination.

Fetal death (spontaneous abortion)



When there is a fetal or embryonic death. the patient may remain clinically normal and may continue to feel pregnant for days. There may be a history of bleeding or abdominal cramp. The uterus may be normal, small. or even enlarged if there is significant intrauterine haematoma.

The fetal pole may be visible but no heart action will be demonstrated. If the examination is made during the first 8 weeks of pregnancy. It should be repeated after another 7 days. After the eighth week. fetal life should always be demonstrable in a normal pregnancy.

Fetal death (spontaneous abortion)



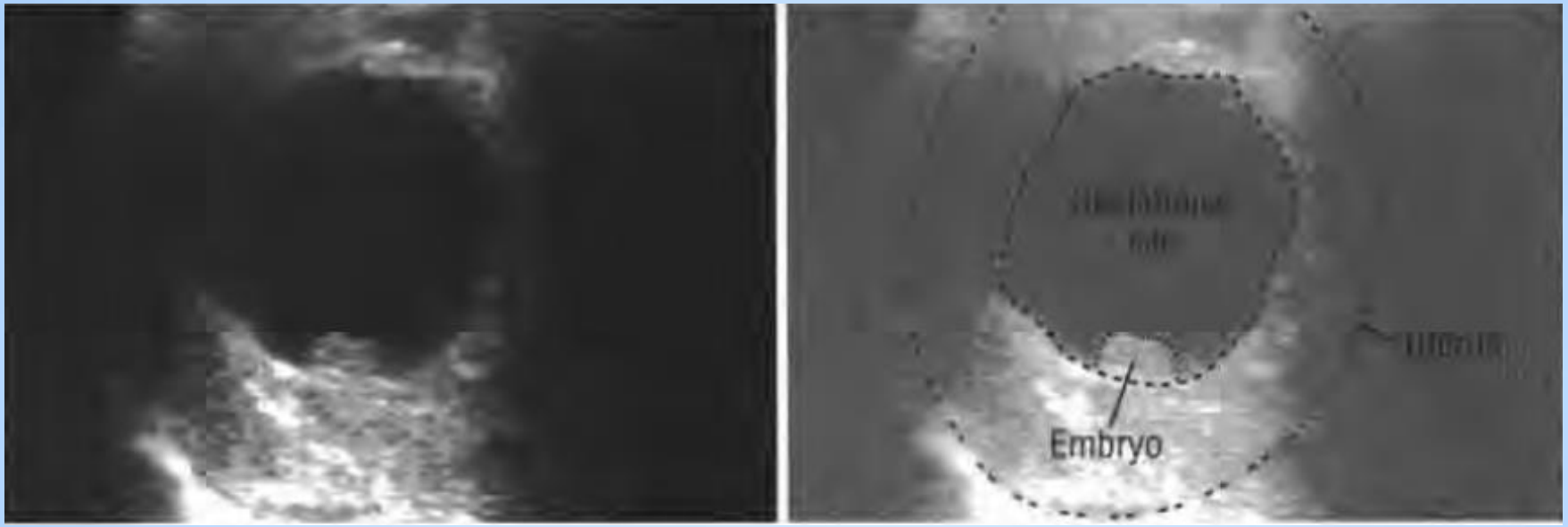

Fetal death. The sac is the correct size for the expected gestational age. but the embryo is too small (and no heart beat was seen).

It should always be possible to demonstrate fetal heart activity after the eighth week of pregnancy.

Incomplete abortion



The patient may have a history of amenorrhoea, followed by loss of blood; she may have seen the fetus. If this is recent, the uterus may still be large, approximately the expected size for gestational age. However, the uterus may be empty and the endometrial canal may be normal. If the abortion is incomplete, the uterus will be smaller than expected for gestational age and filled with an abnormally shaped sac or with an amorphous mass of variable size, shape and echogenicity. This is the retained placenta and blood clots. There will be no sign of fetal life.

Incomplete abortion



It can be difficult to recognize the retained products of conception after a spontaneous abortion. This diagnosis should not be made unless there are identifiable parts, such as a yolk sac, gestational sac or dead embryo. Endometrial thickening is not a reliable way of recognizing or excluding retained products of conception, and a molar pregnancy must be excluded.

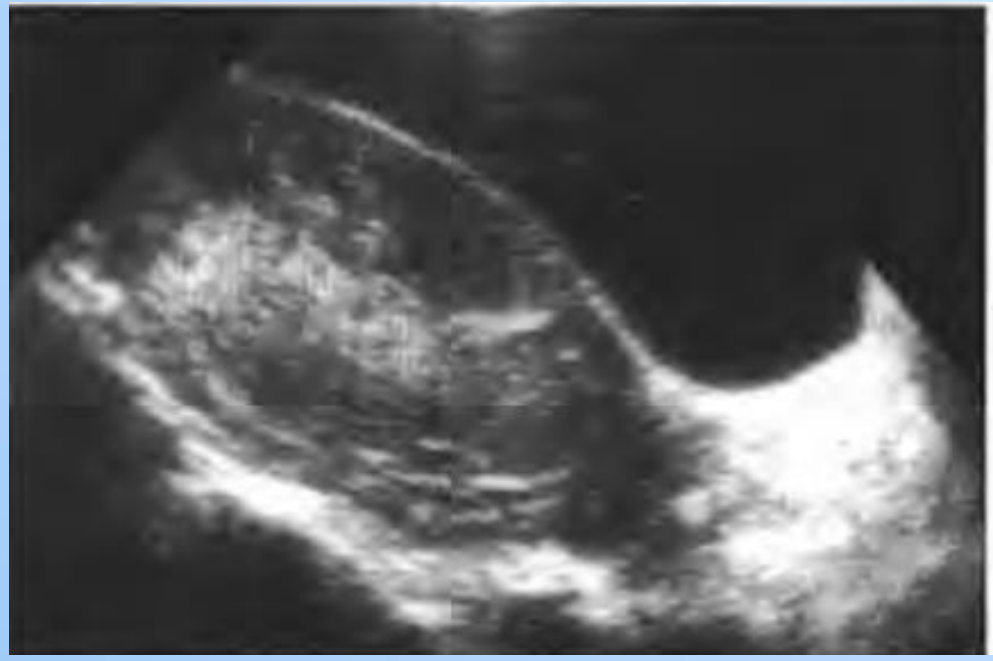



Large uterus



The commonest causes of a uterus larger than expected are:

- Hydatidiform mole.
- Choriocarcinoma.
- Intrauterine bleeding associated with spontaneous abortion.
- Uterine myoma (fibroids).

1. Hydatidiform mole.



Clinical findings are nonspecific. Ultrasound is almost always abnormal and shows a large uterus filled with a mass of uniform echoes providing a regular speckled appearance: the "snow-storm" effect. It may be difficult to distinguish a mole from echogenic blood within the uterus. but blood is usually more heterogeneous and less echogenic than a mole. which may have cystic spaces (vesicles). In older patients in particular. a large myoma may cause confusion.

1. Hydatidiform mole.

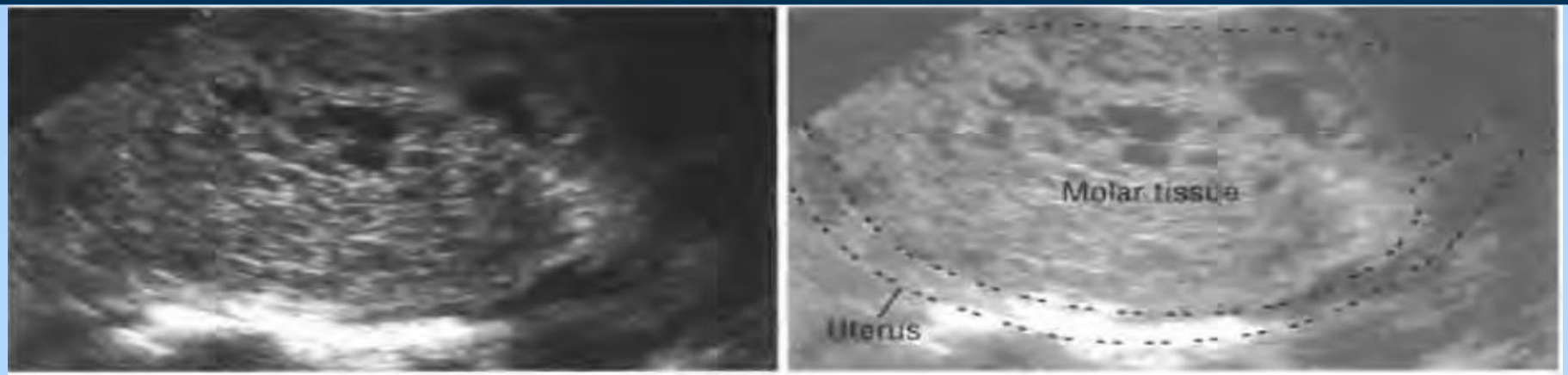

Fig. 176a. A hydatidiform mole filling the uterus with echogenic and cystic tissue.

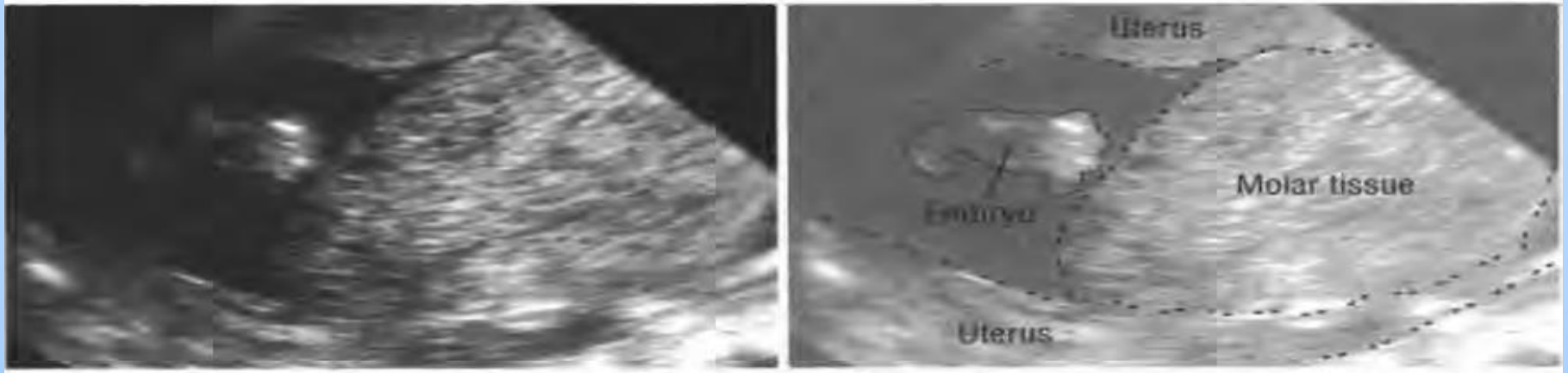

Fig. 176b. A hydatidiform mole with a living embryo. There is an increased risk of chromosomal abnormalities in the fetus and, as pregnancy progresses, there is an increasing likelihood of fetal death.

2. Choriocarcinoma



may be indistinguishable from a hydatidiform mole by ultrasound. but it should be considered if the uterus is much larger than expected and the ultrasound scan shows areas of haemorrhage and necrosis rather than the uniform echoes of a mole. The pattern of choriocarcinoma may be mixed. with both solid and fluid echoes. rather than the homogeneous snow-storm effect of a mole. Rarely there may be disease elsewhere: X-ray the chest to exclude metastases.

3. Intrauterine haemorrhage due to threatened or spontaneous abortion.



This is mainly a clinical diagnosis based on bleeding in early pregnancy The blood may be completely anechogenic or echogenic. It is usually heterogeneous

If there is any doubt after one scan, repeat in one or two weeks.

3. Intrauterine haemorrhage due to threatened or spontaneous abortion.



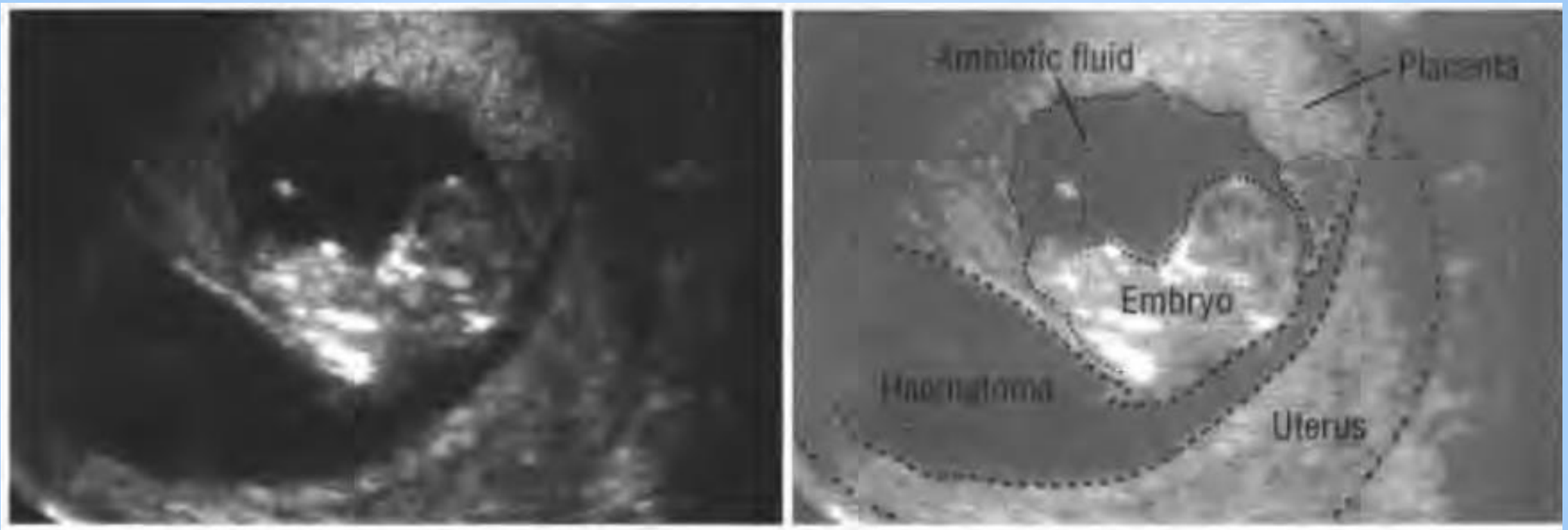

Fig. 177. A poorly echogenic intrauterine haematoma, which is lifting the edge of the placenta and distorting the gestational sac. This haematoma was absorbed and the embryo survived.

4. Large irregular uterus



In the first trimester a large, irregular uterus is usually due to uterine myomas . Record the size and position of the myomas and estimate the potential difficulties that they may cause during labour. The myomas should be reviewed at 32-36 weeks' gestation. The central area may become necrotic, showing a mixed or echo-free pattern.

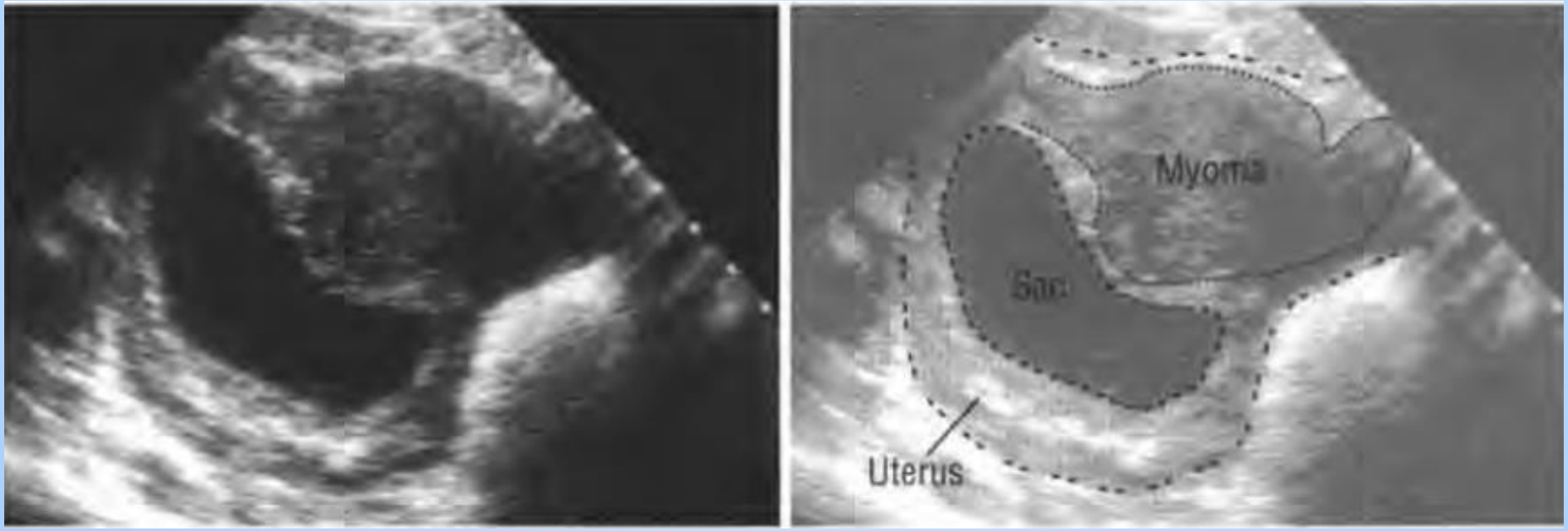

A myoma pressing on the gestational sac and also bulging outward from the uterus. There is varying echogenicity in the myoma.


Thank you