

Normal and abnormal testis

Dr.Hayder Jasim Taher

PhD of Medical Imaging



Outline of my presentation

- ✓ Introduction.
- ✓ Indications.
- ✓ The normal testis.
- ✓ Abnormal scrotum.
- ✓ Small or absent testis.
- ✓ The epididymis.
- ✓ Testicular trauma.
- ✓ Torsion of the testis.
- ✓ Hernia.
- ✓ Varicocele.

Introduction:



Ultrasound imaging of the scrotum provides pictures of a male's testicles and the surrounding tissues. It is used to help evaluate disorders of the testicles, epididymis (tubes immediately next to the testicles that collect sperm) and scrotum.

Indications



1. Swelling of the scrotum.
2. Trauma.
3. Infection.
4. Pain.
5. Apparently absent testicle (swelling in the groin in young males).
6. Haematospermia.
7. Infertility.

The normal testis



The normal testis is oval, homogeneous and hyperechogenic .

1. The average length in the adult is 5.0 cm.
2. The average width is 3.0 cm.
3. The average transverse diameter is 2.0 cm.
4. The vertical diameter is 2.5 cm.

The epididymis lies on the inferior aspect of the testis and is more echogenic than the testis. It is subdivided into a head, body and tail, the head being the part most reliably demonstrated by ultrasound. The two testes are separated in the scrotum by a hyperechogenic septum. There are often small collections of fluid within the scrotum.

Abnormal scrotum



Unilateral swelling

Swelling on one side of the scrotum may be due to:

1. **Hydrocele.** Fluid in the scrotum will surround the testis with an echo-free region, varying in size and position. If the fluid is due to inflammation or trauma, there may be internal debris causing internal echoes on ultrasound. The testis must be carefully examined to exclude underlying malignancy.
2. **Trauma and torsion of the testis.**
3. **Hernia.**
4. **Varicocele.**
5. **Testicular mass**, e.g. tumour or infection. The majority of testicular tumours are malignant. The tumours may be hypoechogenic or hyperechogenic, and the testis may be normal in size or enlarged. The two testes must be compared, because a tumour may replace all the normal tissue, and can then only be recognized by the difference in echogenicity. Even when the two testes are of equal density, gentle compression may show a small tumour not demonstrated by routine scanning. It can be difficult to distinguish between tumour and infection.

Small or absent testis



Failure to demonstrate a testis in the scrotum with ultrasound indicates that the testis is absent. If clinical examination of the inguinal canal reveals a mass, ultrasound can demonstrate the location and size of the mass, but may not be able to differentiate testicular tissue from an enlarged lymph node. If there is no palpable mass in the inguinal region on clinical examination, there is no indication to proceed with ultrasound.

The epididymis



The epididymis may become infected or develop cysts.

1. **Epididymitis.** Ultrasound will demonstrate an enlarged and hypoechogenic epididymis on the affected side. If there is associated orchitis, the testis will also be comparatively hypoechogenic. Chronic epididymitis may have both hypo- and hyperechogenic areas.
2. **Cyst in the epididymis**. Cysts may be single or multiple, and are confined to the epididymis. The testis will not be affected. Epididymal cysts must be differentiated from the more tubular varicocele.

Testicular trauma



Testicular trauma accounts for less than 1% of all trauma-related injuries, because of the anatomic location and mobility of the scrotum. Direct trauma to the scrotum, typically during a sporting injury or other similar mechanism is the commonest form of scrotal injury followed by motor vehicle collision and penetrating injuries. Scrotal trauma patients present with acute pain, and accurate diagnosis is necessary to minimize complications and prevent loss of the testis. A thorough history and detailed physical examination are essential for an accurate diagnosis. High-resolution USG with Doppler flow evaluation is the investigation of choice for the evaluation of scrotal abnormalities. It is noninvasive and can be used to quickly evaluate scrotal contents, testicular integrity and blood flow.

Testicular trauma



It is the third most-common cause of acute scrotal pain and may result in various degrees of damage to the testes. Testicular trauma can be blunt or penetrating in cause. Also, iatrogenic injury from surgery (e.g. incorrect site, inguinoscrotal surgery) can occur. Associated extratesticular injuries (e.g. epididymis rupture, epididymitis, scrotal wall hematoma, hematoceles) can also commonly occur. USG in scrotal trauma reveals a wide spectrum of morphology, ranging in severity from simple scrotal wall edema to testicular rupture and infarction. As the management is determined by the severity of the injury, it is important for the sonologist to be well versed with the appearance of each type of injury along this spectrum. Accurate USG diagnosis is therefore the essence of appropriate therapy in scrotal trauma.

Testicular trauma



Following injury, the testis may be enlarged or remain normal in size. When there is excess fluid in the scrotum, the testis should be scanned at many different angles to exclude rupture. The injured testis may show complex echogenicity, especially when there is an internal haematoma (or subsequent abscess). **Blood** will appear as fluid within the scrotum, often with complex echogenicity due to blood clots

Torsion of the testis



It may be difficult to confirm torsion of the testis with ultrasound, but if the rotation has disrupted the normal blood supply, ultrasound will demonstrate decreased echogenicity, compared with the normal testis, in the acute stage. There may be associated scrotal fluid (hydrocele).

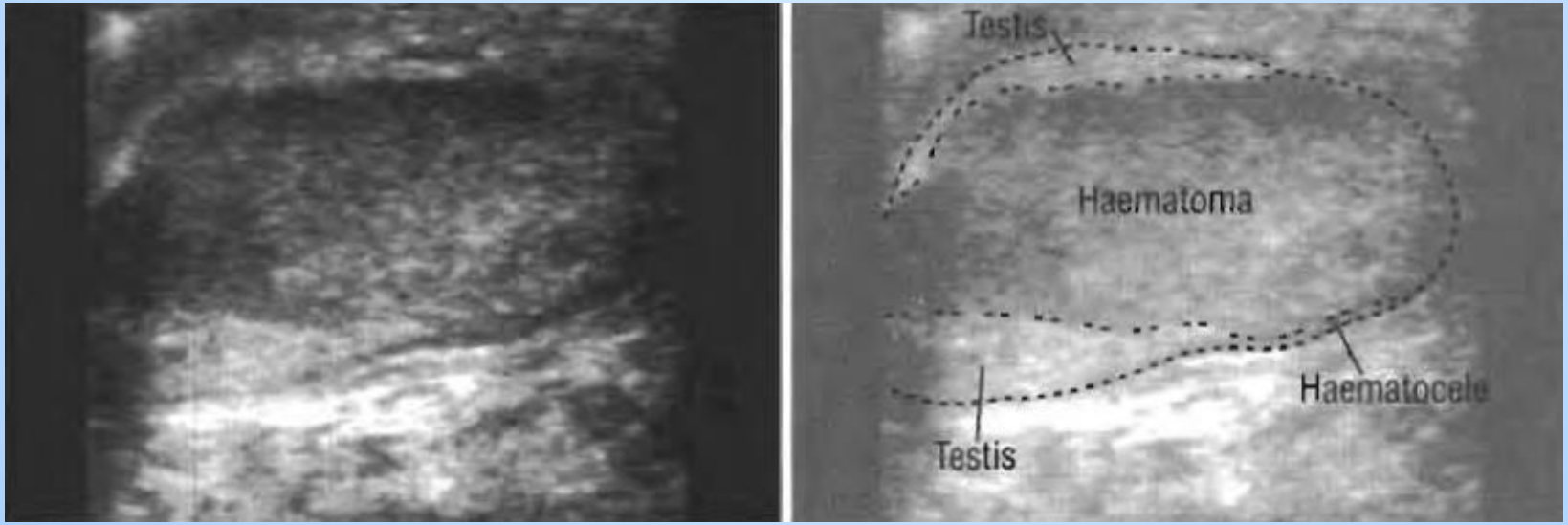

Figure: Longitudinal scan: a haematoma of the testis without disruption (fracture) but with a small haematocele.

Hernia



Omenta, mesentery or intestinal loops that have prolapsed through an inguinal hernia into the scrotum are usually associated with a small hydrocele. The loops of bowel will appear on ultrasound as a complex mass within the echo-free fluid. If there is a significant solid content within the bowel, there will be hyperechogenic areas also

Varicocele



When the veins draining the testis and epididymis are dilated, ultrasound will demonstrate multiple tortuous, tubular, hypoechogenic structures around the periphery of the testis, which is often smaller than the normal testis. Varicocele is more common on the left side: there may be associated infertility. The underlying testis must be scanned to exclude a tumor and varicocele must be differentiated from Spermatocele. A Val salva manoeuvre will often cause the veins to dilate.


Thank you