

Abnormal liver

Hayder Jasim Taher

PhD of Medical Imaging



Outline of my presentation

- ✓ Enlarged liver/hepatomegaly: homogeneous pattern
- ✓ Enlarged liver: non homogeneous pattern
- ✓ Small liver/shrunken liver

Enlarged liver/hepatomegaly: homogeneous pattern



When the liver is enlarged but has a normal diffuse homogeneous echo pattern, consider the following:

1- Congestive cardiac failure : The hepatic veins will be dilated. The inferior vena cava does not vary on respiration. Look for a pleural effusion above the diaphragm

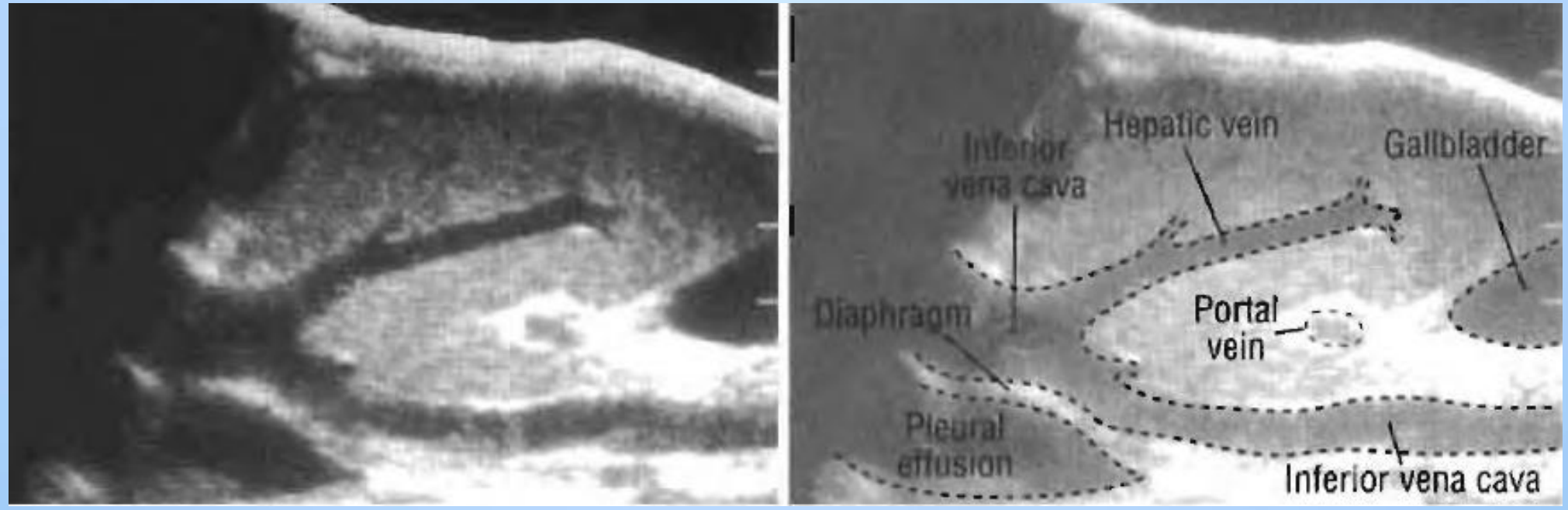

Enlarged liver/hepatomegaly: homogeneous pattern



2- Acute hepatitis : There are no characteristic sonographic changes, but the liver may be enlarged and tender.

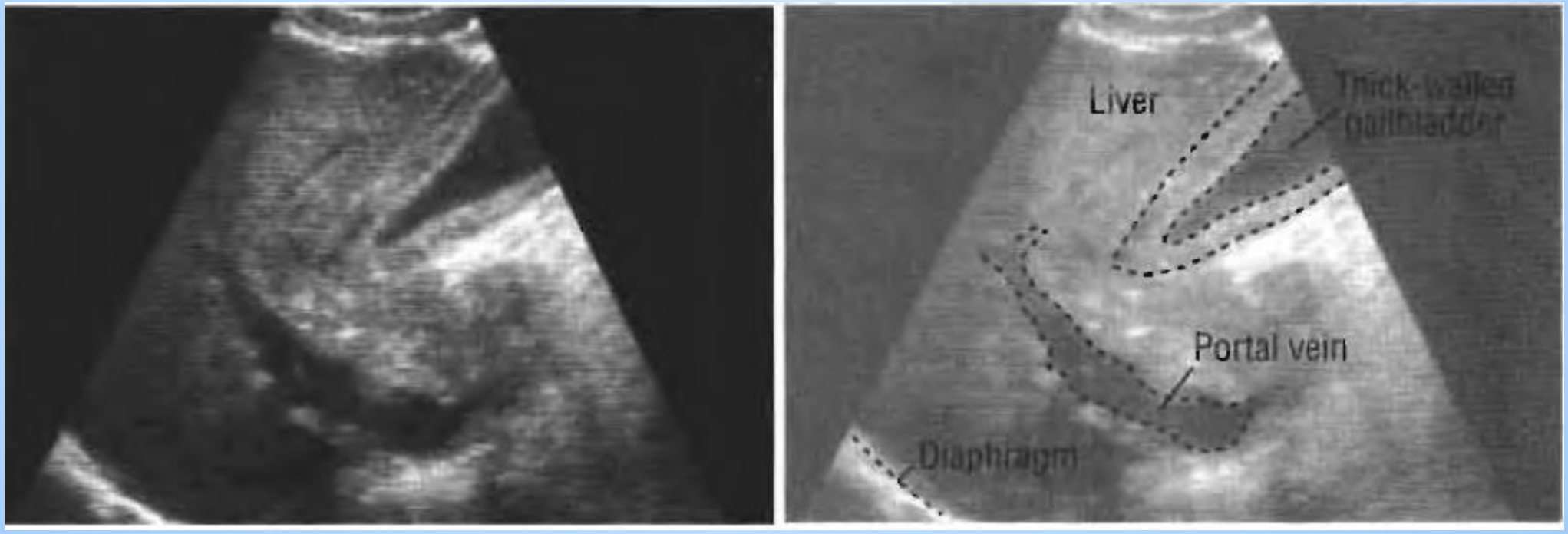

Enlarged liver/hepatomegaly: homogeneous pattern



3- Tropical hepatomegaly : The only significant finding is liver enlargement, usually associated with splenomegaly.

4- Schistosomiasis : The liver can be either sonographic ally normal or enlarged, with thickening of the portal vein and the main branches, which become highly echogenic, especially around the porta hepatishepatis.

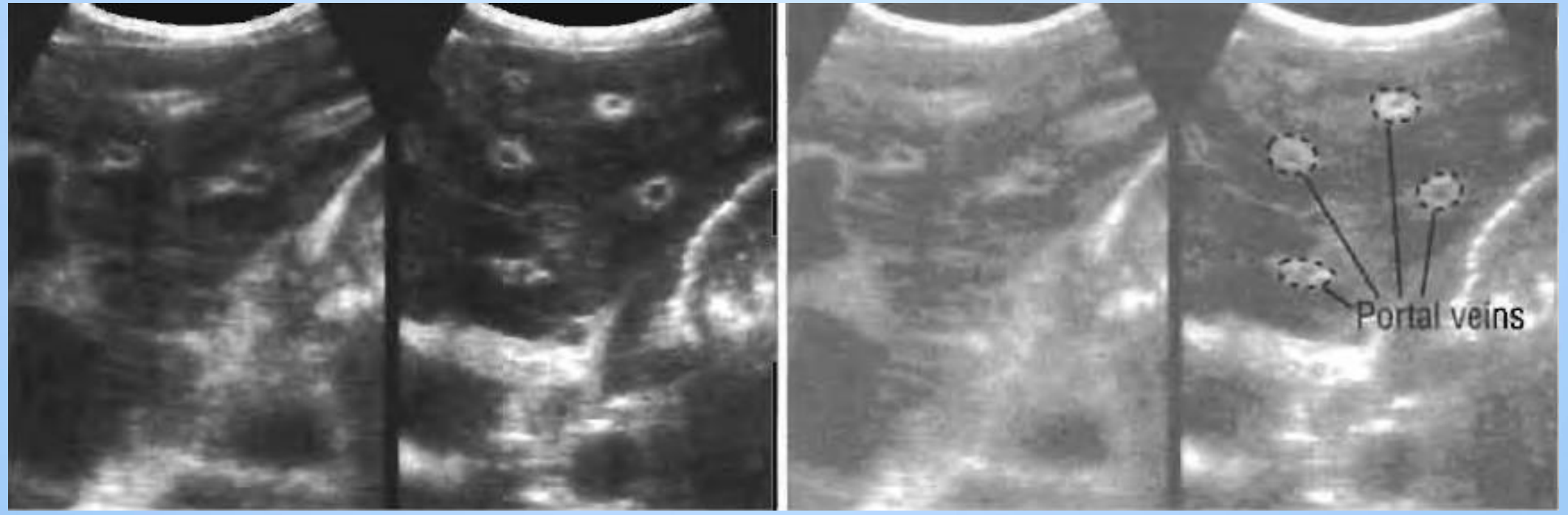

Enlarged liver: non homogeneous pattern



1- Without discrete masses : when there is increased echogenicity in the liver parenchyma, with loss or the highly reflective edges or the peripheral portal veins, cirrhosis, chronic hepatitis or a fatty liver should be suspected.





Enlarged liver: non homogeneous pattern



2- With multiple echogenic masses : Multiple masses of various Sizes, shapes and echo textures, producing a non homogeneous echo pattern throughout the liver, are consistent with.

- **Macronodular cirrhosis** The liver is enlarged with echogenic masses of various sizes but with normal interven ing tissue.

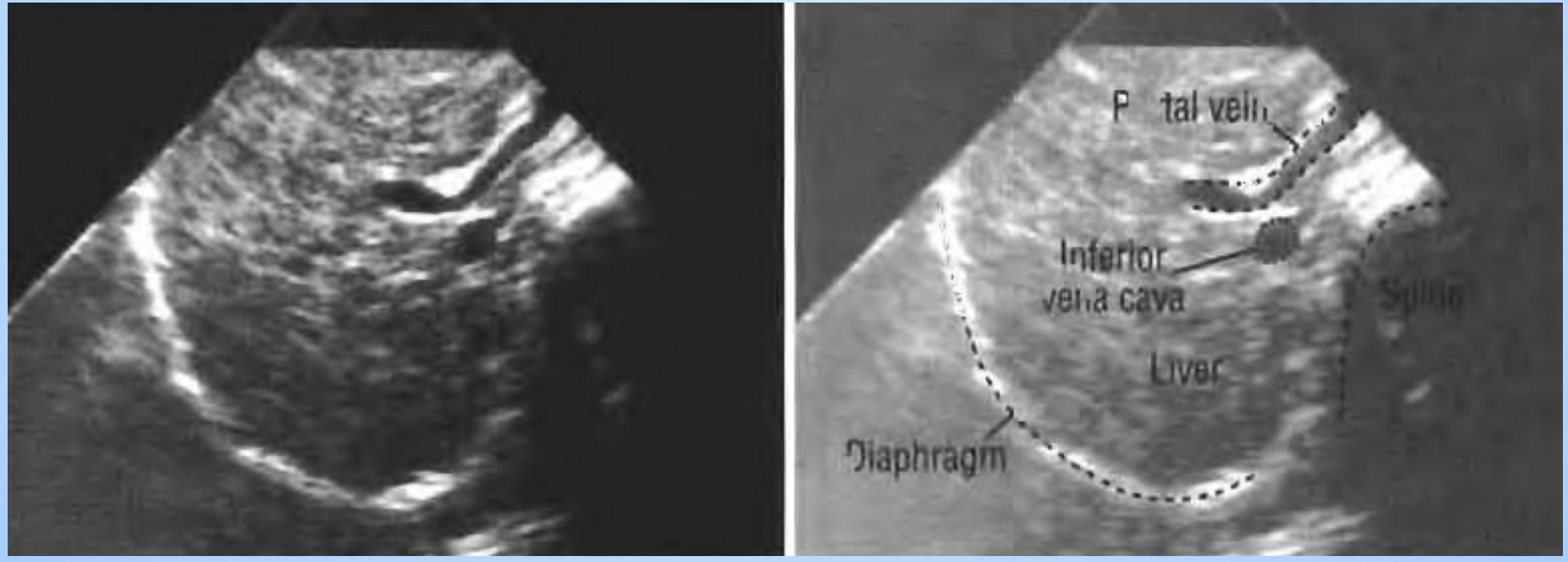

Enlarged liver: non homogeneous pattern



- **Multiple abscesses** These are usually ill defined, with strong back wall echoes and internal echoes.

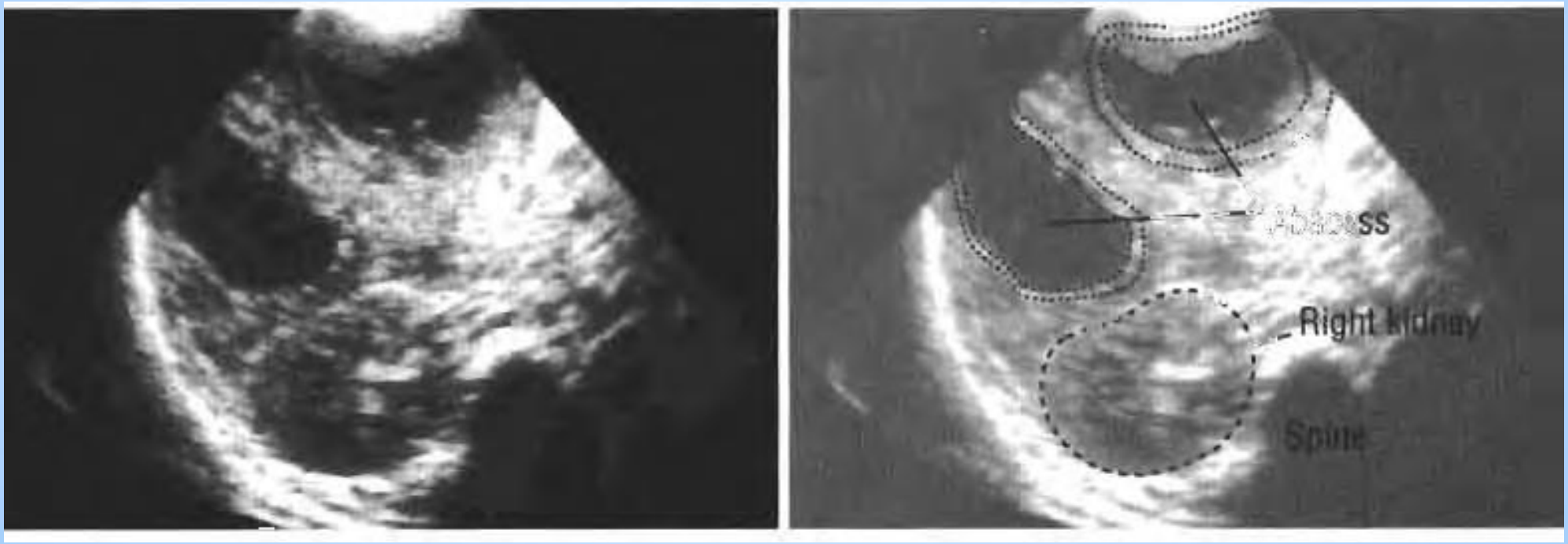

Enlarged liver: non homogeneous pattern



- **Multiple metastases** These may be hyperechogenic or hypo echogenic and well circumscribed or ill defined, or both.Metastases are often more numerous and more variable in size than abscesses: multinodular hepatocarcinoma can resemble metastases.

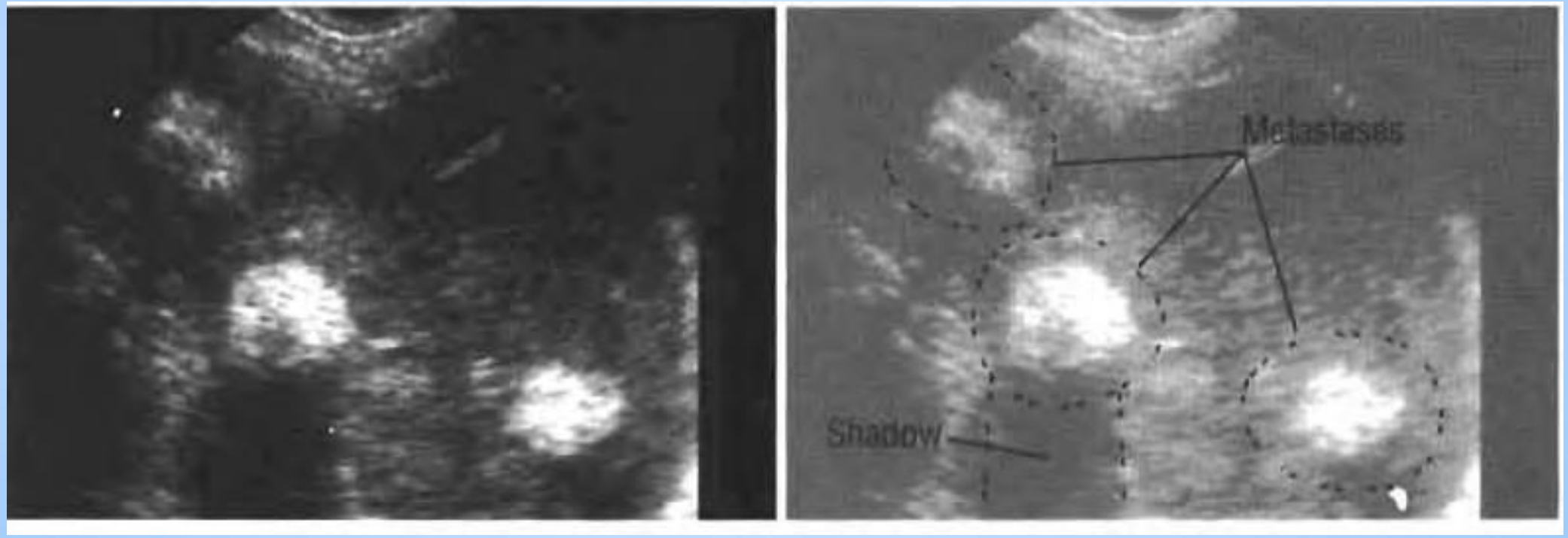

Enlarged liver: non homogeneous pattern



- **Lymphoma :** This may be considered when there are multiple hypoechogenicm masses in the liver, usually with irregular outlines and without associated acoustic enhancement. It is not possible to distinguish be tween lymphoma and metastases by ultrasound.

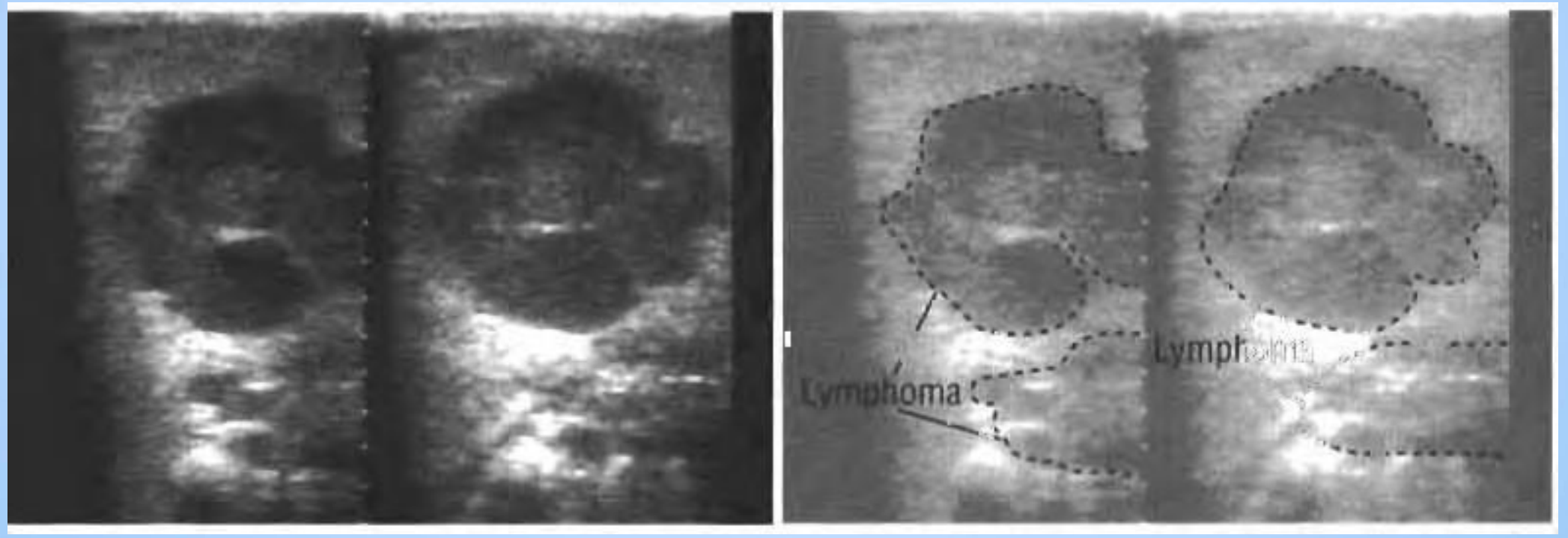

Enlarged liver: non homogeneous pattern



- **Haematomas:** These are often irregular in outline, with acoustic enhancement. However, when blood has clotted, the haematomas may be hyperechogenic. It is important to obtain a clinical history of either trauma o r anticoagulant medication.

Small liver/shrunken liver



A diffusely increased echogenicity and distorted portal and hepatic veins in a shrunken liver are usually due to micronodular cirrhosis. This is often associated with portal hypertension, splenomegaly, ascites, dilated splenic veins and multiple varices.

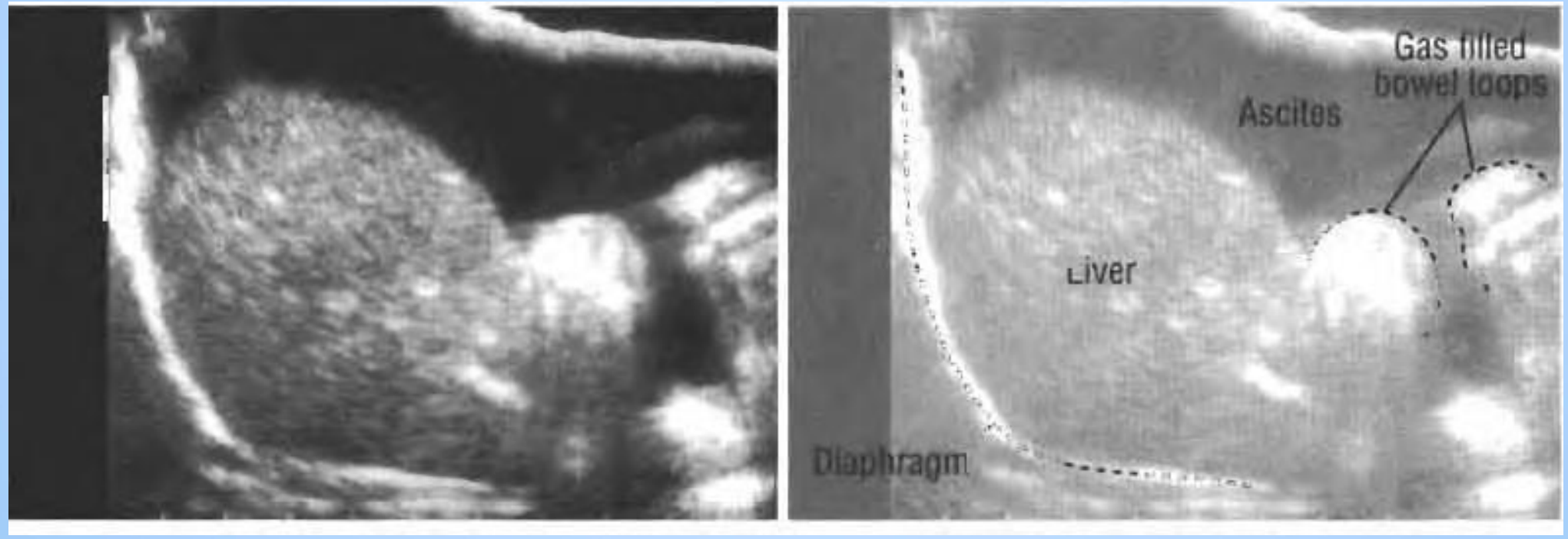

Q



- **What are the sonographic features of multiple echogenic masses in the liver?**

Thank you