

Cystic lesions in normal or large liver

Hayder Jasim Taher

PhD of Medical Imaging



Outline of my presentation

- ✓ Cystic lesions in normal or large liver.
- ✓ Differential diagnosis of liver masses.
- ✓ Trauma to the liver.

Introduction:



- Simple hepatic cysts are common benign liver lesions and have no malignant potential. They can be diagnosed with ultrasound, CT, or MRI.
- Simple hepatic cysts are one of the commonest liver lesions, occurring in ~ (range 2 7% of the population. There may be a slight female predilection.
- Hepatic cysts are typically discovered incidentally and are almost always asymptomatic. They can demonstrate slow growth over time, although rapid size increase may be caused by internal hemorrhage.

Introduction:



- Simple hepatic cysts may be isolated or multiple and may vary from a few millimeters to several centimeters in diameter. Simple hepatic cysts are benign developmental lesions that do not communicate with the biliary tree 2.
- The current theory regarding the origin of true hepatic cysts is that they originate from hamartomatous tissue. On histopathological analysis, true hepatic cysts contain serous fluid and are lined by a nearly imperceptible wall consisting of cuboidal epithelium, identical to that of bile ducts, and a thin underlying rim of fibrous stroma While they can occur anywhere in the liver, there may be a greater predilection towards the right lobe of the liver

Cystic lesions in normal or large liver



• **Well defined solitary cyst** A well rounded, echo free mass with acoustic enhancement, usually less than 3 cm in diameter, and often a chance finding without symptoms, is likely to be a solitary simple congenital cyst. A small hydatid cyst must also be excluded and cannot always be differentiated sonographically.

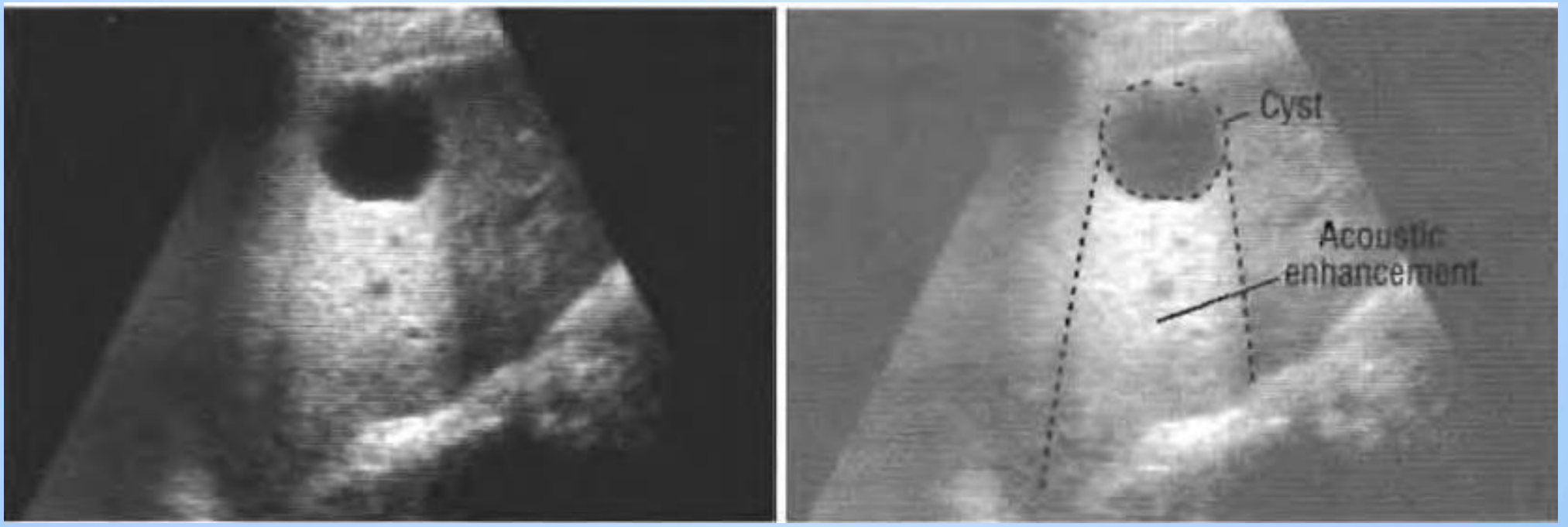

Transverse scan: a simple hepatic cyst with a sharp outline and acoustic enhancement.

Enlarged liver/hepatomegaly: homogeneous pattern



- **Solitary cyst with a rough irregular outline** See liver abscess.
- **Multiple cystic lesions** Multiple spherical cystic masses of varying sizes, completely echo free with a sharp outline and posterior acoustic enhancement, may indicate congenital polycystic disease. Search for cysts in the kidney, pancreas and spleen; congenital cystic disease can be very difficult to differentiate from hydatid disease.
- **Complex cyst** Haemorrhage or infection of any cyst may result in internal echoes and resemble an abscess or necrotic tumour.
- **Echinococcal cyst** Hydatid disease can present a broad spectrum of sonographic features.

Differential diagnosis of liver masses, Trauma of the liver



- Because abdominal ultrasonography is both noninvasive and inexpensive, currently, it is the imaging method used most frequently to screen for liver tumors. Ultrasonography can effectively identify a liver mass of 5 mm and is valuable to differentiate cystic from solid lesions.
- Liver cirrhosis results from hepatocellular necrosis, fibrosis, and regeneration. Because regenerative nodules are common in liver cirrhosis, the most important clinical problem is to distinguish a regenerative nodule from a small HCC. On liver ultrasonography, regenerative nodules are small, hypoechoic nodules.

Differential diagnosis of liver masses, Trauma of the liver



Liver lesions represent a heterogeneous group of pathology ranging from solitary benign lesions to multiple metastases from a variety of primary tumors.

Liver lesions may be infiltrative or have mass effect, be solitary or multiple, benign or malignant.

Assessment of liver lesions takes into consideration their appearance and vascularity on a variety of imaging modalities:

- cystic liver lesions
- Hyper-vascular liver lesions
- liver tumors

The differential diagnosis for pediatric liver lesions is different to that for an adult.

Differential diagnosis of liver masses



- It may be difficult to distinguish hepatocellular carcinoma from multiple liver metastases or abscesses. Primary carcinoma usually develops as one large dominant mass, but there may be multiple masses of various sizes and patterns, which may have a hypo-echogenic rim. The centre may become necrotic and appear quite cystic, with fluid filled cavities and thick, irregular margins.

- It can be very difficult to distinguish such tumours from abscesses

A single solid mass in the liver



Many different diseases may cause a solitary, solid mass in the liver. The differential diagnosis may be very difficult and may require biopsy. A solitary, well defined hyper-echogenic mass close to the liver capsule may be a haemangioma: 75% of haemangiomas have posterior acoustic enhancement without acoustic shadowing, but when large may lose hyperechogenicity and cannot be easily differentiated from a primary malignant liver tumour. Occasionally there will be multiple haemangiomas, but they do not usually produce clinical symptoms.

A single solid mass in the liver



It can be very difficult to differentiate a hamangioma from a solitary metastasis, abscess, or hydatid cyst. A lack of clinical symptoms strongly suggests haemangioma. To confirm the diagnosis, either computerized tomography, angiography, magnetic resonance imaging o r radionuclide scanning with labelled red blood cells will be necessary.

A single homogeneous mass with a low level echo around the periphery is probably a hepatoma.

However, hepatomas may also present with central necrosis or as a diffuse mass.

Liver abscess



It is very difficult to differentiate between a bacterial abscess, an amoebic abscess and an infected cyst. All may be either multiple or single, and usually present as hypochogenic masses with strong back walls, irregular outline and internal debris, There may be internal gas.

Subphrenic and subhepatic abscesses



- A predominantly echo free, sharply delineated, crescentic area between the liver and the right hemidiaphragm may be due to a right sided subphrenic abscess.
- When using ultrasound to search for the cause of pyrexia of unknown origin, or postsurgical pyrexia, both left and right subphrenic regions should be examined.
- The posterior aspect of the lower chest should also be scanned to exclude an associated pleural effusion.
- Occasionally, a subphrenic abscess may extend to the subhepatic space, most commonly between the liver and the kidney.

Trauma to the liver



Haematomas

Ultrasound can reliably detect intrahepatic haematomas, which vary from hyperechogenic to hypoechogenic. However, the cl inical history and symptoms may be needed to differentiate haematomas from abscesses.

Subcapsular haematomas present as an echo free or complex (due to blood clots) area located between the capsule of the liver and the underlying liver parenchyma.

Extraca psular haematomas present as an echo free or complex (due to blood clots) area adjacent to the liver but lying outside the capsule.

Trauma to the liver



Bilomas

Fluid within or around the liver may be bile, resulting from trauma to the biliary tract. It is not possible to distinguish biloma from haematoma by ultrasound imaging.

Q



- What are the sonographic features of cystic lesions seen in the liver?
- What are the types of cystic lesions in the liver?
- How to differentiate the liver lesions by ultrasound?

Thank you