

Normal and abnormal pancreas

Hayder Jasim Taher

PhD of Medical Imaging



Outline of my presentation

- ✓ Introduction
- ✓ Indications.
- ✓ Normal pancreas.
- ✓ Small pancreas.
- ✓ Diffuse enlargement of the pancreas.
- ✓ Focal enlargement .
- ✓ Pancreatic cysts.
- ✓ Calcification in the pancreas.
- ✓ Dilatation of the pancreatic duct

Introduction



Pancreatic ultrasound can be used to assess for pancreatic malignancy, pancreatitis and its complications, as well as for other pancreatic pathology. As ultrasound (US) is simple and less invasive than other imaging modalities, this technique is widely used for mass screening. However, visualizing the entire pancreas due to complicated anatomy, obesity and overlying gas can be difficult. US plays a key role in the diagnosis of pancreatic carcinoma (PC). To detect these forms of PC, main pancreatic duct (MPD) dilatation (3 mm or more) and pancreatic cysts (5 mm or larger) are US findings of high-risk individuals (HRIs), and these subjects should be observed periodically. Scanning maneuvers are also important for both screening for PC and follow-up of HRIs. As lesions in the groove area and ventral pancreas do not affect the MPD or extrahepatic bile duct, we should pay attention to these areas. Visualization of the tail is also challenging due to gas and stool in the alimentary tract. As the position of the pancreas changes depending on the body posture, and several different body positions should be employed, such as the right lateral decubitus, sitting, and upright positions, rather than only applying strong compression with the transducer. In cases with poor visualization, the liquid-filled stomach method is highly recommended.

Indications



1. Midline upper abdominal pain, acute or chronic.
2 . Jaundice.
3. Upper abdominal mass.
4. Persistent fever, especially with upper abdominal tenderness.
5. Suspected malignant disease.
6. Recurrent chronic pancreatitis.
7. Suspected complications of acute pancreatitis, especially pseudocyst or abscess.
8. Polycystic kidneys: cysts in the liver or spleen.
9. Direct abdominal trauma, particularly in children.

Gas



If bowel gas obscures the image:

- Try gentle compression with the transducer or use decubitus views, both right and left.
- If necessary, give the patient 3 or 4 glasses of water, wait a few minutes to allow the bubbles to disperse and then repeat the examination with the patient sitting or standing, viewing the pancreas through the water-filled stomach.
- If the patient cannot stand, let him or her lie on the left side and drink through a straw. Then scan with the patient supine

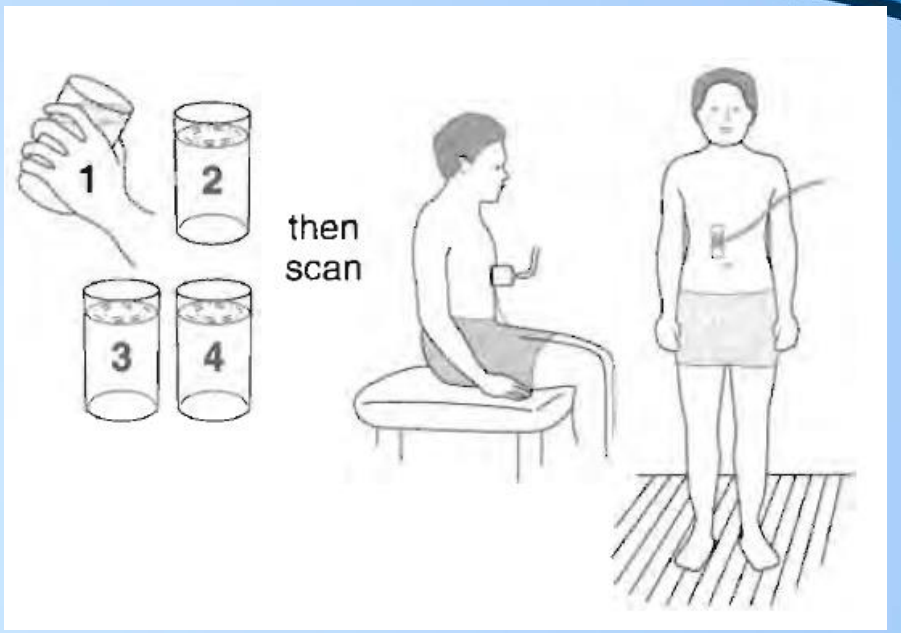



Transverse scanning



Start with transverse scans across the abdomen moving downwards towards the feet until the splenic vein is seen as a linear, tubular structure with the medial end broadened. This is where it is joined by the superior mesenteric vein , at the level of the body of the pancreas . The superior mesenteric artery will be seen in cross-section just below the vein. By angling and rocking the transducer, the head and the tail of the pancreas may be seen.

Continue transverse scans downwards to visualize the head of the pancreas and the uncinate process (if present) between the inferior vena cava and the portal vein.

Imaging the entire pancreas is often difficult. Different positions and scanning angles must be used.

Transverse scanning

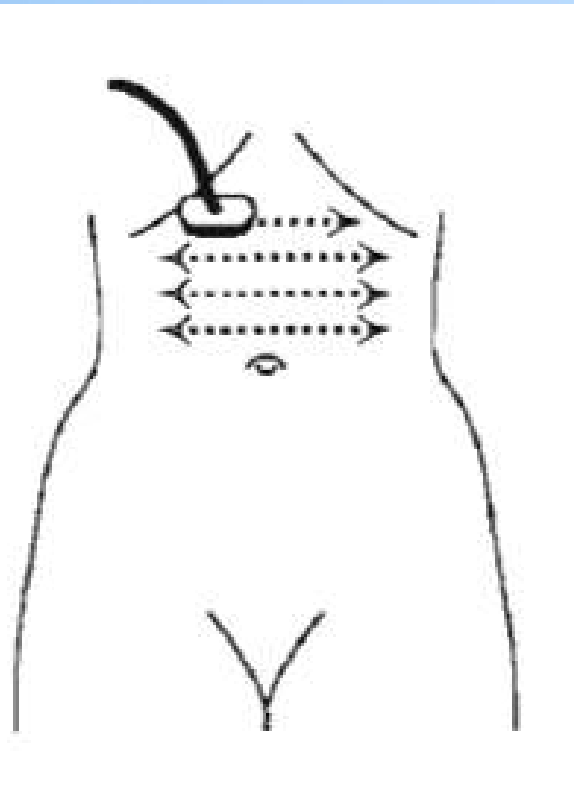

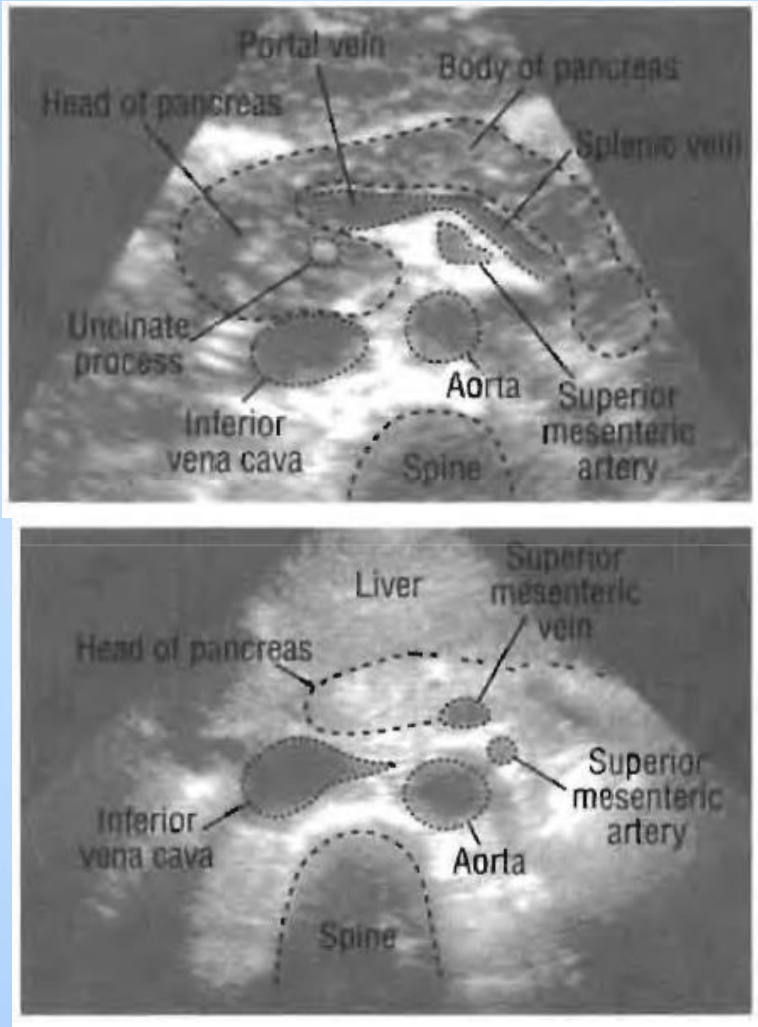

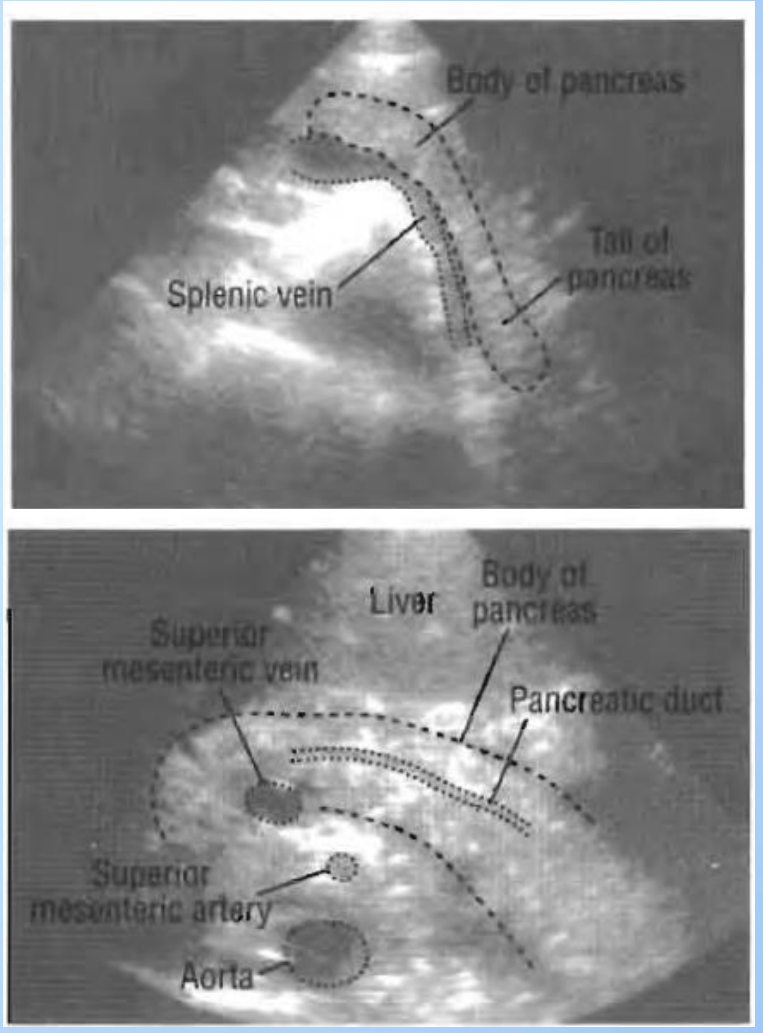

Normal pancreas



The pancreas has about the same echogenicity as the adjacent liver and should appear homogeneous. However, the pancreatic echogenicity increases with age. The outline of the normal pancreas is smooth.
When scanning the pancreas, certain anatomical landmarks should be identified, in the following order:

1. Aorta
2. Inferior vena cava
3. Superior mesenteric artery
4. Splenic vein
5. Superior mesenteric vein
6. Wall of the stomach
7. Common bile duct

The essential landmarks are the superior mesenteric artery and the splenic vein.

Normal pancreatic size



There is great variability in the size and shape of the pancreas. The following guidelines may be helpful.

- The average diameter of the head of the pancreas: 2.8 cm.
- The average diameter of the medial part of the body of the pancreas: less than 2 cm.
- The average diameter of the tail of the pancreas: 2.5 cm.
- The diameter of the pancreatic duct should not exceed 2 mm.

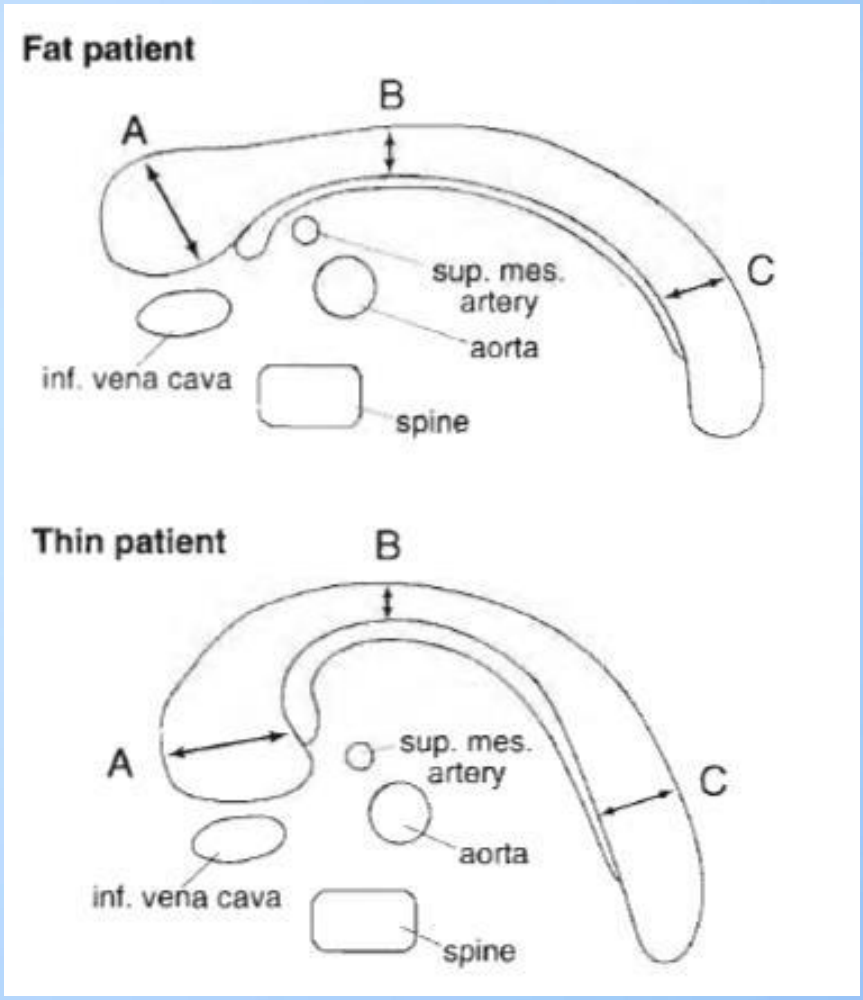

Small pancreas



The pancreas is usually smaller in elderly people, but this is not of clinical significance. When there is overall atrophy of the pancreas, the decrease in size is usually uniform throughout the pancreas. If there appears to be atrophy of the tail of the pancreas alone (the head appearing-normal), then a tumour in the head of the pancreas must be suspected. The head must be scanned carefully because chronic

pancreatitis in the body and tail may be associated with a slow- growing tumour in the head of the pancreas (Fig-7).

If the pancreas is small and irregularly hyperechogenic and non- homogeneous compared with the liver, the cause is usually chronic pancreatitis.

Small pancreas

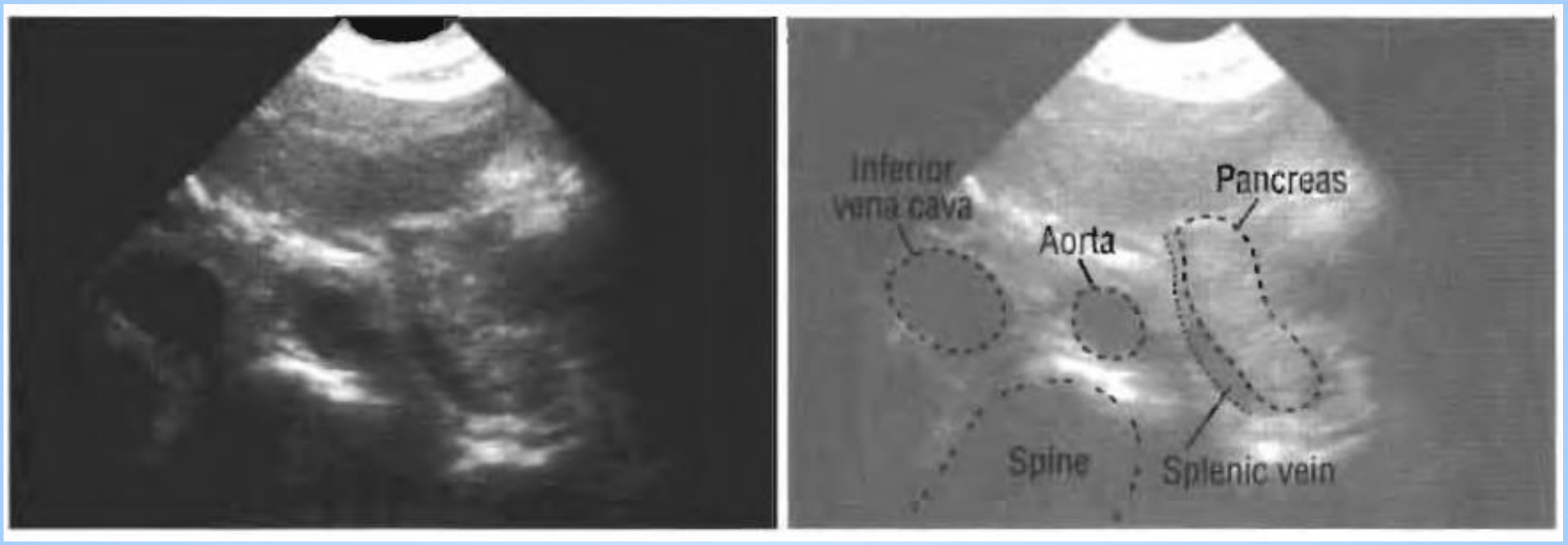

Atrophy of the tail of the pancreas.

Small pancreas

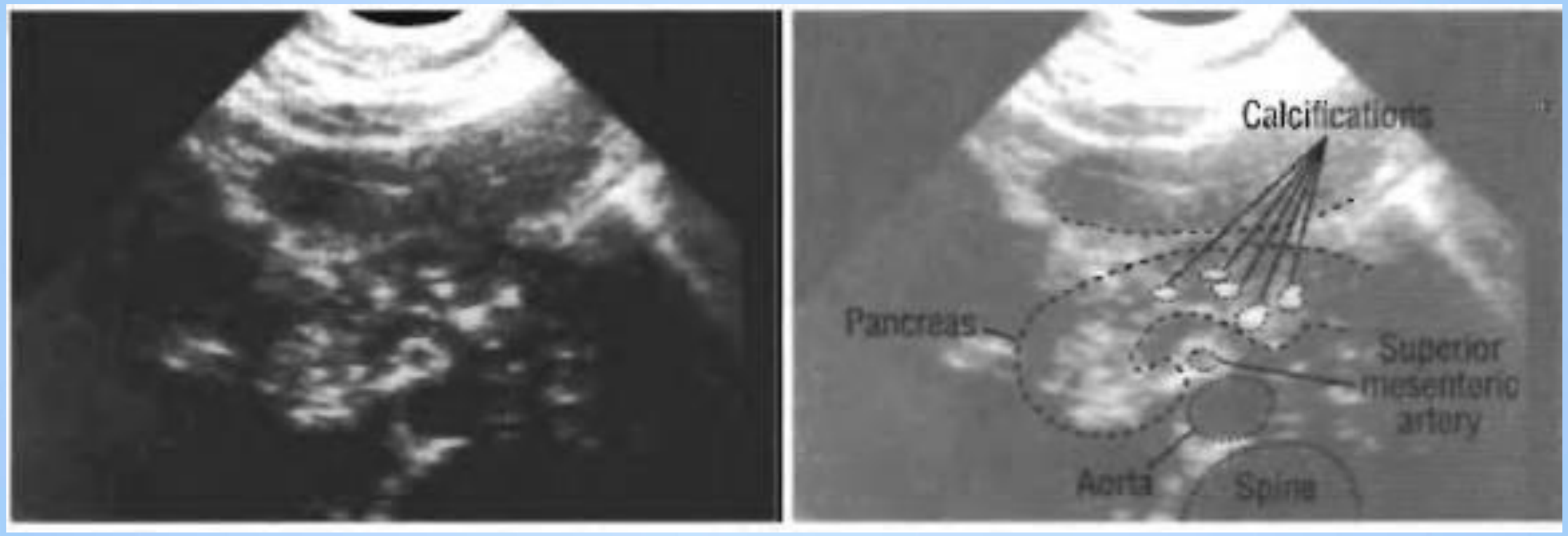

Fig-7: A small. nonhomogeneous pancreas with calcifications due to chronic pancreatitis

Diffuse enlargement of the pancreas



In acute pancreatitis, the pancreas may be diffusely enlarged and either normal or hypochogenic compared with the adjacent liver. The serum amylase is usually elevated, and there may be local ileus due to bowel irritation.

When the pancreas is irregularly hyperechogenic and diffusely enlarged, there is usually acute pancreatitis superimposed on chronic pancreatitis.

Focal enlargement (noncystic)



Almost all pancreatic tumours are hypochogenic compared with the normal pancreas. It is not possible to distinguish between focal pancreatitis or pancreatic tumour by ultrasound alone. Even if the serum amylase is elevated, repeat the ultrasound examination in 2 weeks to assess the change. Tumour and pancreatitis can co-exist. When the pattern is mixed, biopsy is needed.

	Tumour	Acute pancreatitis, diffuse or local	Chronic pancreatitis	Aging normal pancreas
Echogenicity relative to the adjacent liver	Low	Low	High	High

Ultrasound cannot distinguish focal pancreatitis from a pancreatic tumour.

Pancreatic cysts



True pancreatic cysts are rare. They are usually single, echo-free, smooth cavities filled with fluid. Small multiple cysts may be con- genital. An abscess or haematoma in the pancreas will appear as a complex mass, often associated with severe pancreatitis.

Pseudocysts following trauma or acute pancreatitis are not uncommon; they may increase in size and rupture. Such cysts can be single or multiple. In the early stages they are complex, with internal echoes and ill-defined walls, but eventually these cysts become smooth-walled and echo-free.

Pancreatic cystadenoma or other cystic tumours usually appear on ultrasound as multiseptate cystic masses with associated solid components. Hydatid cysts are unusual in the pancreas.

Calcification in the pancreas



Ultrasound is not the best way to assess pancreatic calcification. A supine anteroposterior radiograph of the upper abdomen is preferable.

Calcification within the pancreas can produce acoustic shadowing. However, fi the calcification is very small, there may only be bright discrete echoes without shadowing. Calcification is usually due to:

- Chronic pancreatitis.
- Calculi in the pancreatic duct.
- Biliary calculi in the distal common bile duct can be mistaken for pancreatic calcification. There is usually dilatation of the proximal bile duct.

Dilatation of the pancreatic duct



The normal maximum internal diameter of the pancreatic duct is 2 mm.

The causes of dilatation of the pancreatic duct are:

• Tumour of the head of the pancreas or of the ampulla of Vater. Both are usually associated with jaundice and dilatation of the biliary tract.

- Calculus in the common pancreatic duct.
- Calculus in the intrapancreatic duct.
- Chronic pancreatitis
- Postoperative strictures following Whipple's operation or partial pancreatectomy.

The clinical history should be verified with the patient or relatives if necessary.

Thank you