

Normal and abnormal spleen

Hayder Jasim Taher

PhD of Medical Imaging



Outline of my presentation

- ✓ Introduction
- ✓ Indications.
- ✓ Normal spleen.
- ✓ Abnormal spleen.
- ✓ Trauma.

Introduction



The spleen is an organ of the hematological system and has a role in immune response, storage of red blood cells and hematopoiesis. The spleen is a wedge shaped organ lying mainly in the left upper quadrant (left hypochondrium and partly in the epigastrium) and is protected by the left 9th to 11th ribs. It is soft, highly vascular and dark purple in color. Size and weight vary from person-to-person but on average is around 2.5 cm thick, 7.5 cm broad and 12.5 cm in length. For pediatric measurements, see the article spleen size (pediatric). The spleen has two poles (superior and inferior), three borders (superior, inferior and intermediate) and two surfaces (diaphragmatic and visceral). It is enclosed by a thin capsule, which is easily ruptured. The spleen is completely covered by peritoneum, except at the hilum, which forms a number of ligaments.

Indications



- Splenomegaly (enlarged spleen)
- Left abdominal mass
- Blunt abdominal trauma
- Left upper abdominal pain (an erect abdominal X-ray, including both sides of the diaphragm, is also needed if perforation of the bowel is suspected)
- Suspected subphrenic abscess (pyrexia of unknown origin)
- Jaundice combined with anaemia
- Echinococcosis (hydatid disease)
- Ascites or localized intra-abdominal fluid
- Suspected malignancy, especially lymphoma or leukaemia.

Normal spleen



It is important to identify the:

- Left hemi-diaphragm.
- Splenic hilus.
- Splenic veins and relationship to pancreas.
- Left kidney (and renal/splenic relationship).
- Left edge of liver.
- Pancreas.

When the spleen is normal in size, it can be difficult to image completely (Fig-8).

Normal spleen

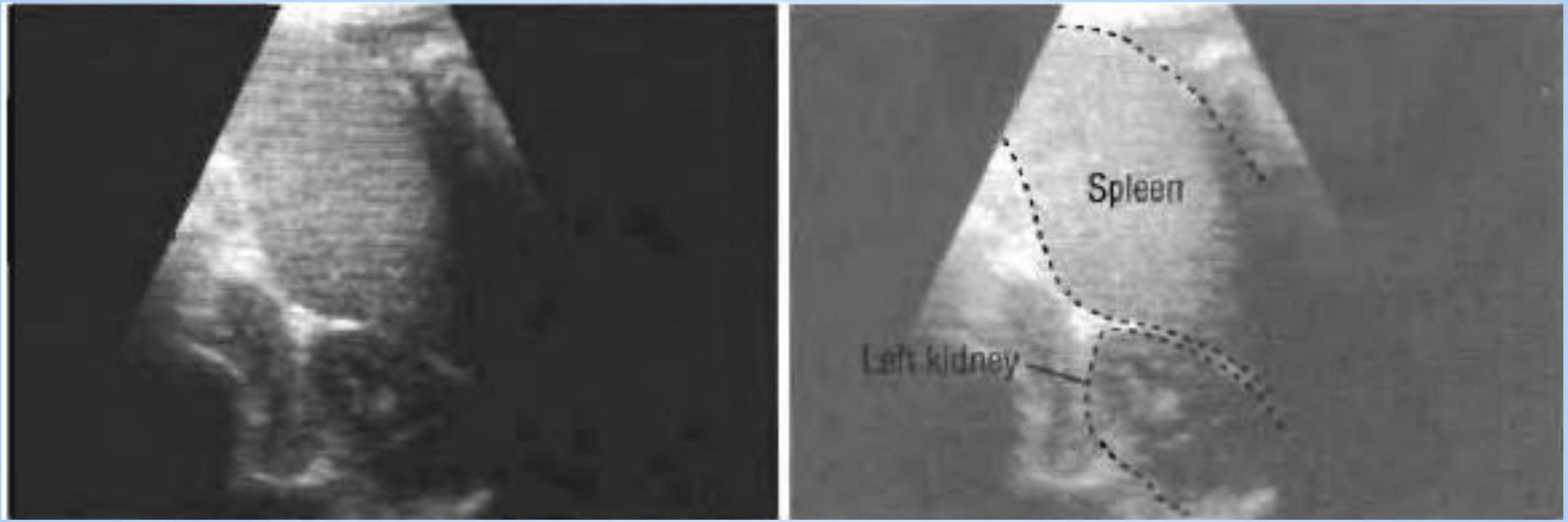

Fig-8: Oblique scan: normal spleen and left kidney

Echo pattern



The spleen should show a uniform homogeneous echo pattern. It is slightly less echogenic than the liver.

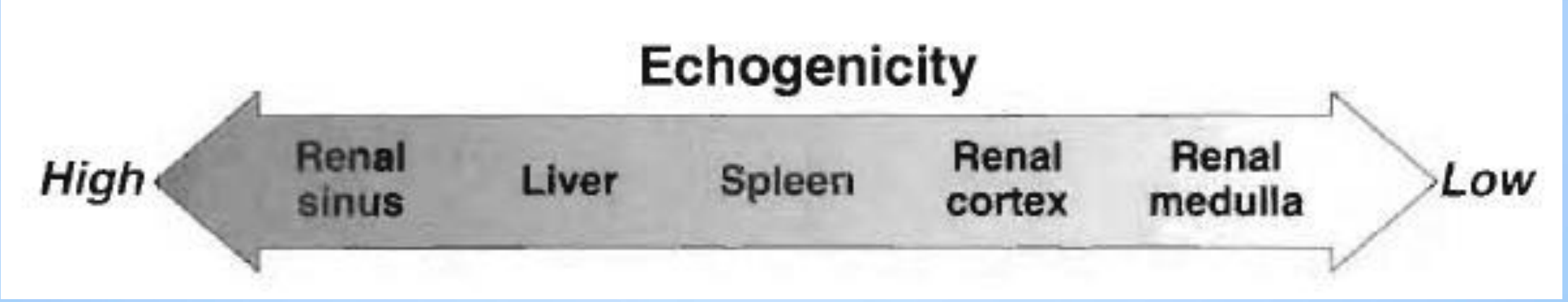

Abnormal spleen



Enlarged spleen/splenomegaly

There are no absolute criteria for the size of the spleen on ultrasound. When normal, it is a little larger than or about the same size as the left kidney. The length should not exceed 15 cm in the major axis. A chronically enlarged spleen may often distort and displace the left kidney.

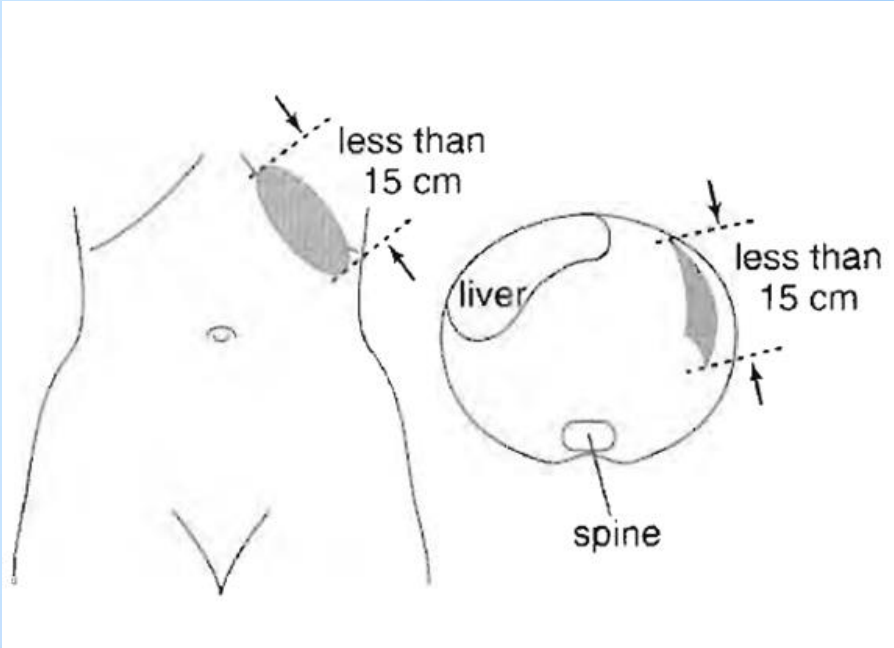

Abnormal spleen



Homogeneous splenomegaly

This may be due to:

- Tropical splenomegaly, which includes idiopathic splenomegaly, malaria, trypanosomiasis, leishmaniasis and schistosomiasis (Fig-9).
- Sickle cell disease (unless infarcted).
- Portal hypertension.
- Leukaemia.
- Metabolic disease.
- Lymphoma (may contain hyperechogenic masses).
- Infections such as rubella and mononucleosis.

Whenever there is splenomegaly, examine the liver for size and echogenicity. Also examine the splenic and portal veins, the inferior vena cava, hepatic veins and mesentery for thickening.

Abnormal spleen

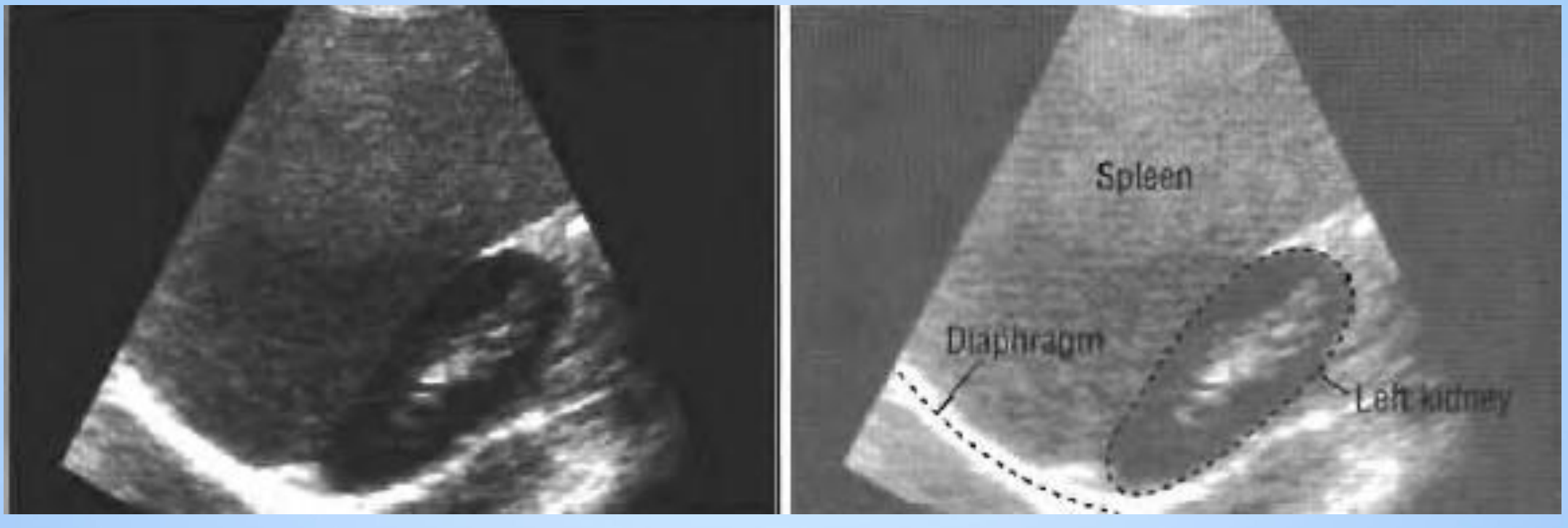

Fig-9: Longitudinal scan: gross splenomegaly (due to leishmaniasis) compressing the left kidney.

Non-homogeneous spleen, with or without splenomegaly



Well defined cystic lesion

If there is a clearly demarcated, echo-free mass with posterior acoustic enhancement, differentiate:

1. **Cystic disease (may be multiple).** Examine liver and pancreas for cysts.

2. **Congenital cysts.** These are usually solitary and may contain echoes as a result of haemorrhage

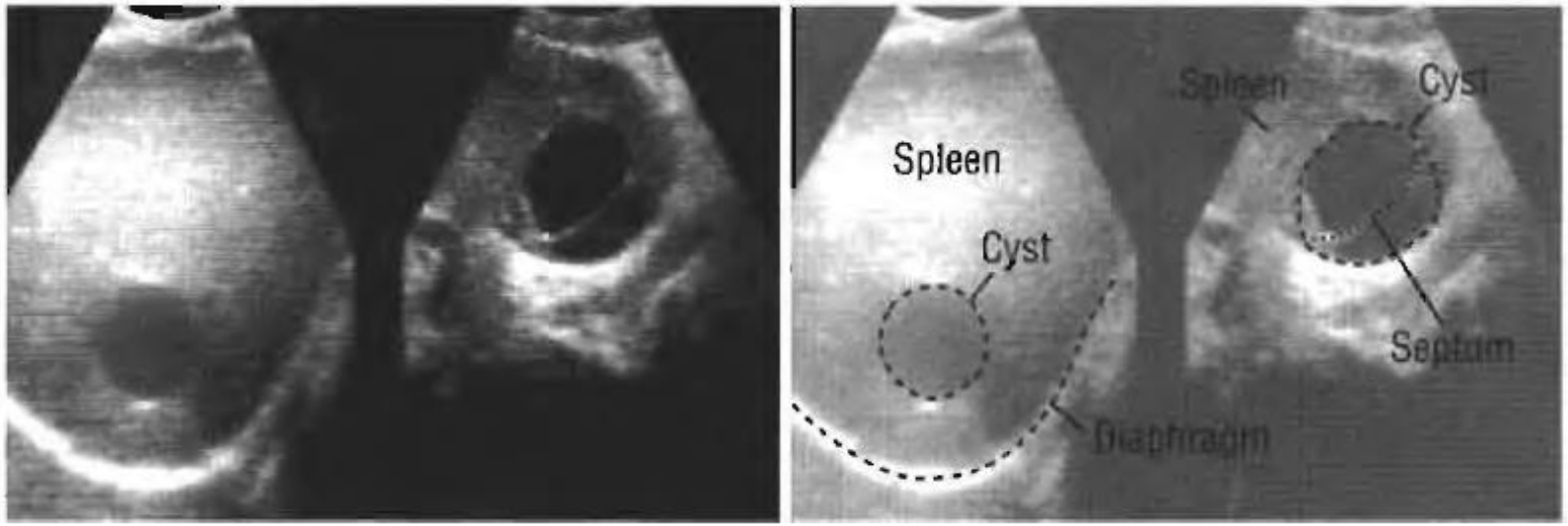

Fig. 80a. Longitudinal scans: a septate cyst in the spleen, found incidentally.

Non-homogeneous spleen, with or without splenomegaly



Well defined cystic lesion

3. Echinococcal (hydatid) cysts. These are usually clearly defined with a double wall (the pericyst and the cyst wall) and often septate. There will be markedly enhanced back wall echoes and often marked variation in the thickness of the wall of the cyst. However, hydatid cysts may appear as roughly rounded masses with an irregular contour and a mixed echo pattern resembling an abscess. The cyst can be hypochogenic with few irregular echoes or hyperechogenic and solid without any back wall shadow: combinations of these findings may occur. The walls of the-cyst may be collapsed or saggingan d there may be a floating density within the cyst, or even a cyst within a cyst (which is pathognomonic for hydatid disease).

There may be calcification within the wall of the cyst and there may be "sand" in the most dependent portion.

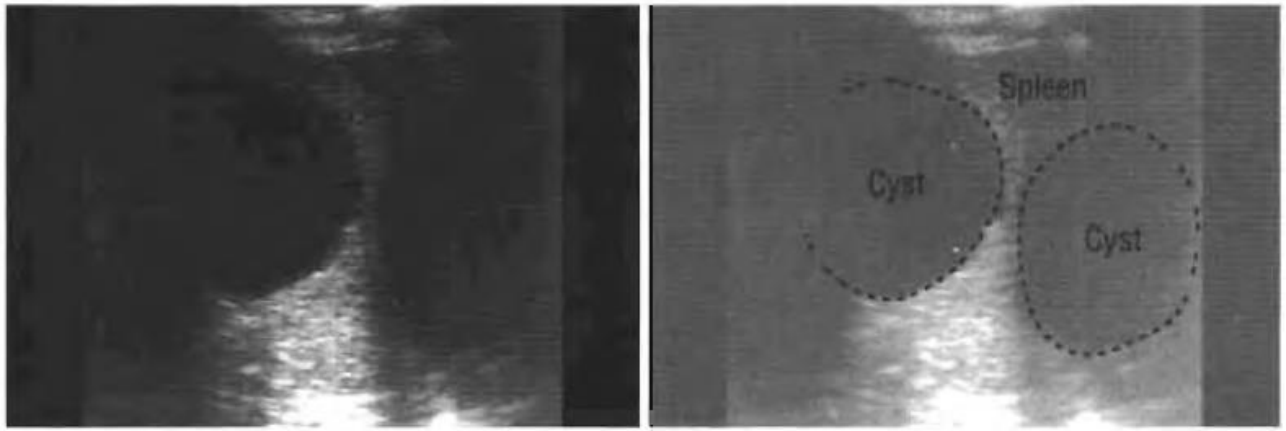

Fig. 80b. Hydatid cysts in the spleen.

Non-homogeneous spleen, with or without splenomegaly



4. Hematoma

If the spleen is enlarged, and there is a history of trauma, scan the spleen to exclude injury (see p. 134).

A regular but ill-defined cystic lesion in the spleen



Scan in different projections.

1. A hypoechogenic cystic area with an irregular outline, usually containing debris and associated with splenomegaly and local tenderness, suggests a splenic abscess. Examine the liver for other abscesses.After successful treatment, the abscess may resolve or become larger and almost echo-free, but is no longer tender.

2. A similar cystic lesion which is larger and contains fluid may be a splenic abscess following-infarction resulting from sickle cell disease. Amoebic abscesses are very rare in the spleen: bacterial abscesses are more common.

A regular but ill-defined cystic lesion in the spleen

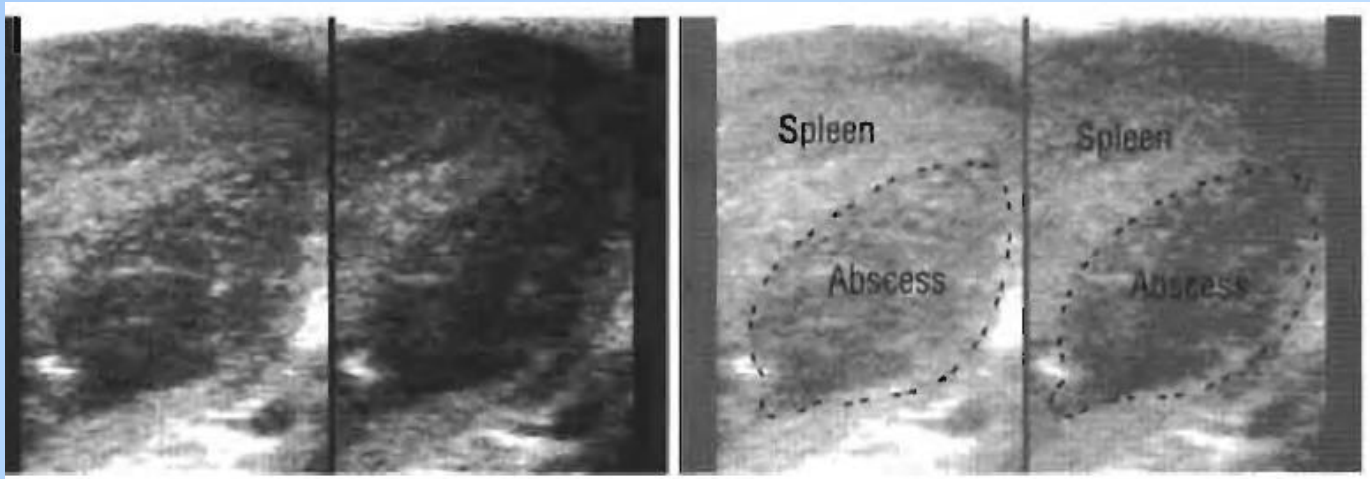

Fig. 81a. An early abscess in the spleen, before treatment.

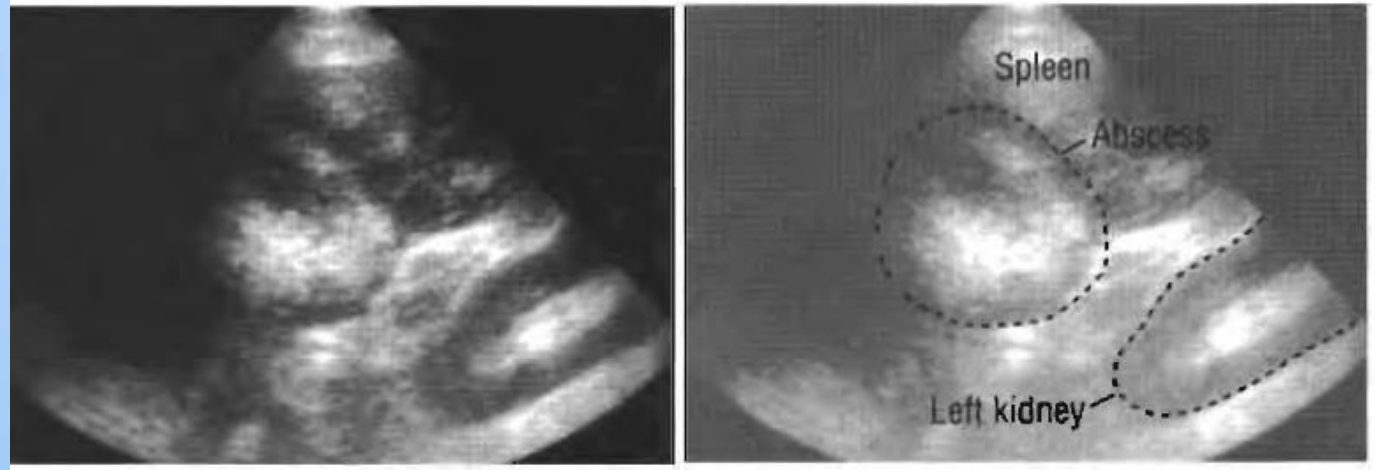

Fig. 81b. A splenic abscess after treatment.

Splenic vein



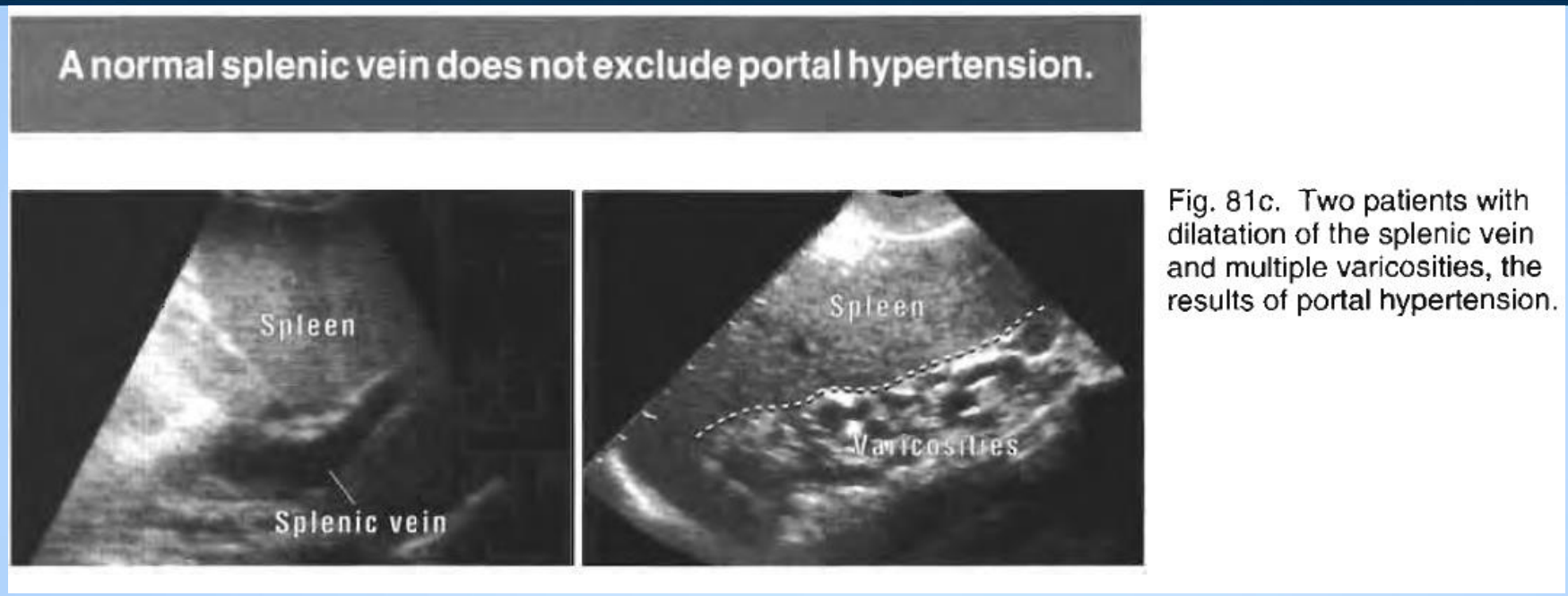

Fig. 81c. Two patients with dilatation of the splenic vein and multiple varicosities, the results of portal hypertension.

A normal splenic vein does not exclude portal hypertension.

Enlarged splenic vein

If the splenic vein appears large and remains more than 10 mm in diameter on normal respiration,portal hypertension should be suspected. When the portal vein is more than 13 mm in diameter and does not vary with respiration, there is a strong correlation with portal hypertension.

Intrasplenic mass, with or without splenomegaly



Splenic masses may be single or multiple and well defined or irregular in outline. Lymphoma is the commonest cause of an intrasplenic mass, and such masses are usually hypochogenic. Malignant tumours, either primary or metastatic, are rare and may be either hypo- or hyperechogenic.

Intrasplenic mass, with or without splenomegaly



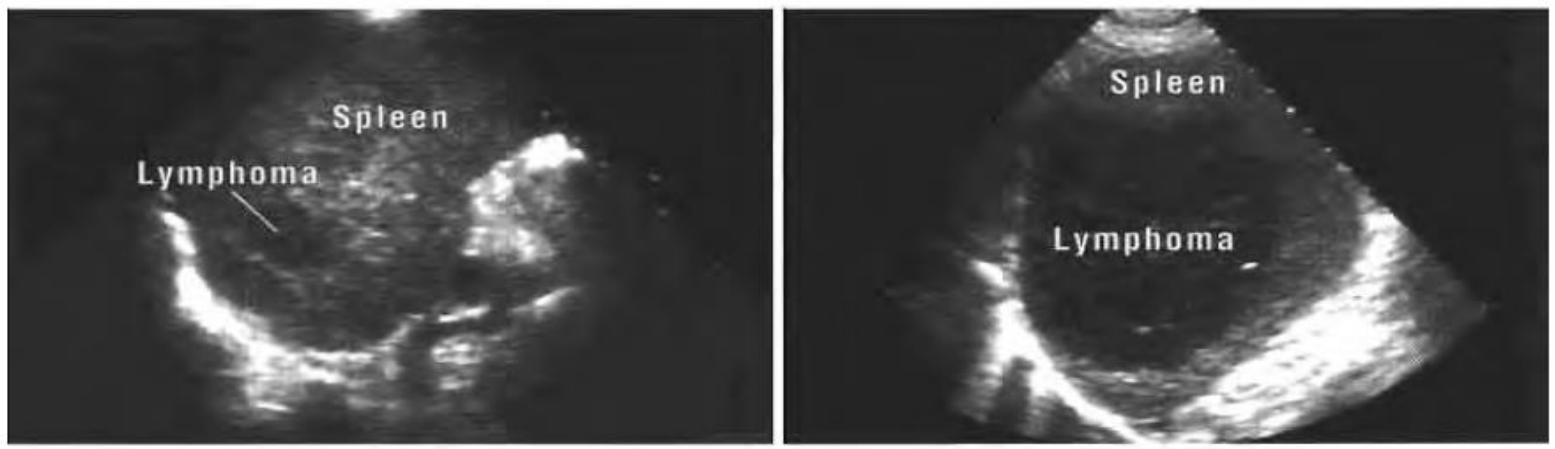

Fig. 82a. Two patients with lymphoma of the spleen: a small mass in the spleen on the left, a much larger mass in the spleen on the right. Both masses are hypoechogenic.

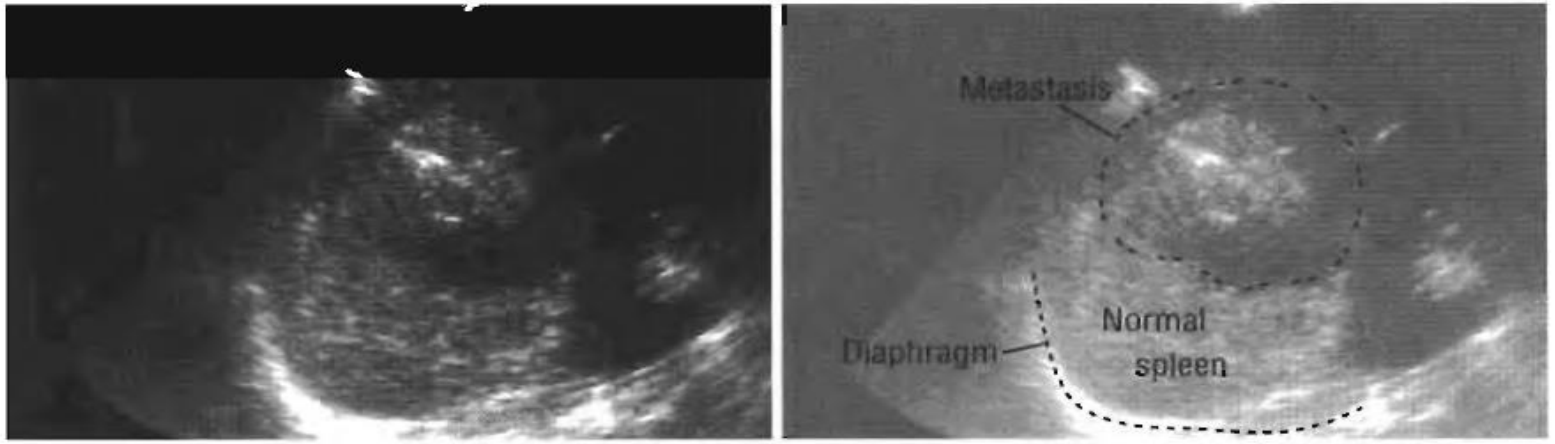

Fig. 82b. Metastasis in the spleen from carcinoma of the ovary.

Intrasplenic mass, with or without splenomegaly



Splenic abscess: an irregular, hypoechogenic or complex cystic intrasplenic mass.

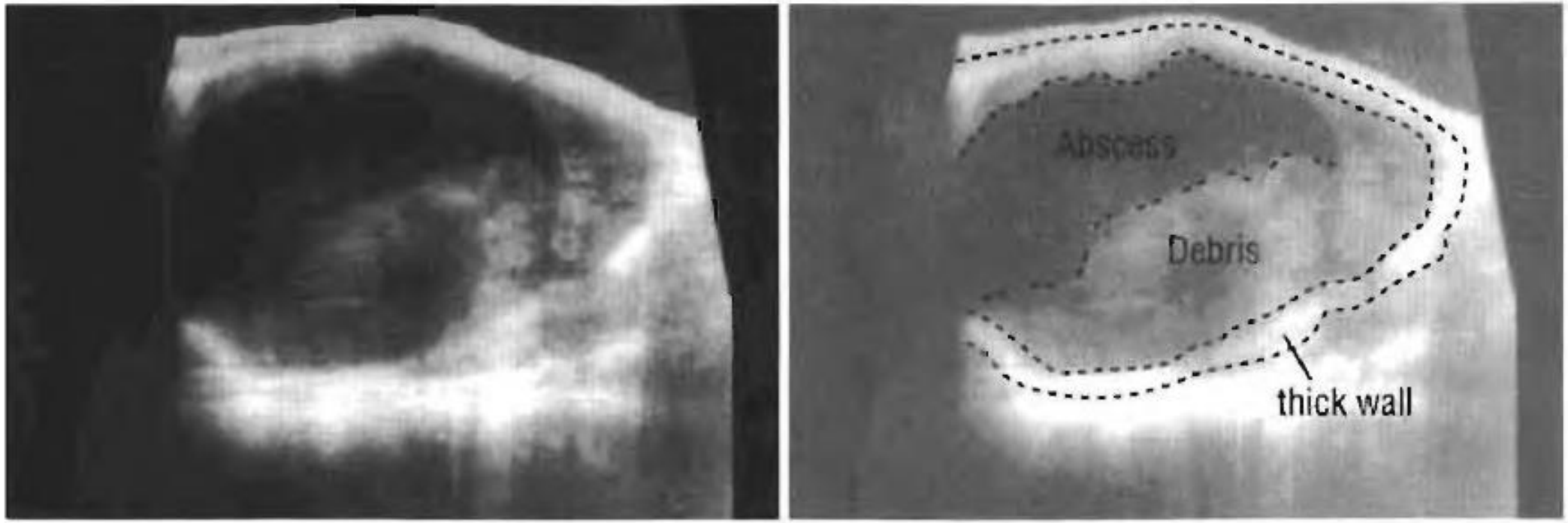

Fig. 82d. A large splenic abscess, containing debris and almost filling the spleen.

Pyrexia (usually of unknown origin)



If possible, check the total and the differential white cell count. Start with longitudinal scans.

A perisplenic, subdiaphragmatic, echo-free or complex mass, superior to the spleen but limited by the left diaphragm, isprobably asubphrenic abscess.

Pyrexia (usually of unknown origin)



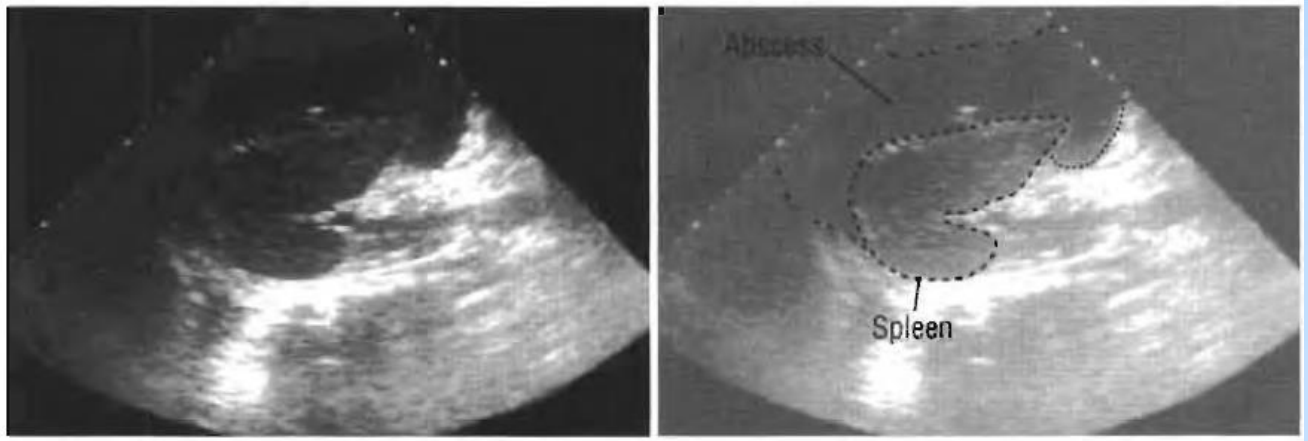

Fig. 83a. Longitudinal scan: a collection of fluid around the spleen; this was a perisplenic abscess, but the type of fluid can seldom be identified with an ultrasound scan.

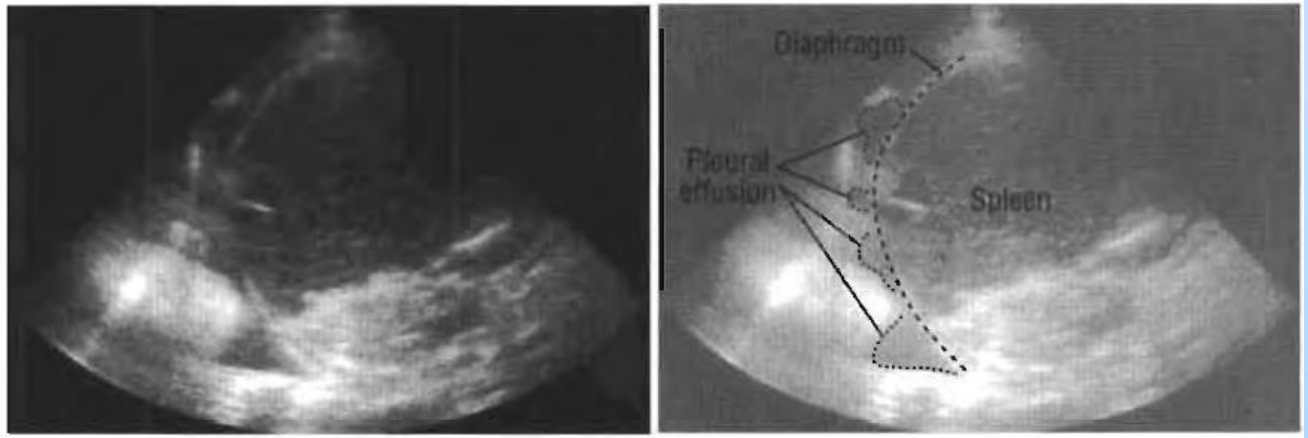

Fig. 83b. A left pleural effusion seen through the spleen.

Trauma



- If there is free intraperitoneal or subphrenic fluid and an irregular splenic outline, a splenic tear or injury is likely.
- An echo-free or complex echo area at the periphery of the spleen, associated with general or localized splenomegaly suggests a subcapsular haematoma. Search carefully for free intra- abdominal fluid.
- An intrasplenic echo-free or complex, irregular mass suggests an acute haematoma. An accessory spleen may have the same appearance.
- An echogenic intrasplenic mass is probably an old haematoma.
- which has calcified, giving bright echoes with acoustic shadowing. A haemangioma may have the same appearance. An irregular, echo-free or complex mass may be a traumatic cyst or a damaged hydatid cyst.

Trauma



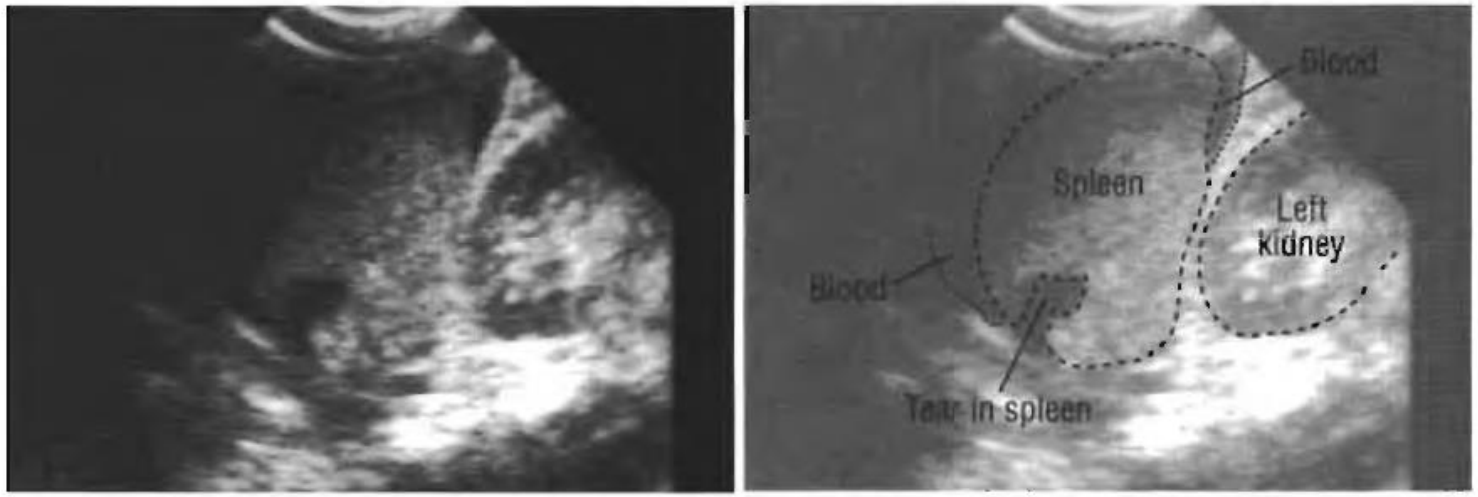

Fig. 84a. A tear in the upper pole of the spleen following injury.

If there is a history of trauma to the abdomen within the previous 10 days, suspect damage to the spleen when there is splenomegaly, persistent anaemia or intra-abdominal fluid.

Thank you