

Normal kidney and ureters, absent kidney, abnormal kidney: large kidney

Hayder Jasim Taher

PhD of Medical Imaging



Outline of my presentation

- ✓ Introduction.
- ✓ Indications.
- ✓ Normal kidney.
- ✓ Adrenal (suprarenal) glands.
- ✓ Absent kidney.
- ✓ Large kidney

Introduction



A kidney ultrasound (renal ultrasound) is an imaging test that allows your healthcare provider to look at your right and left kidney, as well as your bladder. The kidneys are the filtration system of your body. They filter the waste products out of your blood. The waste products then leave your body as urine.

Your healthcare provider may also need a “post void” done with this exam. This requires you to come to the test with a full bladder so that the provider can get a volume of your bladder before and after you empty it.

Indications



- Renal or ureteric pain.
- Suspected renal mass (large kidney).
- Non-functioning kidney on urography.
- Haematuria.
- Recurrent urinary infection.
- Trauma.
- Suspected polycystic disease.
- Pyrexia of unknown origin or postoperative complication.
- Renal failure of unknown origin.
- Schistosomiasis.

Ultrasound *cannot* assess renal function.

Normal kidney



Both kidneys should be about the same size. In adults, a difference of more than 2 cm in length is abnormal.

1. Length: up to 12 cm and not less than 9 cm.
2. Width: normally 4-6 cm but may vary a little with the angle of the scan.
3. Thickness: up to 3.5 cm but may vary a little with the angle of the scan.
4. The central echo complex (the renal sinus) is very echogenic and normally occupies about one-third of the kidney. (The renal sinus includes the pelvis, calyces, vessels and fat.)

In the **newborn**, the kidneys are about 4 cm long and 2 cm wide.

The renal pyramids are poorly defined hypochogenic areas in the medulla of the kidney, surrounded by the more echogenic renal cortex. It is easier to see the pyramids in children and young adults.

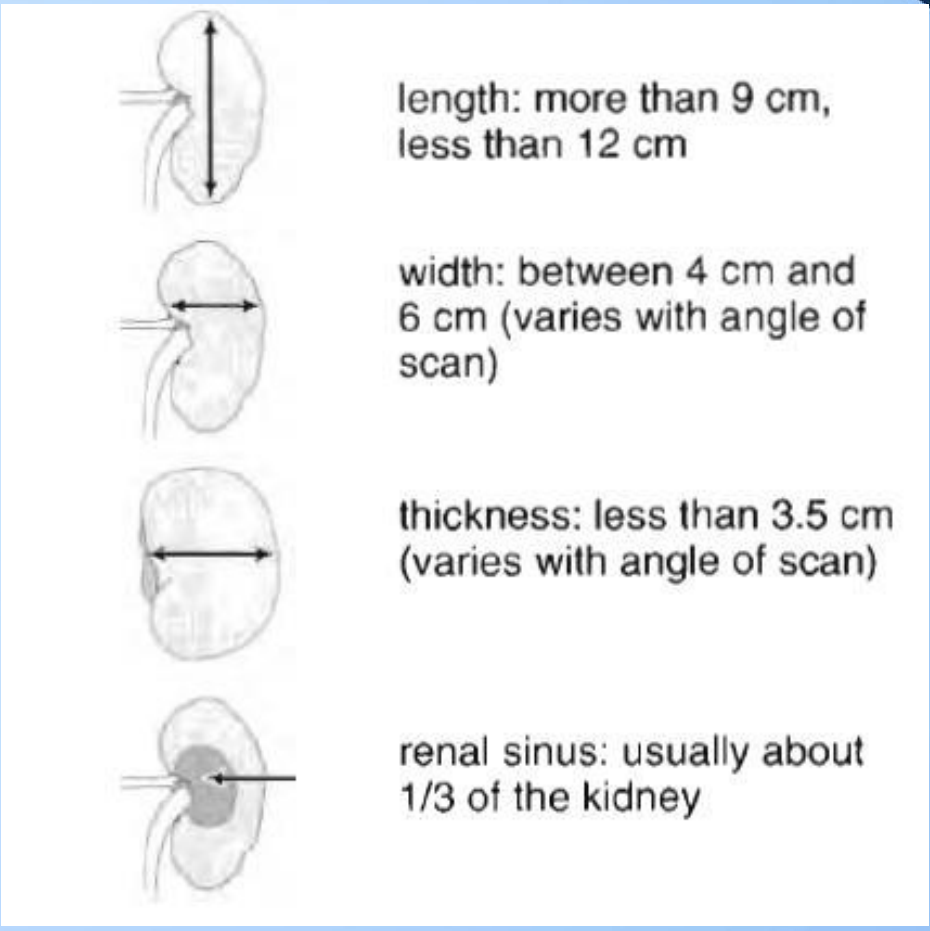

Normal kidney



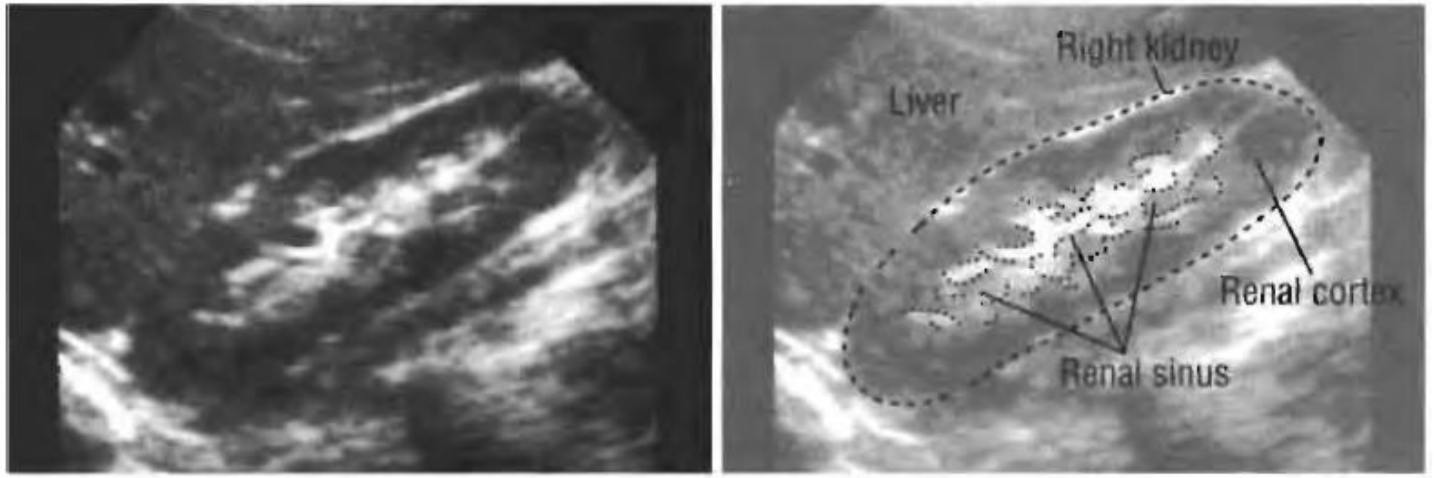

Fig. 97a. Longitudinal scan of a normal right kidney.

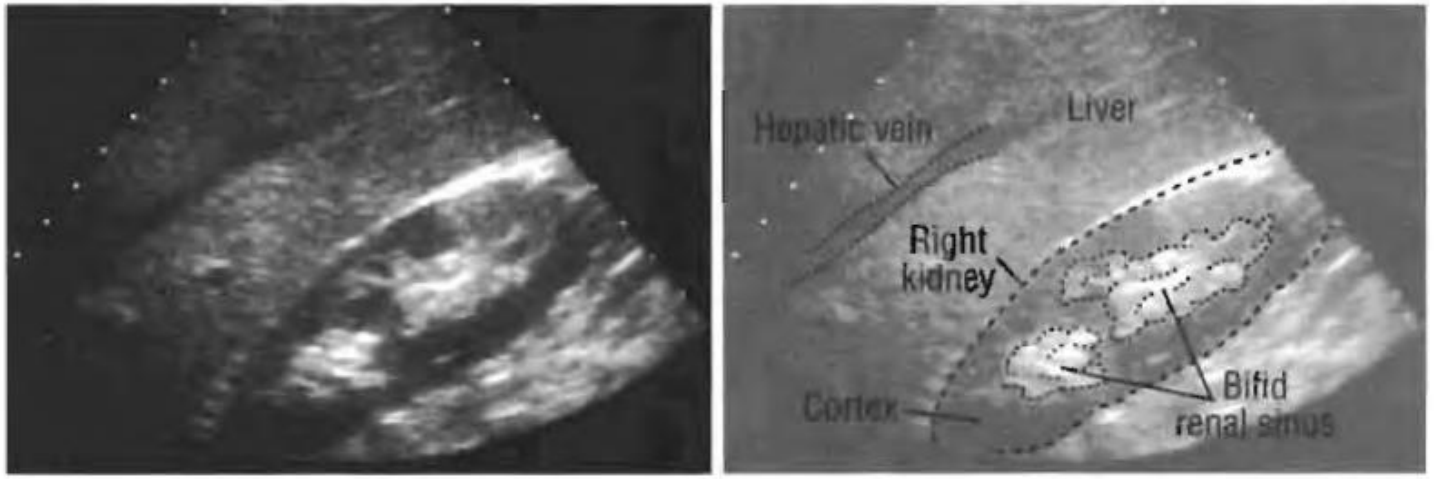

Fig. 97b. Longitudinal scan of a normal right kidney with a bifid renal sinus.

Normal kidney



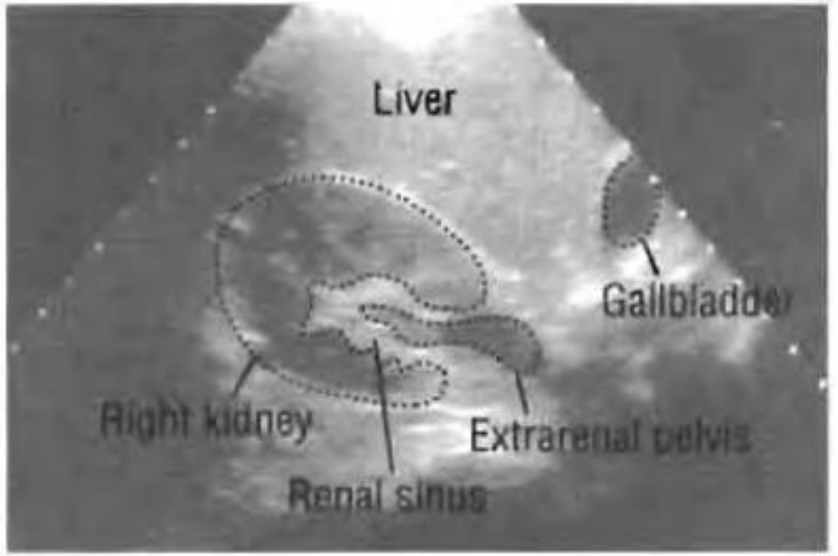

Fig. 97c. Anterior transverse scan through the right renal sinus, showing the pelvis.

When scanning it is important to identify the following:



1. **The renal capsule.** This appears as a bright, smooth, echogenic line around the kidney.
2. **The cortex.** This is less echogenic than the liver but more echogenic than the adjacent renal pyramids (Fig. 98a).
3. **The renal medulla.** This contains the hypoechogenic, renal pyramids which should not be mistaken for renal cysts.
4. **The renal sinus** (the fat, the collecting system and the vessels at the hilus). This is the innermost part of the kidney and has the greatest echogenicity (Fig. 98b).
5. **The ureters**. Normal ureters are not always seen : they should be sought where they leave the kidney at the hilus (Fig. 98c). They may be single or multiple and are often seen in the coronal projection.
6. **The renal arteries and veins.** These are best seen at the hilus. They may be multiple and may enter the kidney at different levels (Fig. 98c).

When scanning it is important to identify the following:



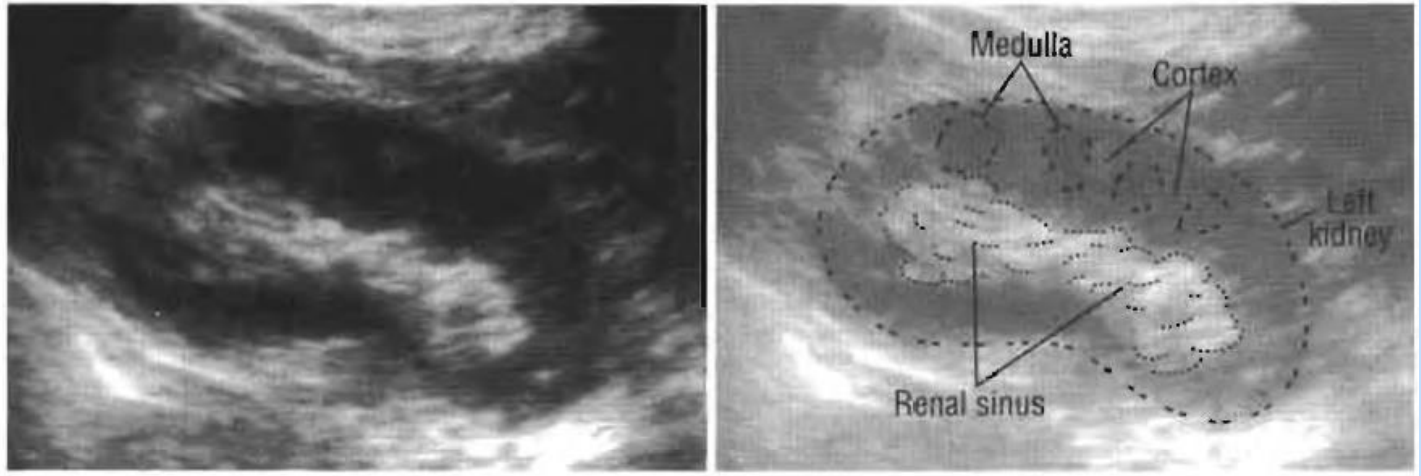

Fig. 98a. Longitudinal scan of a normal left kidney.

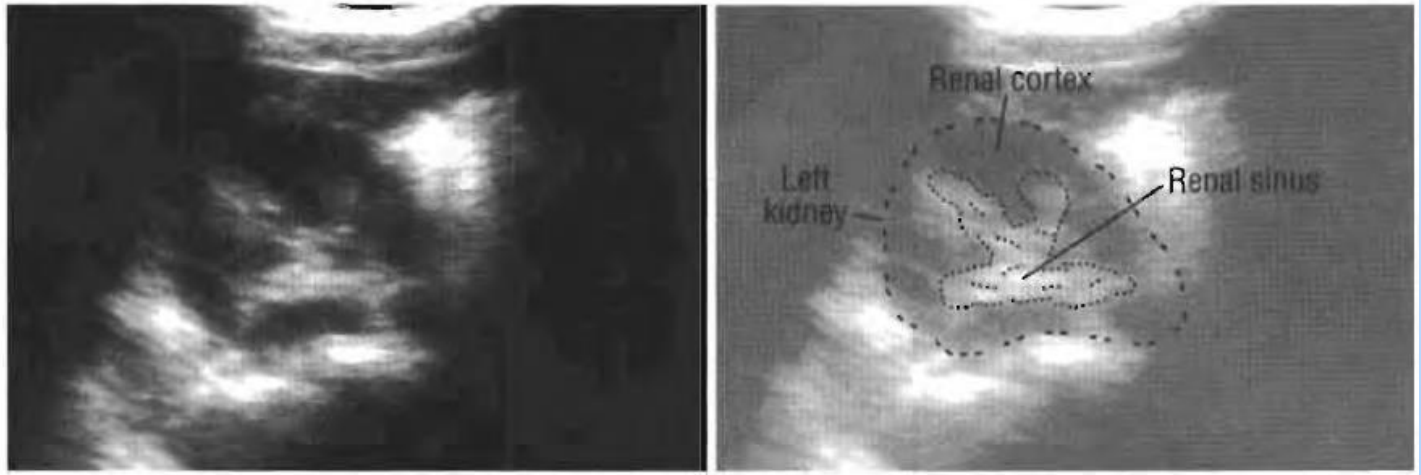

Fig. 98b. Transverse scan of a normal left kidney.

When scanning it is important to identify the following:



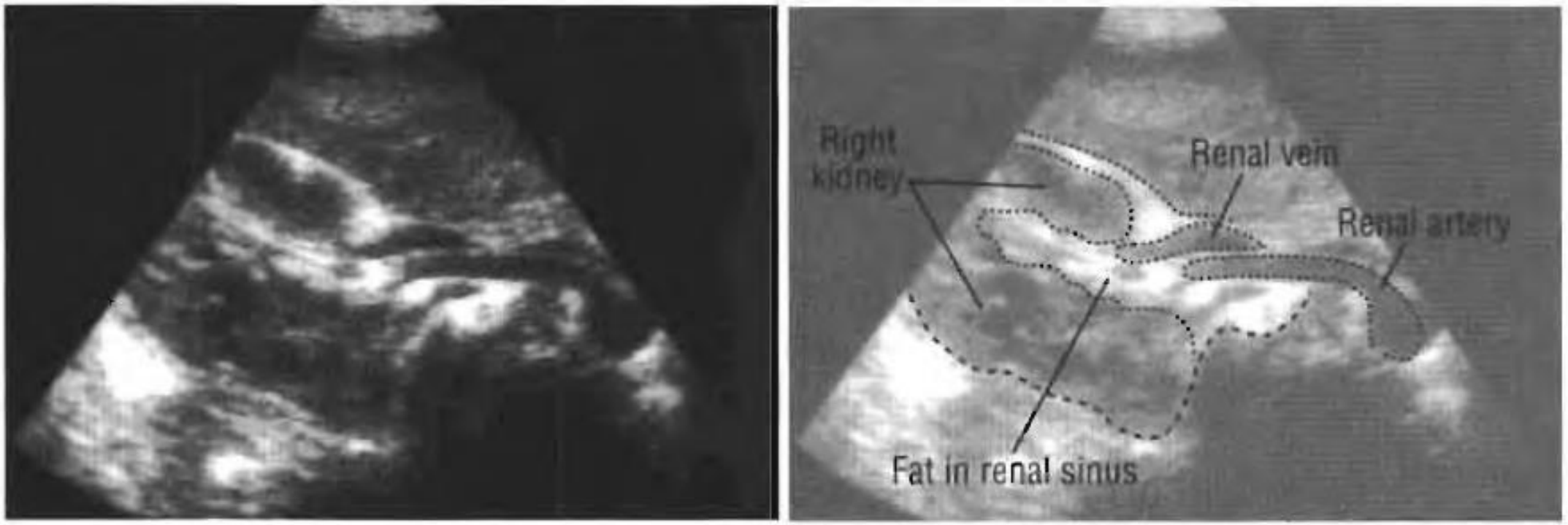

Fig. 98c. Transverse scan of a normal renal sinus (renal pelvis, fat and vessels).

When scanning it is important to identify the following:



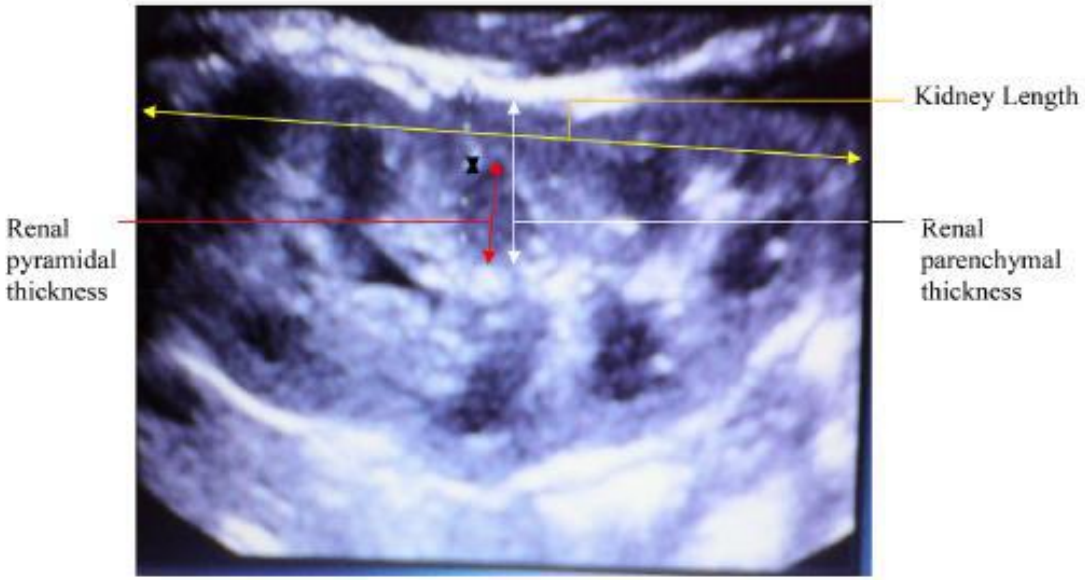

(a)

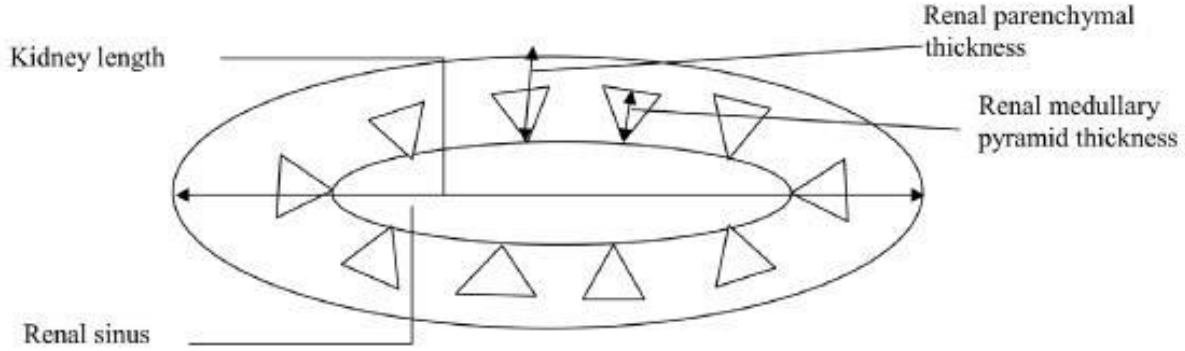

When scanning it is important to identify the following:



- **Renal parenchymal thickness** is measured between the cortex perirenal fat interface (capsule) and the sinus pyramid apex interface at the mid portion on long section of the kidney.
- **Renal medullary pyramid thickness** was measured as the distance between the apex and the base of pyramid at the mid portion of the kidney.
- **Renal length** is measured as the maximum bipolar dimension in longitudinal plane which showed central sinus echoes the best with the renal parenchyma evenly distributed all around the central sinus.
- **Renal width** is measured as the maximum distance between medial and lateral borders of kidney.
- **Renal thickness** or depth is measured as the distance between ventral and dorsal surfaces of the kidney.
- **Renal cortical thickness** is measured as the distance between the renal capsule and the external margin of the hypoechoic medulla (base of the renal pyramid)
- The volume of the entire kidney was calculated using the mathematical formula:

Length (Cm) × width (Cm) × depth (Cm)/2

Adrenal (suprarenal) glands



The adrenal glands are not easily seen with ultrasound.

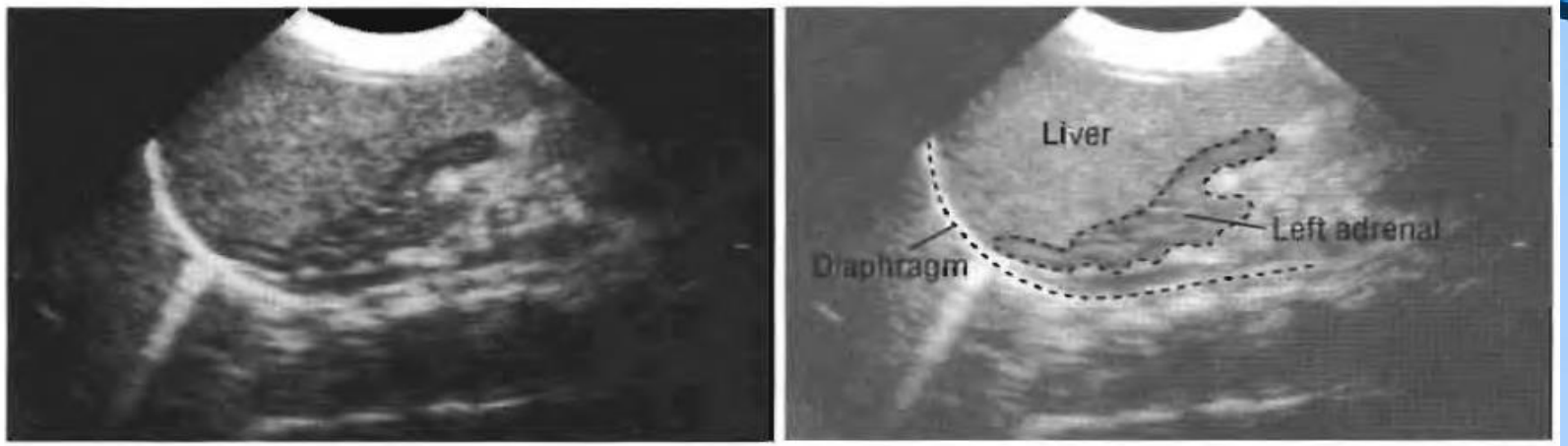

Fig. 99a. Longitudinal scan of the normal left adrenal gland of an infant (the adrenals are large compared with those of an adult).

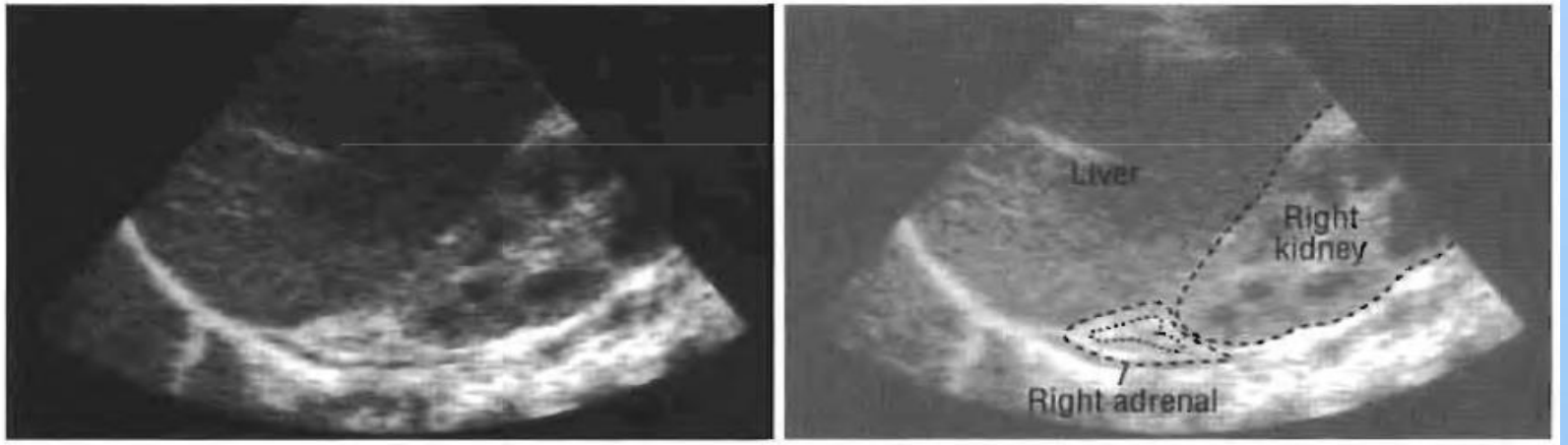

Fig. 99b. Longitudinal scan of a normal right adrenal gland of an adult.

Absent kidney



If either kidney cannot be seen, search again. Adjust the gain to show the liver parenchyma and spleen, and scan in different projections. Assess the size of the visible kidney. Hypertrophy of a kidney occurs (at any age) in a few months when the other kidney has been removed or is not functioning. If there is one large kidney and the other cannot be visualized after a careful search, it is probable that the patient has only one kidney.

If one kidney cannot be demonstrated,consider the following possibilities:

- **The kidney may have been removed.** Check the clinical history and examine the patient for scars.
- **The kidney may be ectopic.** Search the kidney area and the whole abdomen, including the pelvis. If no kidney is found, X-ray the chest. Acontrast urogram may be necessary.
- **If only one large but normal kidney is demonstrated,** and there has not been any surgery, it is likely that there is congenital absence of the other kidney. If the only kidney visualized is not enlarged, a failure to demonstrate the other kidney suggests chronic disease.
- **If there is one large but distorted kidney,** there may be a developmental abnormality.
- Apparent absence of both kidneys may be a failure to demonstrate them with ultrasound because of changed echogenicity resulting from chronic disease of the renal parenchyma.
- **Any kidney less than 2 cm thick and 4 cm long can be very difficult to visualize.** Locate a renal vessel or ureter; this may help to localize the kidney, especially if the ureter is dilated.

Absent kidney

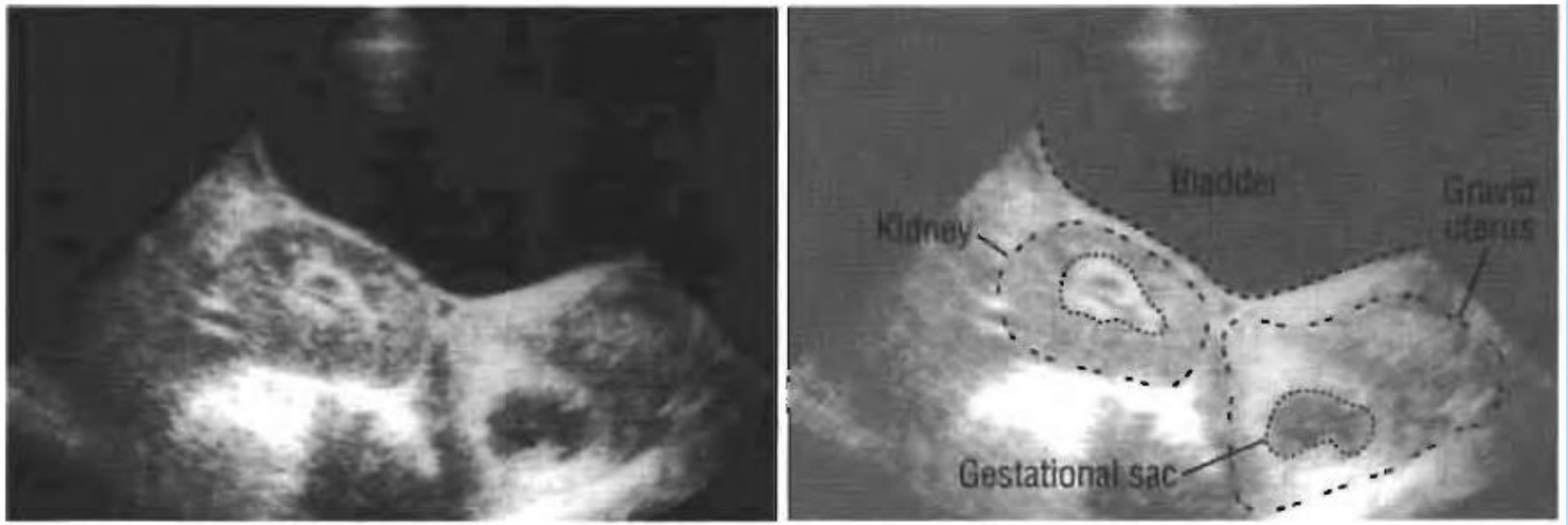

Fig. 100. Longitudinal scan through the bladder showing a low-lying (pelvic) kidney. The patient is 8 weeks pregnant.

A pelvic kidney may be confused sonographically with a tubo-ovarian mass or gastrointestinal tumour. Use a contrast urogram to locate the kidney.

Large kidney



Bilateral enlargement

- When the kidneys are enlarged but normal in shape, with normal, decreased or increased homogeneous echogenicity, the possible causes are:

  - Acute or subacute glomerulonephritis or severe pyelonephritis.
  - Amyloidosis.
  - The nephrotic syndrome.

- When the kidneys have a smooth outline and are uniformly enlarged, with nonhomogeneous hyperechogenicity, the possible causes are:

  - Lymphoma.
  - Metastases.
  - Polycystic kidneys.

Large kidney



Unilateral enlargement

If one kidney appears to be enlarged but has normal echogenicity, and the other kidney is small or absent, the enlargement may be due to compensatory hypertrophy. When no other kidney is seen, exclude crossed ectopia and other developmental abnormality.

The kidney may be slightly enlarged because of persistent segmentation (duplication) with two or even three ureters. Search for the renal hilus: there are likely to be two or more vessels and ureters.

Large kidney



One kidney is enlarged or more lobulated than normal

The commonest cause of an enlarged kidney is hydronephrosis, which will appear on ultrasound images as multiple, well circumscribed cystic areas (the calyces) with a dilated central cystic area (the renal pelvis, normally less than 1 c m in width).

Always compare the two kidneys when assessing the size of the renal pelvis. When much of the pelvis is outside the renal parenchyma, it may be a normal variant. When the renal pelvis is enlarged, normal echoes can be lost because of the fluid content A large renal pelvis may be due either to overhydration with increased urinary output or to an overfilled urinary bladder. The renal calyces will be normal. Ask the patient to empty the bladder and rescan.

Large kidney



One kidney is enlarged or more lobulated than normal

Pelvic dilatation can occur normally in pregnancy and does not necessarily indicate infection. Check the urine for infection, and check the uterus for pregnancy.

A large renal pelvis is an indication to scan the ureters and the bladder and particularly the other kidney to locate the obstruction. If no cause is identified, a contrast urogram will be necessary. The normal con- cave calyces may become inverted and rounded as the degree of obstruction increases. Eventually the renal cortex becomes thinned.

Large kidney



One kidney is enlarged or more lobulated than normal

To assess the degree of hydronephrosis, measure the size of the renal pelvis when the bladder is empty. If the pelvis is **wider than 1 cm**, but there is no calyceal dilatation, the hydronephrosis **is mild**. When there is calyceal dilatation, the hydronephrosis is **moderate**. If there is loss of the renal cortex. it is advanced.

Hydronephrosis can be caused by congenital obstruction of the uretero- pelvic junction, by ureteric stenosis (e.g. as in schistosomiasis) or a calculus, or from external pressure on the ureters by a retroperitoneal or abdominal mass.

Degrees of hydronephrosis



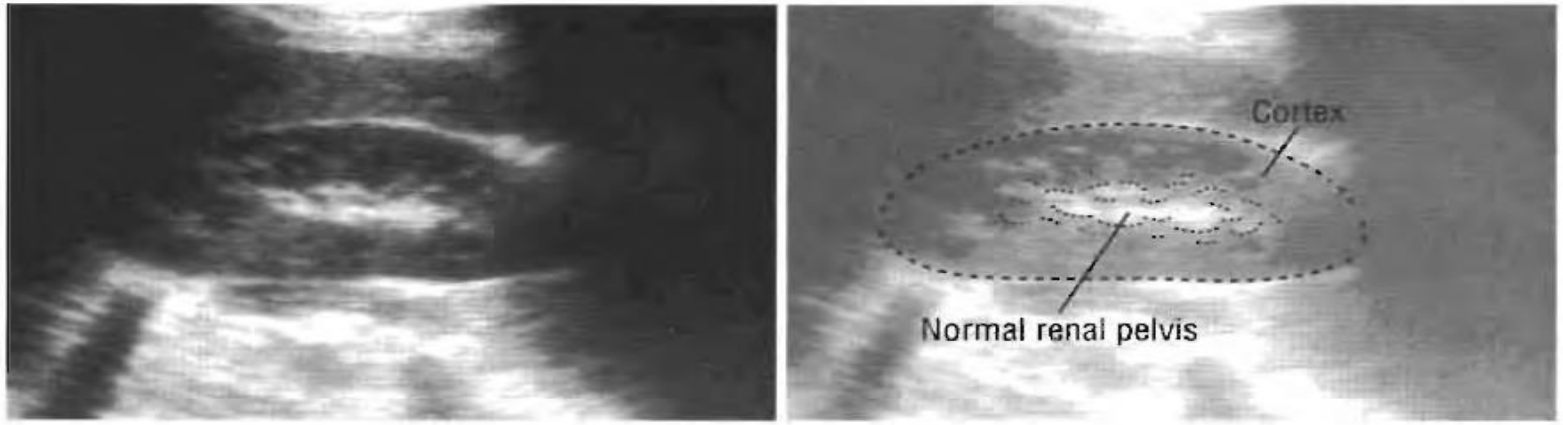

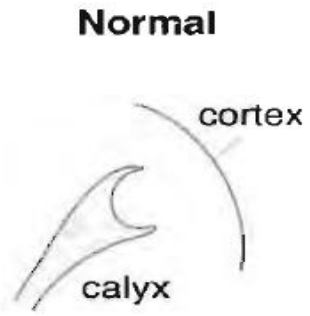

Fig. 104a. Longitudinal scan: the renal pelvis of a normal kidney is less than 1 cm in width.

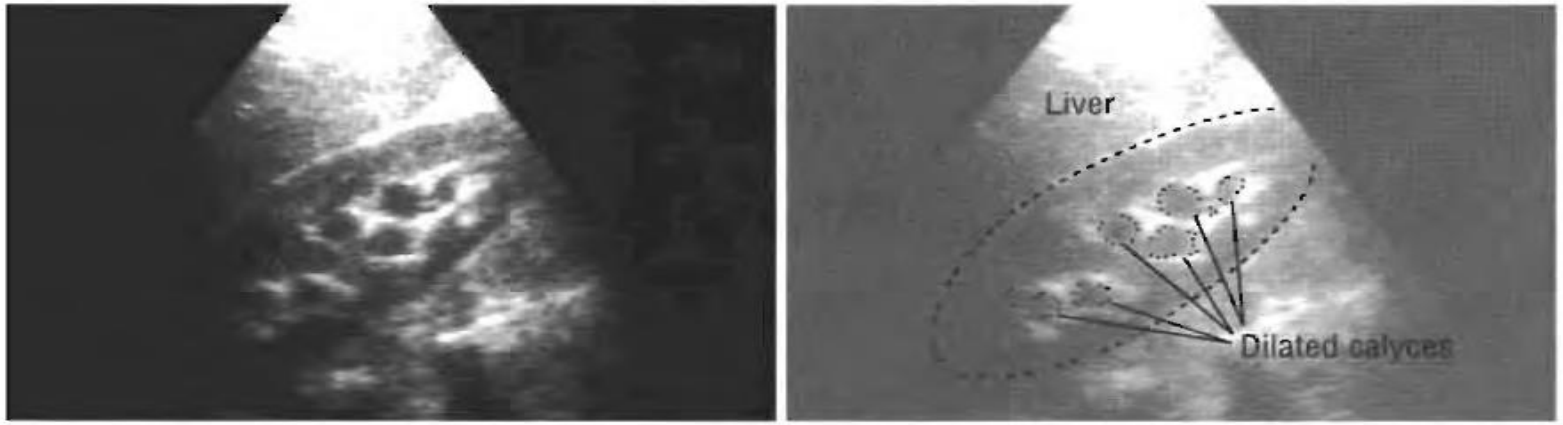

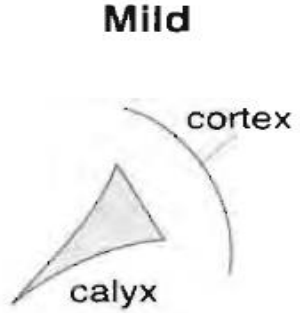

Fig. 104b. Longitudinal scan: a renal pelvis more than 1 cm in width, indicating mild hydronephrosis. Small parapelvic cysts have a similar appearance.

Degrees of hydronephrosis



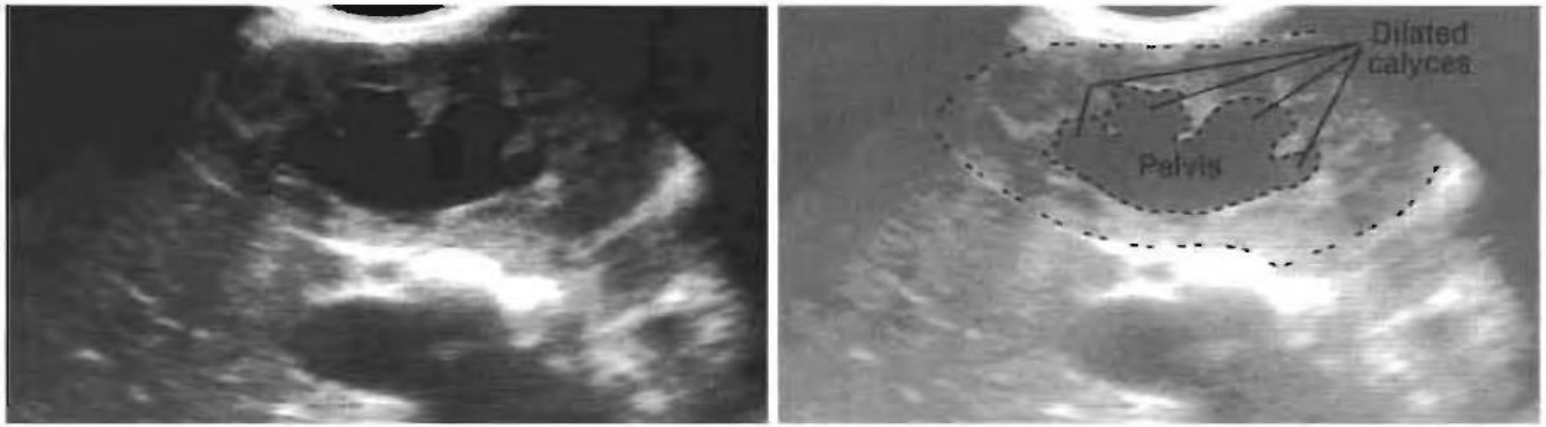

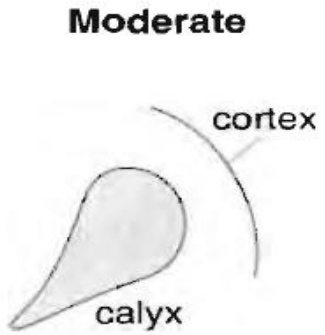

Fig. 104c. Longitudinal scan: calyceal dilatation, indicating moderate hydronephrosis.

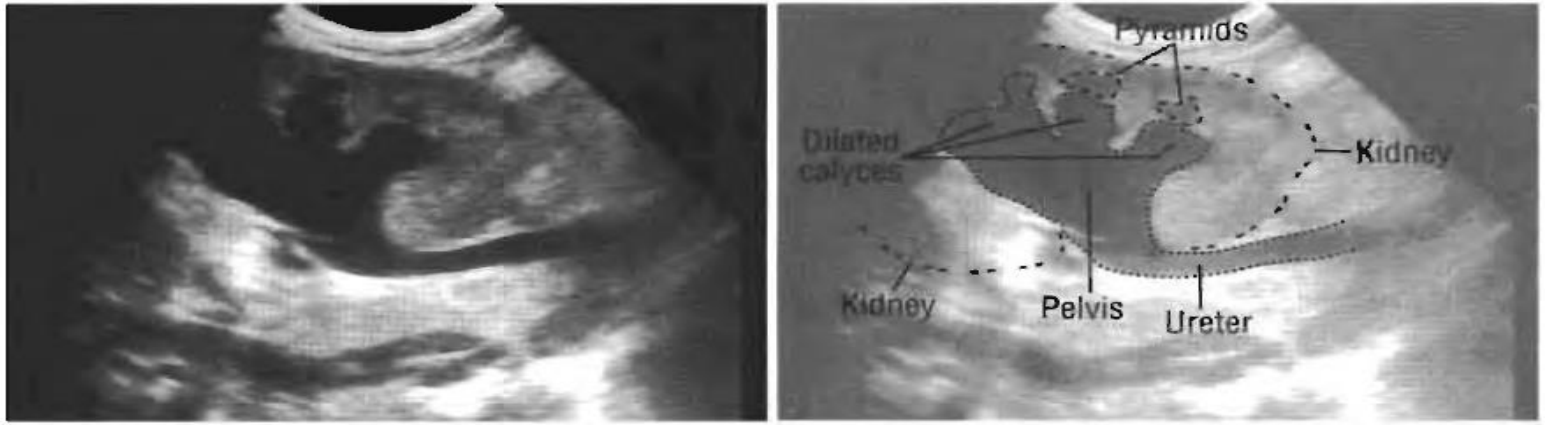

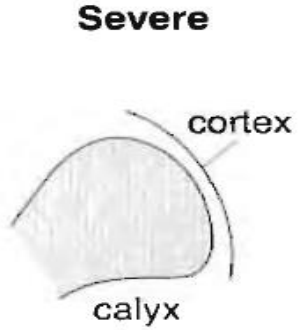

Fig. 104d. Longitudinal scan: dilated calyces and a renal cortex decreased in width are indicative of advanced hydronephrosis.


Thank you