Cholelithiasis

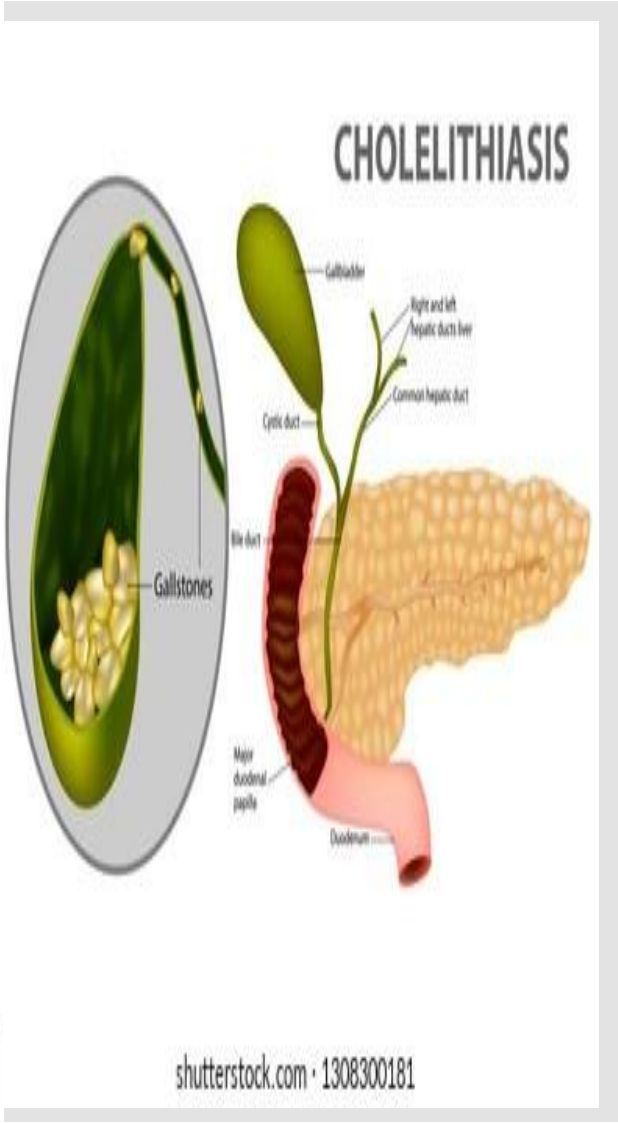

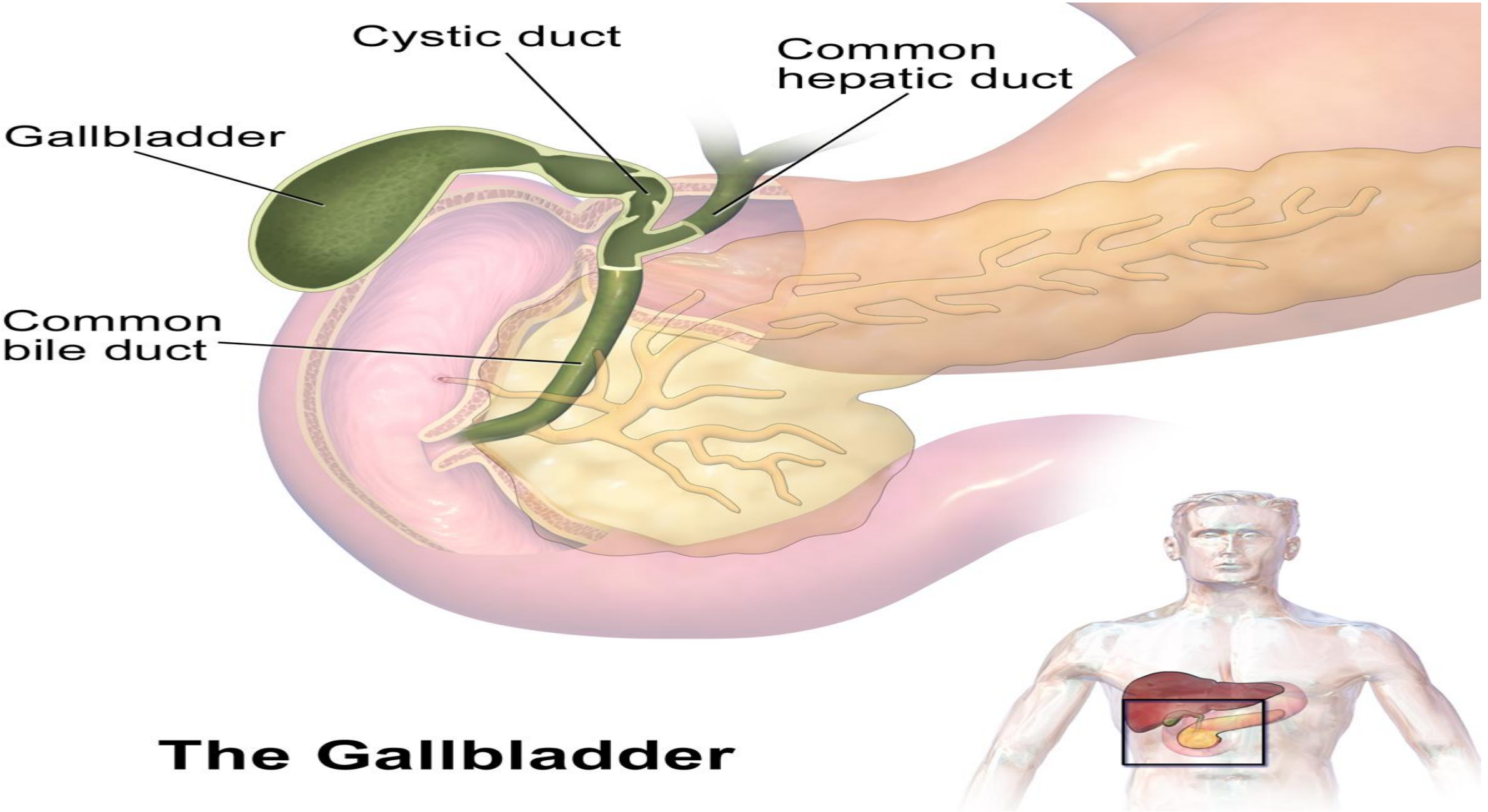

The Gallbladder

ANATOMIC AND PHYSIOLOGIC OVERVIEW

- **The Gallbladder**
- The gallbladder, a pear-shaped, hollow, saclike organ, 7.5 to 10 cm (3 to 4 in) long, lies in a shallow depression on the inferior surface of the liver, which it is attached by loose connective tissue.
- The capacity of the gallbladder is 30 to 50 mL of bile.
- Its wall is composed largely of smooth muscle.
- The gallbladder is connected to the common bile duct by the cystic duct

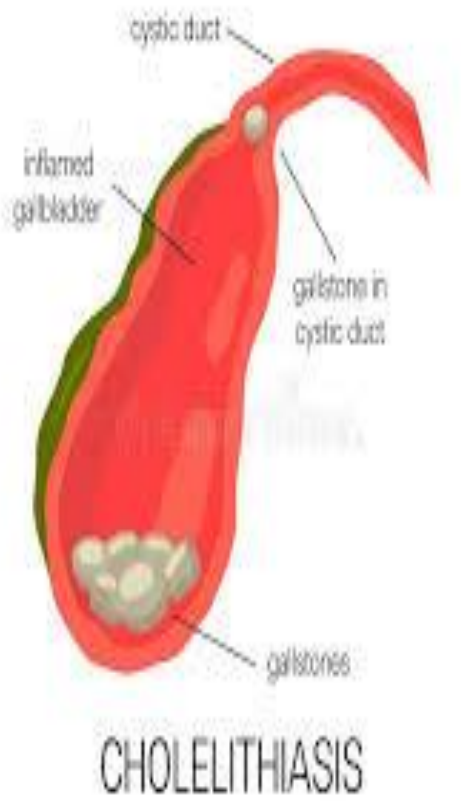

Definition

- Calculi, or gallstones, usually form in the gallbladder from the solid constituents of bile .
- they vary greatly in size, shape, and composition .
- They are uncommon in children and young adults but become more prevalent with increasing age, affecting 30% to 40% of people by the age of 80 years.

- **Gallstone Types**
- **The two main kinds of gallstones are:**

1. **Cholesterol stones.** These are usually yellow-green. They're the most common, making up 80% of gallstones.
2. **Pigment stones.** These are smaller and darker. They're made of bilirubin..

CHOLESTEROL CALCULI



PIGMENT CALCULI





- ***Two to three times more women than men develop cholesterol stones and gallbladder disease;***

1. **affected women are usually older than 40 years of age**
2. **Multiparous. (many or more than one at a birth).**
3. **obese.**
4. **use oral contraceptives, estrogens, or clofibrate(these medications are known to increase biliary cholesterol saturation).**

SignS and symptom s

- The symptoms may be acute or chronic .

1. fullness.
2. Abdominal distention.
3. vague pain in the right upper quadrant of the abdomen, may occur.
4. The distress may follow a meal rich in fried or fatty foods.

Assessment and Diagnostic Findings

1. Abdominal X-Ray
2. Ultrasonography
3. Radionuclide Imaging
4. Cholecystography
5. Endoscopic Retrograde Cholangiopancreatography

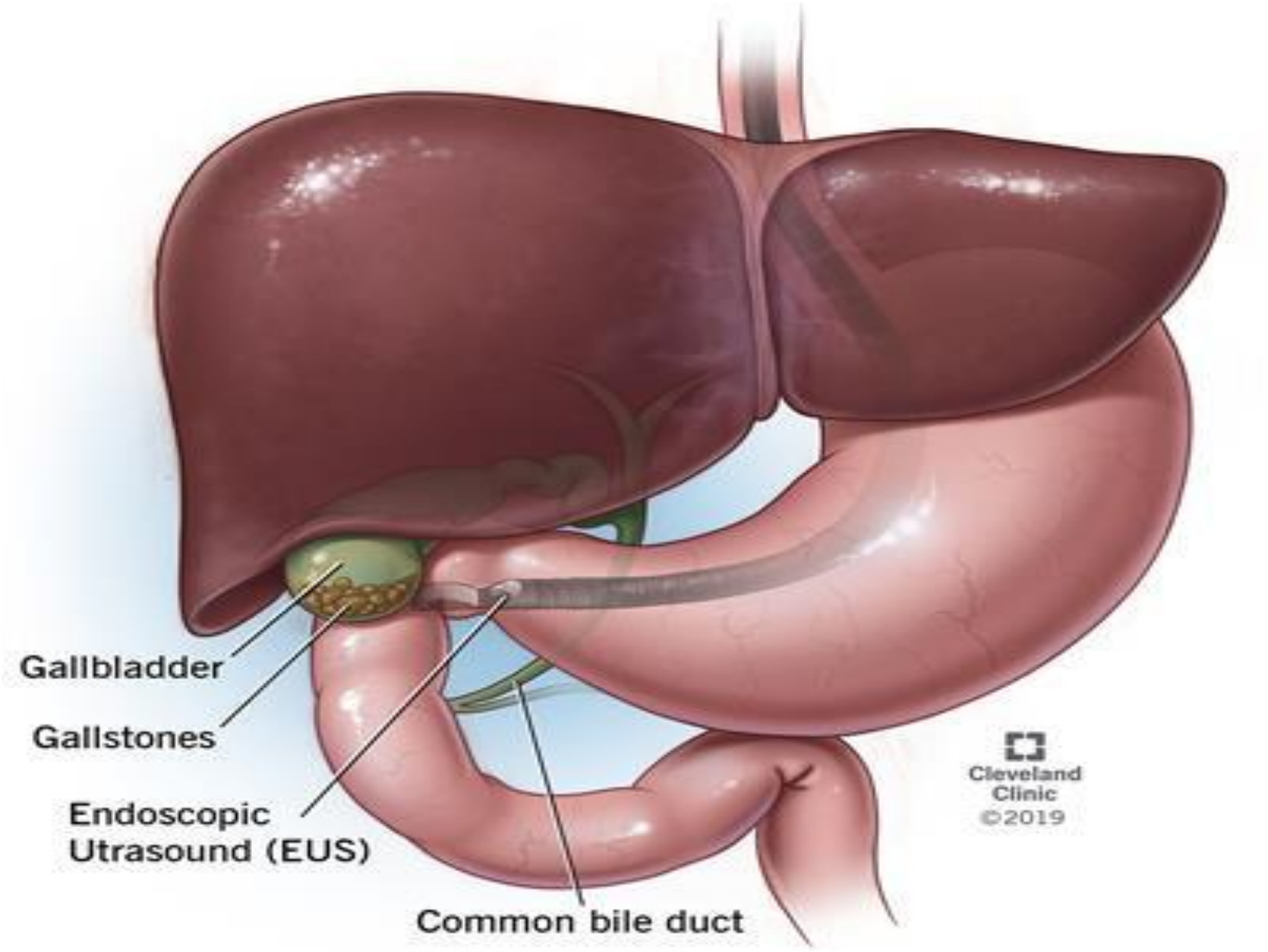
Gallbladder
Gallstones
Endoscopic
Utrasound (EUS)
Common bile duct
Cleveland
Clinic
©2019

COMPLICATIONS OF GALLSTONES

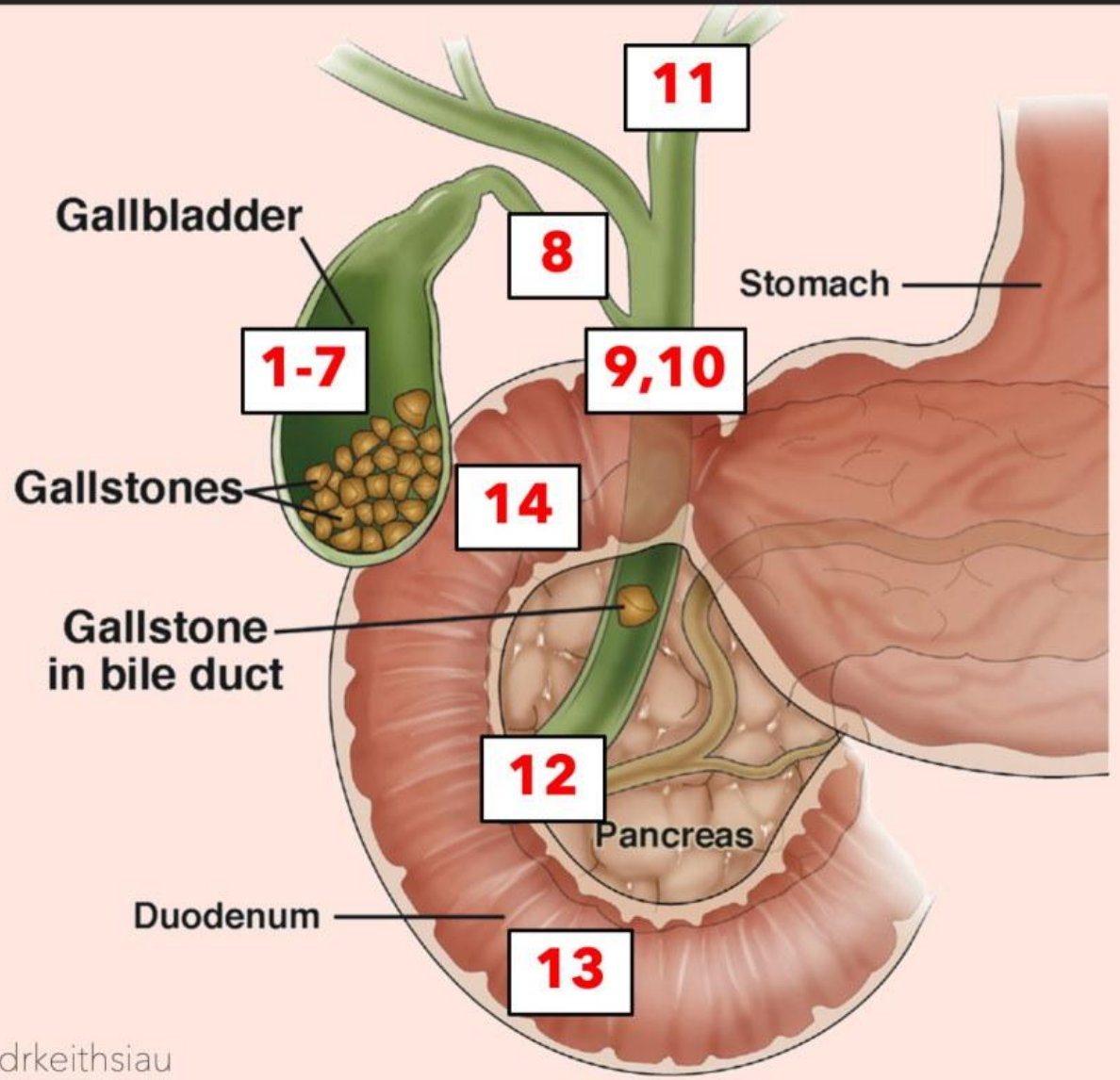

1. Biliary colic
2. Cholecystitis
3. Mucocele
4. Empyema
5. Fistula
6. Perforation
7. Gallbladder carcinoma
8. Mirizzi's syndrome
9. Choledocholithiasis
10. Cholangitis
11. Intrahepatic stones
12. Pancreatitis
13. Gallstone ileus
14. Bouveret's syndrome

@drkeithsiau

Treatment options for gallstones include:

- **Surgery to remove the gallbladder (cholecystectomy).**

Laparoscopic cholecystectomy

is a common surgery that requires general anesthesia. The surgeon will usually make three or four incisions in your abdomen. They'll then insert a small, lighted device into one of the incisions, check for stones, and carefully remove your gallbladder

Open cholecystectomy. This surgery is typically performed when the gallbladder is inflamed, infected, or scarred.



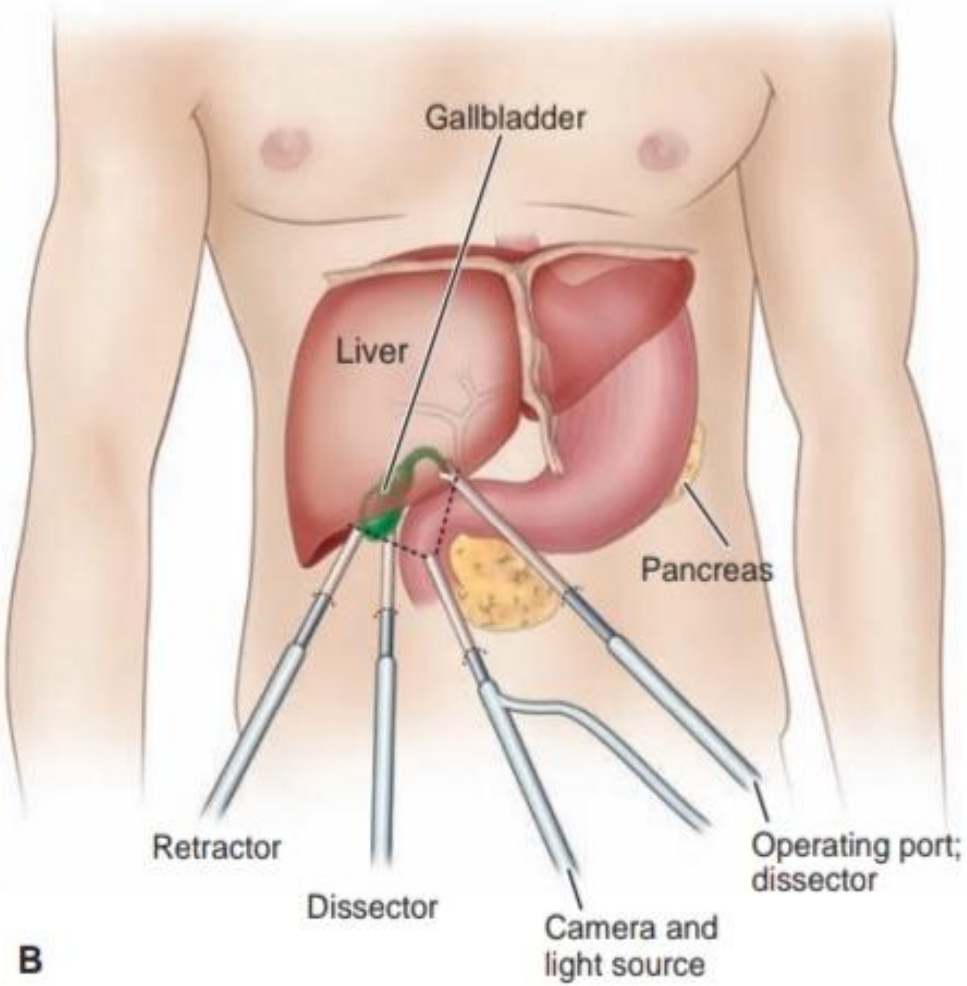

A B

Figure 40-5 **A,** In laparoscopic cholecystectomy, the surgeon makes four small incisions (less than one half inch each) in the abdomen **(B)** and inserts a laparoscope with a miniature camera through the umbilical incision. The camera apparatus displays the gallbladder and adjacent tissues on a screen, allowing the surgeon to visualize the sections of the organ for removal.

nursing diagnosis

1. Risk for Deficient Fluid Volume
2. Acute Pain
3. Risk for Imbalanced Nutrition: Less Than Body Requirements
4. Deficient Knowledge

Interventions

1. Maintain accurate record of I&O,
2. Monitor for signs and symptoms of increased or continued nausea or vomiting, abdominal cramps, weakness, twitching .
3. Eliminate noxious sights or smells from environment .
4. Perform frequent oral hygiene with alcohol-free mouthwash; apply lubricants.
5. Keep patient NPO as necessary.
6. Bed rest.
7. Check up v/s.


Thank for listening