PHYSICAL ASSESSMENT
INTEGUMENTARY SYSTEM

Dr. Sahar Adham

Equipment

- ✓Ruler
- ✓Lighting
- ✓Penlight
- ✓Gloves
- ✓Magnifying glass
- ✓Woods lamp

Nails Assessment

PE Technique :

Inspection

Color

Normal : pink

Abnormal: Pale, Bluish

Hygiene: Clean, Wally trimmed

Abnormal: Dirty ,

Consideration : client work , educational instruction for cleaning

Shape: Convex ,the angle between the nail bad and the nail is 160 degree

Abnormal:

spoon shape : anemia

clubbing :early clubbing 180 degree , more than 180 degree consider as late clubbing

Beau’s line : acute disease

Later Clubbing



Spoon Shape (koilonychia)





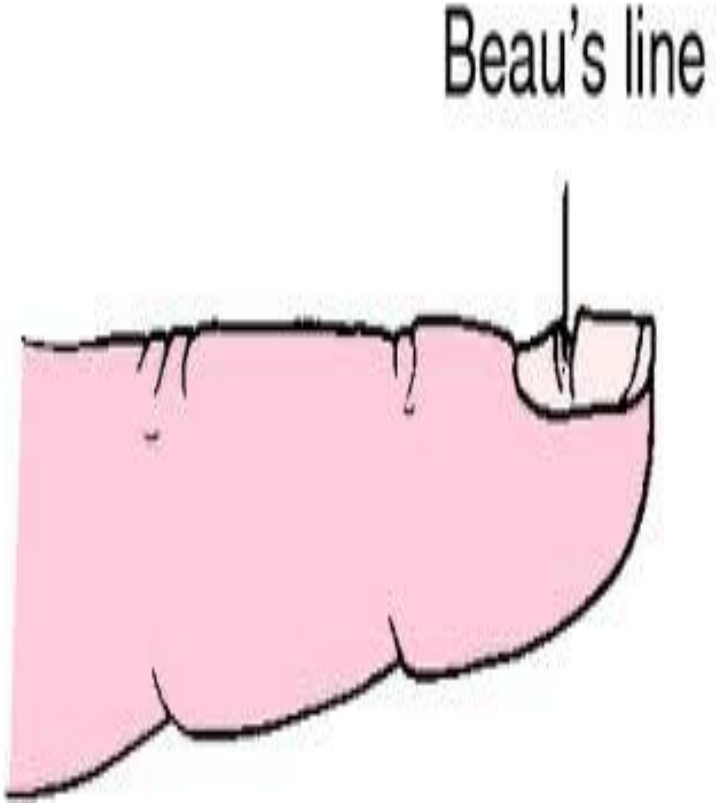
Beau's line



PE Palpation

Texture

Normal: smooth & thin

Abnormal: Hard & thick

Vascularity

Assessed by Blanch test (refill) normal color returned within 2 second

Skin Assessment

PE Technique

Inspection

Color : Evenly white to light brown

Abnormal: pale, cyanosis , yellowish & erythema (local or general)

Marks and pigmentation :

Moles ,naive & birth marks normal

Abnormal : changing of Moles ABCDE

Pigmentation :

petechiae pin point red flat impalpable discoloration of skin

Purpura : hemorrhage into skin caused by decrease platelet ,liver disfunction

Ecchymosis : discoloration of skin called black and blue mark due to trauma

Lesion:

Macule : red ,less than 1cm flat as freckle

Papule :Solid elevated less than 0.5 cm such as warts & nevi

Patch : red flat more than 1cm 1stage pressure ulcer

Nodules : Solid elevated deep than papule within 0.5-2 cm such as cyst

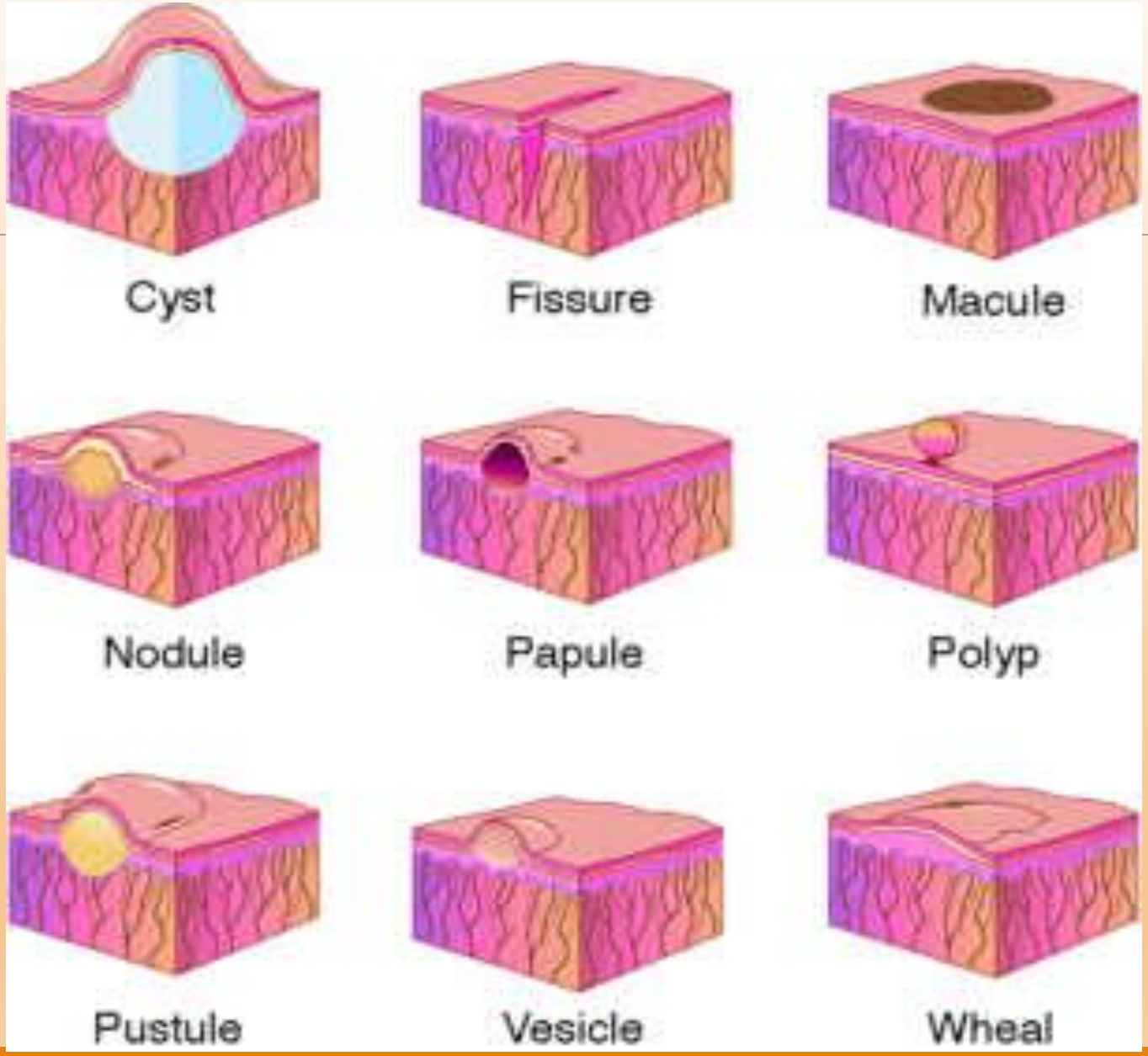
Cyst
Fissure
Macule
Nodule
Papule
Polyp
Pustule
Vesicle
Wheal

Vesicle : Accumulation of fluid in skin elevated , less than 0.5 cm full of serous such as blister

Bullae : as vesicle but great than 0.5 cm

Pustule : such as vesicle less than 0.5 cm put full of pus such as acne

Wheal : local edema irregular elevation may be red or pale as insect bite

Palpation

Temperature

Texture : smooth evenly firm

Abnormal : roughness (occupation , weather & chemical products

Moisture : dry some perspiration in palm , axially , folded skin area

Abnormal : diaphoresis or clammy

Mobility and Elasticity (turgor)

Mobility

Elasticity

Hair Assessment :

Cleanliness : clean ,shiny , free of dandruff and lice's

Hair distribution : evenly distributed on the scalp

Color : normal color or chemical color

Texture : smooth or coarse , oily or dry

Scalp : free of lesion and mass

Bald

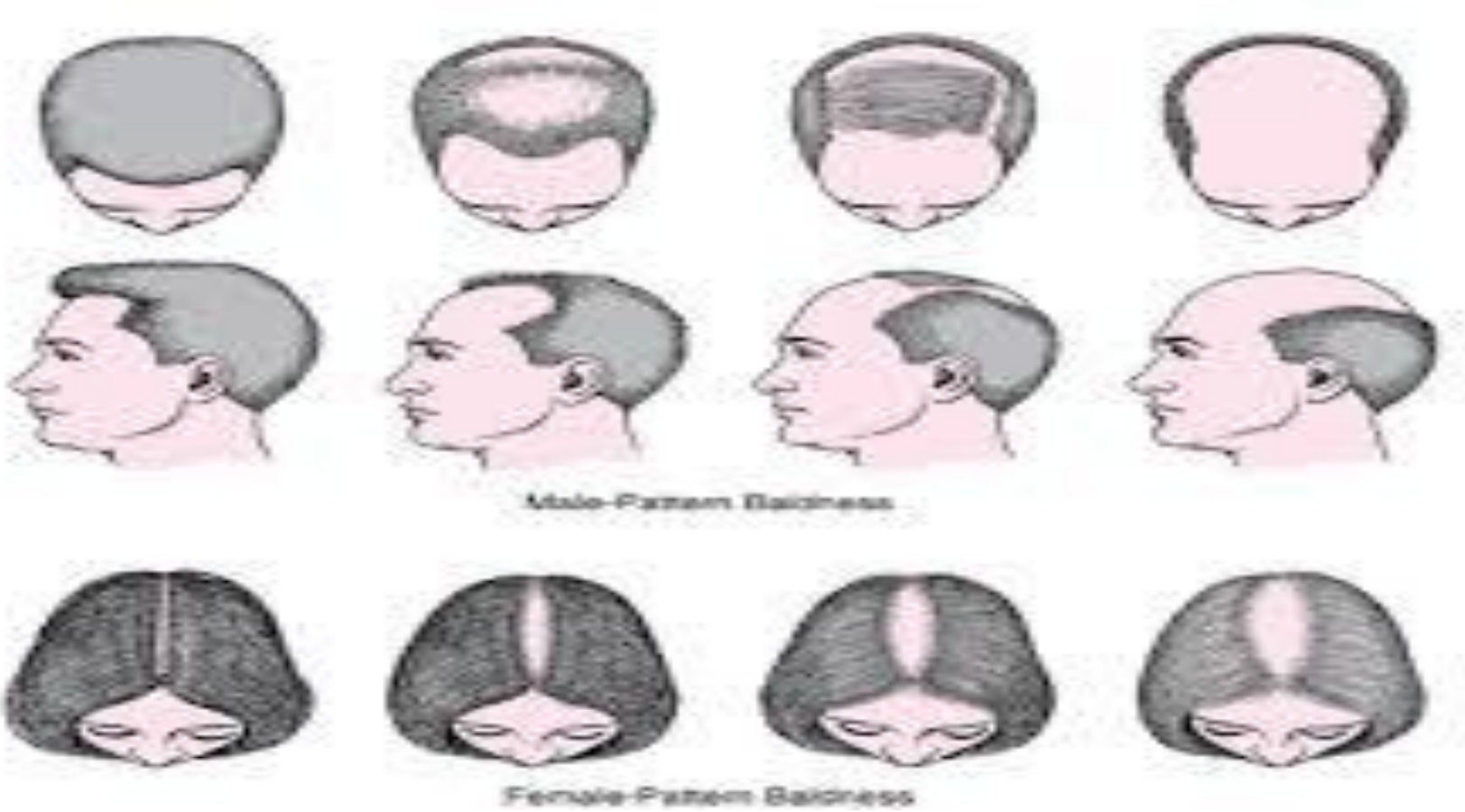

Alopecia



