Physical Examination
Ear, Nose, Mouth and Throat

Dr. Sahar Adham

COMPETENCIES

* Discuss the system-specific history for the ears, nose, mouth, and throat.
* Describe normal findings in the physical assessment of the ears, nose, mouth, and throat.
* Describe common abnormalities found in the physical assessment of the ears, nose, mouth, and throat.
* Explain the pathophysiology of common abnormalities of the ears, nose, mouth, and throat.

General Approach to Ears, Nose, Mouth, and Throat

1. Greet the patient and explain the assessment techniques that using.
2. Use a quiet room that will be free from interruptions.
3. Ensured that the light in the room provides sufficient brightness adequate observation of the patient.
4. Place the patient in an upright sitting position or for patients who cannot tolerated he sitting position assess head so that it can be rotated from side to side
5. Visualize the underlying structures during the assessment allow adequate description of findings.
6. Always compare right and left ears, as well as right and left nose, sinuses, mouth, and throat..

Equipment

- Otoscope with earpieces of different
- sizes and pneumatic attachment
- Nasal speculum
- Penlight
- Tuning fork (512)Hz
- Tongue blade
- Watch
- Gauze square
- Clean gloves
- Transilluminator
- Cotton-tipped applicator

- Sings & Symptoms:
- History of hearing problem
- Family history
- Medication history
- Ringing in ears hearing difficulty ,onset ,factors contributing to it, and how it interferes with living activities of daily , corrective hearing device
- Pain ,discharge , and lesion

AURICLES

Inspect the auricle for colors, symmetry of size and position 'To inspect position . Note the level at which the superior aspect of the auricle attach to the head in relation to the eye

Normal :

- Color same as facial skin
- Symmetrical
- Auricle aligned with outer canthus of eye, about 1 0" from vertical.

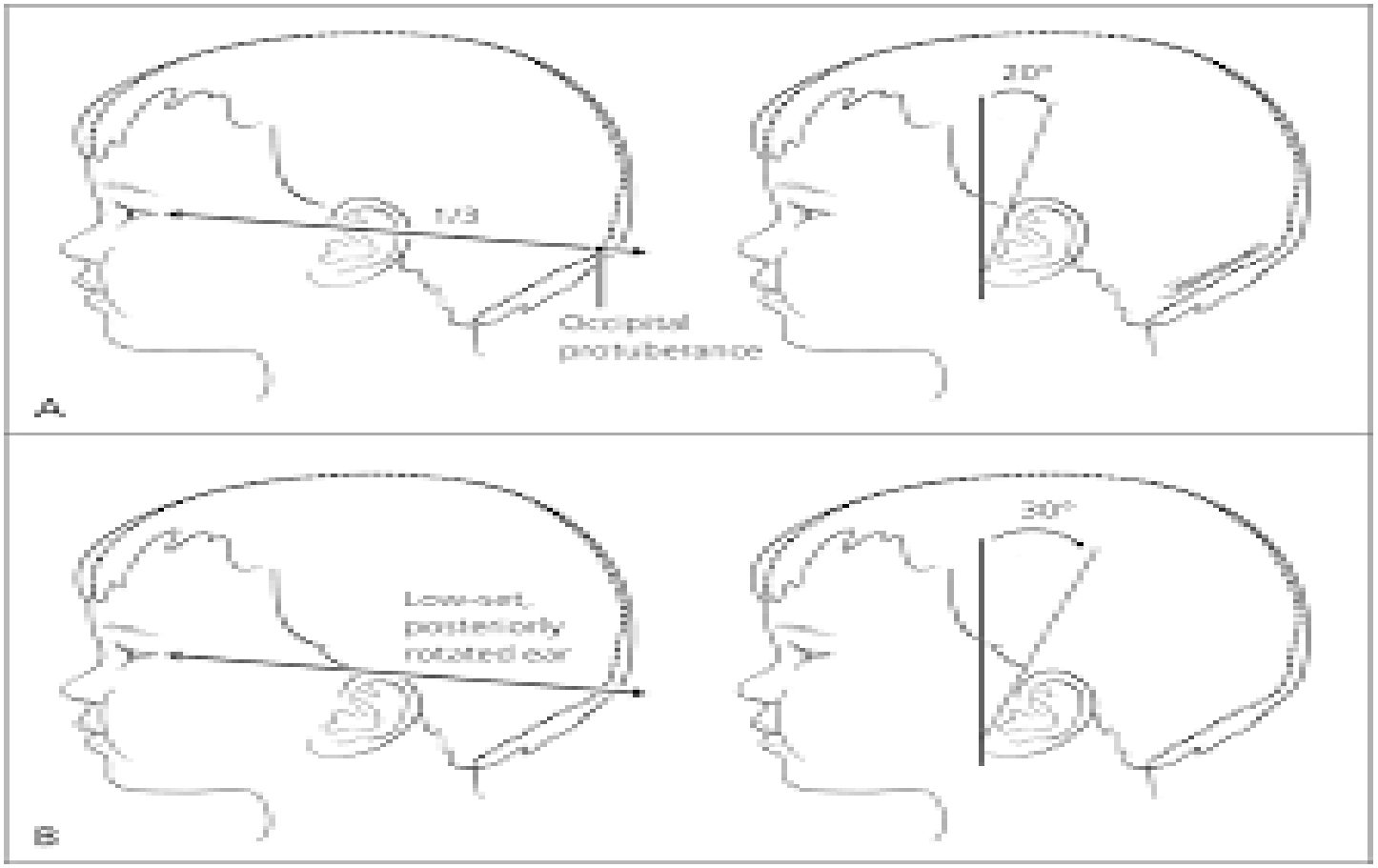
1/3
Occipital protuberance
30°
A
Low-set, posteriorly rotated ear
30°
B

- Abnormal:

Bluish color of earlobes(cyanosis) pallor

(cold weather)excessive redness (inflammation or fever)

Asymmetry

Low-set(associate with congenital abnormality as Downs syndrome

Palpate the auricles for texture' lasticity,
and tenderness'

- Gent pull he auricles up-down and back war '
- Fold the Pinna forward (it should recoil).
- apply pressure on the mastoid

Normal

Mobile, firm , and not tender pinna recoils after it is folded

Abnormal

Lesions , scaly skin ,tenderness (infection of external ear)

External Ear Canal :

Using anotoscop inspect the external ear canal for cerumen, skin lesion ,pus or blood

Normal: pink in color , dry , hairy , dry yellow or brow cerumen , free of discharge blood and lesion

Abnormal:

Redness , discharge excessive cerumen or lesion

Inspect tympanic membrane :

Color: gray , shinny ,semitransparent

Abnormal:

Pink or red ,blue bleeding , yellow infection with dull surface



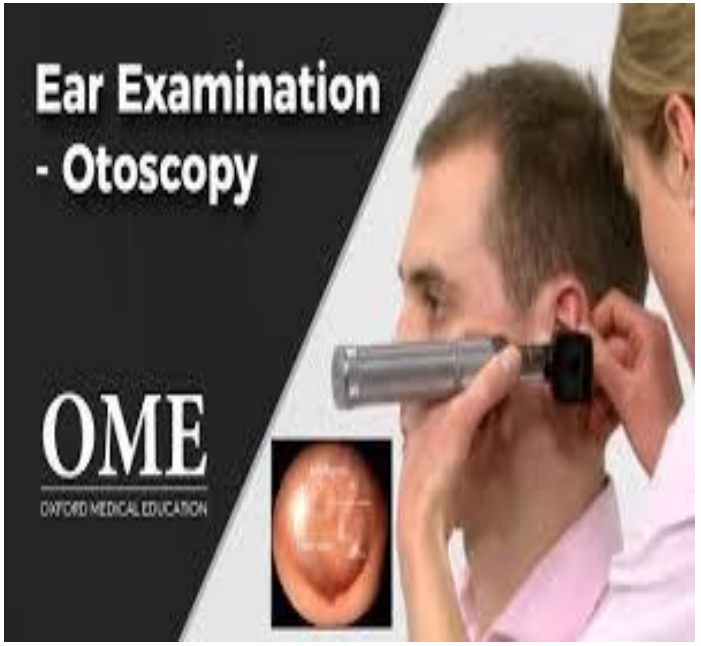
Ear Examination
- Otoscopy
OME
OXFORD MEDICAL EDUCATION





Tophi





Hearing acuity :

1- Assess client responses to normal voice : audible

Abnormal: request for repeat , lean, cups ear

2- Watch tick test : able to hear ticking in both ear

Abnormal: unable to hear

3- Tuning fork test :

Weber’s test

Rinne test

Hearing acuity – weber test



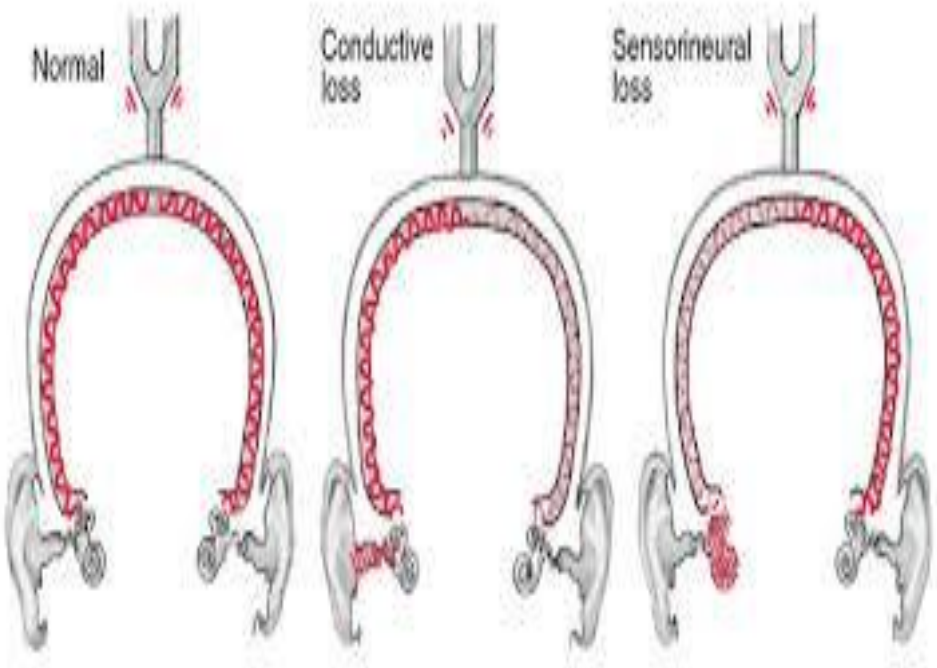

Rinne test


Rinne's Test
With a 512 Hz tuning fork press against the mastoid bone and then hold it 1cm away from the ear.
'Which is louder, behind the ear or in front?'
การทดสอบรินเน่ (rinne test)

Tympanic membrane

- Color/shape-pearly grey, shiny, translucent, with no bulging or retraction. a) Cone shaped light reflection of the otoscope light is seen at 5:00 in the right ear and at 7:00 in the left ear.





Mouth & Oropharynx

Equipment Needed

1. Penlight
2. Tongue blade
3. Small gauze (2*2)
4. Clean gloves

Preparation:

1. Position the client sitting up straight with his \her head at your eye level.
2. Remove client's dentures if available

Subjective data:

I. Sores & Lesions

2.Sore Throat

3. Bleeding gum.

4. Toothache

5. Hoarseness

6. Dysphagia

7. Altered taste

8. Smoking, Alcohol consumption

9. Self-care behaviors, dental care pattern, dentures or appliances

Inspect ion & palpation lips

Normal Findings

Color: in white skin Pink , in dark skin: may have bluish hue or freckle like pigmentation.

Movement: symmetrical during smile , open and close . No lesions, swelling, drooping , its moist and smooth

Wearing gloves, inspect & palpate lips for the following:

The patient's teeth should be clean with no decay, appear white and shiny smooth surfaces and edges. Adults should have a total of 32 teeth with 16 teeth in each arch. Children by the age of 2 1/2 have a total of 20 teeth with 10 in each arch.

Abnormal findings

Missing teeth, loose or broken teeth and misaligned teeth

.

Inspect protruded tongue for the following:

Symmetry & texture and color moist; papillae present; symmetrical appearance; midline fissure present , pink ,smooth

Inspect ventral surface of the tongue & mouth floor for the following:

Color: pink slightly pale

Landmarks: Submandibular duct openings are located on

both sides of the frenulum , tongue is free of lesions or increased redness; frenulum is centered.

Palpate inspected the site of tongue: pink , moist ,free of lesion and ulcer

Copyright © The McGraw-Hill Companies, Inc. Permission required for reproduction or display.

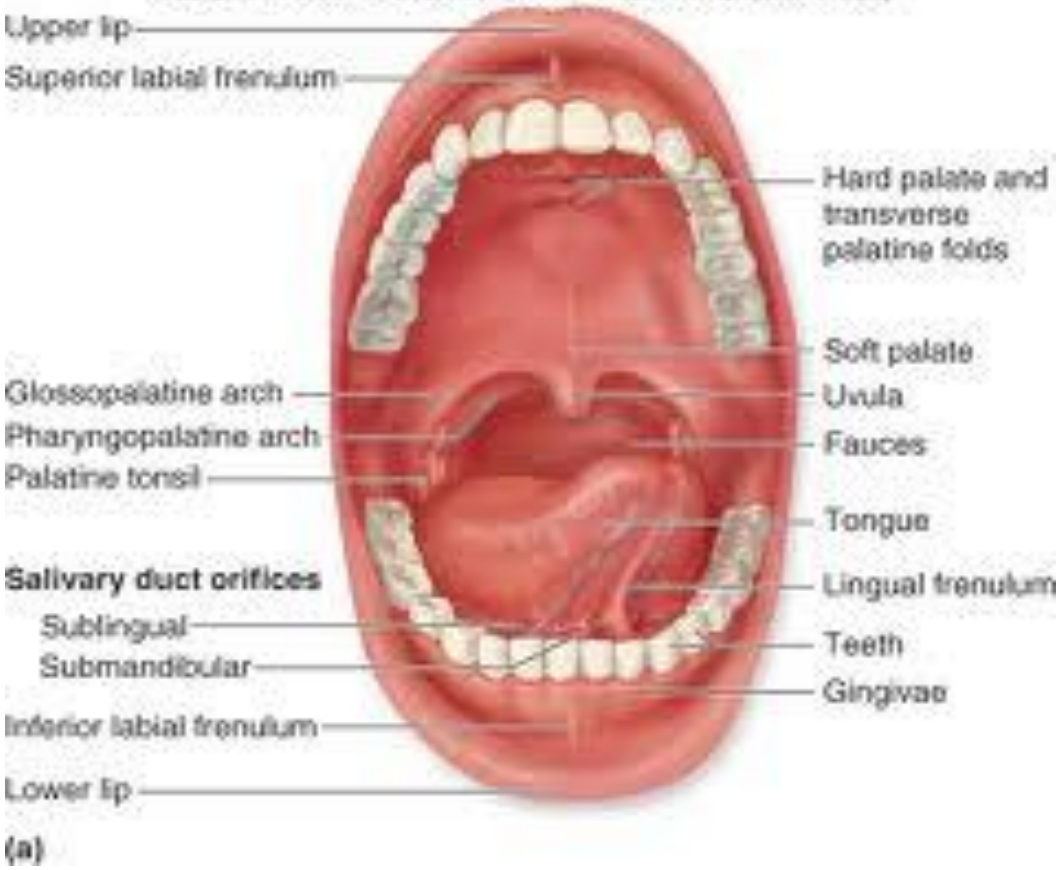

Inspect hard & soft palate for the following:

Color & consistency : hard palate is pale irregular while soft palate is pink and soft , spongy

Inspect oropharynx for the following:

Color : pink

Landmarks : Tonsillar pillars symmetrical;
tonsils present (unless urgically removed) &
without exudates; uvula at midline & rises on phonation.

Grading of Tonsils :

- 0 : tonsils not visible
- 1+ tonsils are visible, ✓
- 2 + tonsils are between the pillars and uvula ✓
- 3 + tonsils are touching the uvula ✓
- 4 + tonsils extend to the midline of the oropharynx. ✓

