Lung & Thorax Assessment

Dr. Sahar Adham

Lung Examination

Objectives:

At the end of this lab, the students will be able to:

1. Demonstrate the ability to safely & accurately complete thorax & lung assessment.

2. Demonstrate the ability to accurately document thorax & lung assessment data in organized

manner.

Equipment Needed

1. Stethoscope

2. Small ruler, marked in centimeters

3. Marking pen

4. Alcohol swab

Preparation

1. Ask the client to sit upright & the male to disrobe to the waist.
2. For female, leave the gown on & open at the back.
3. When examining the anterior chest, lift up the gown & drape it on her shoulders rather than

   removing it completely.
4. For farther comfort: a warm room, a warm diaphragm end piece.
5. Private examination time with no interruption.

Subjective data:

Cough ✓

Past history of respiratory infections ✓

Self-care behaviors ✓

Shortness of breath ✓

Smoking history ✓

Chest pain with breathing ✓

Environmental exposure ✓

Chest Landmarks

Anterior : Right anterior axillary line ,

Right midclavicular line ,

Mid sternum line

left midclavicular line ,

left anterior axillary line

Mid axillary line

Posterior: L . posterior axillary line , L .mid scapular line ,mid spinal line , R. mid scapular line and R. posterior axillary line ,

Inspect anterior, posterior, & lateral thorax for the following:

Color : Pink

Intercostals spaces : Even

Chest symmetry: Equal

Rib slope : Less than 90 degree downward

Respiration (rate, depth, rhythm) ,Even, 12-20/min, unlabored

Anterior-posterior to lateral diameter 1 : 2 ratio

Shape & position of sternum : level with ribs

Position of trachea Midline

Breathing Pattern

Eupnea: Normal breathing is relaxed, effortless, and regular at 14-16 breath\minute

Tachypnea: Rapid shallow breathing is a rate above 20 breaths per minute, associated with increased activity or a disease process

Bradypnea: slow breathing is a rate blow 12 breath per minute with normal depth and rhythm , associated with Sedation , anesthesia

Hypoventilation : Shallow irregular breathing hypercapnia and hypoxemia such as in COPD

Hyperventilation increased depth and rate of breathing (kussmaul 's respiration caused by diabetic ketoacidosis

Apnea is the absence of respirations.

- **Cheyne-Stokes** is the term for cycles of breathing characterized by deep, rapid breaths for about 30 seconds, followed by absence of respirations for 10 to 30 seconds. Cheyne-Stokes respirations constitute a serious symptom and precedes death in cerebral hemorrhage, uremia, or heart disease

Biot's respiration

rapid, short breathing with pauses of several seconds, indicating increased intracranial pressure.

Inspection

Normal chest

Slight retraction of intercostal spaces

2x as wide as deep

Anterior/posterior diameter

1:2



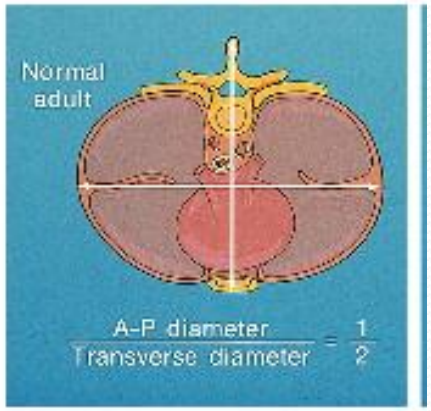

Inspection

Barrel chest

anterior-posterior diameter

2:2

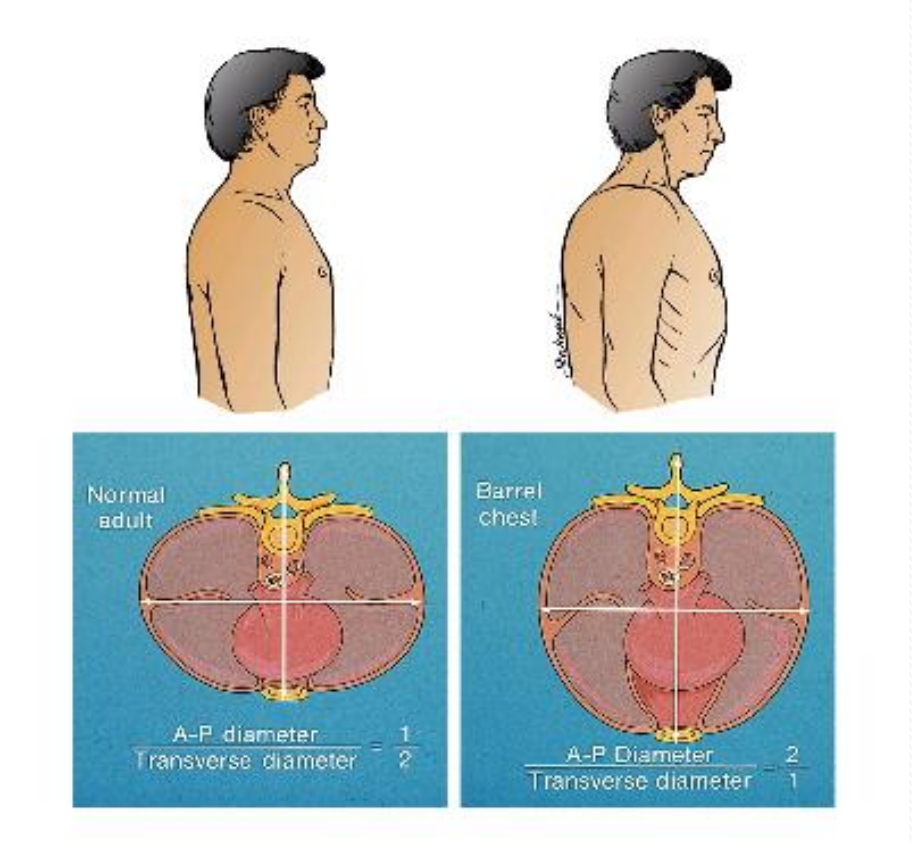

Inspection

Pigeon chest

Sternum protrudes outward

anterior-posterior diameter

↑

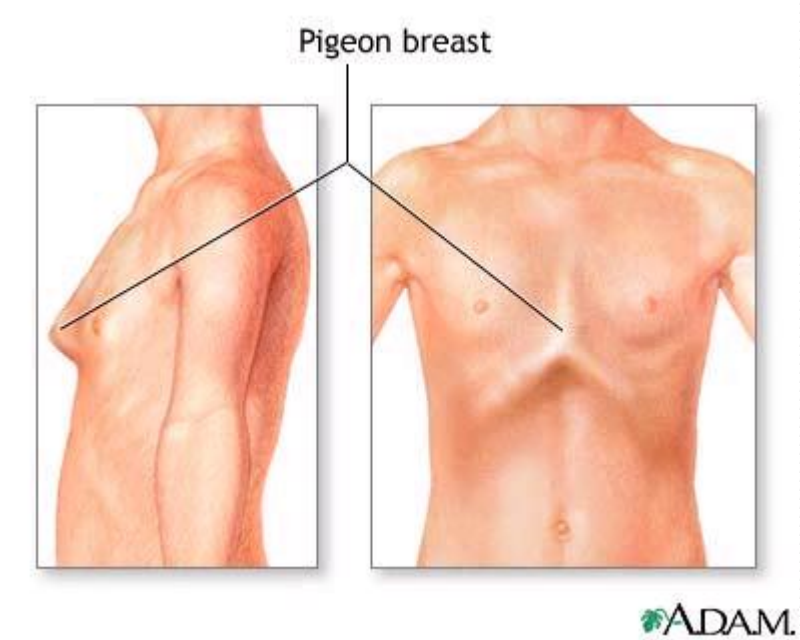

Pigeon and funnal Chest





Inspection

Scoliosis

Lateral curvature of thoracic spine

Assessment

Shoulders elevated?

Complications

Lung & heart damage

Back problems

Body image

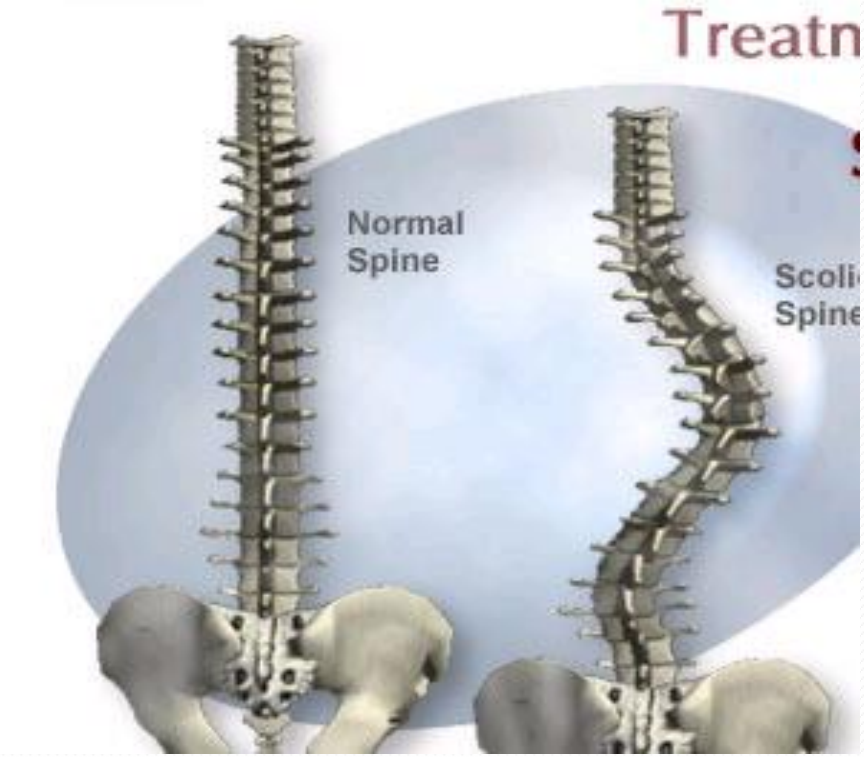

Scoliosis




Signs of scoliosis
Uneven shoulders
Curve in spine
Uneven hips
A.D.A.M.

Inspection

- Kyphosis
  - Abnormal curvature of the thoracic spine

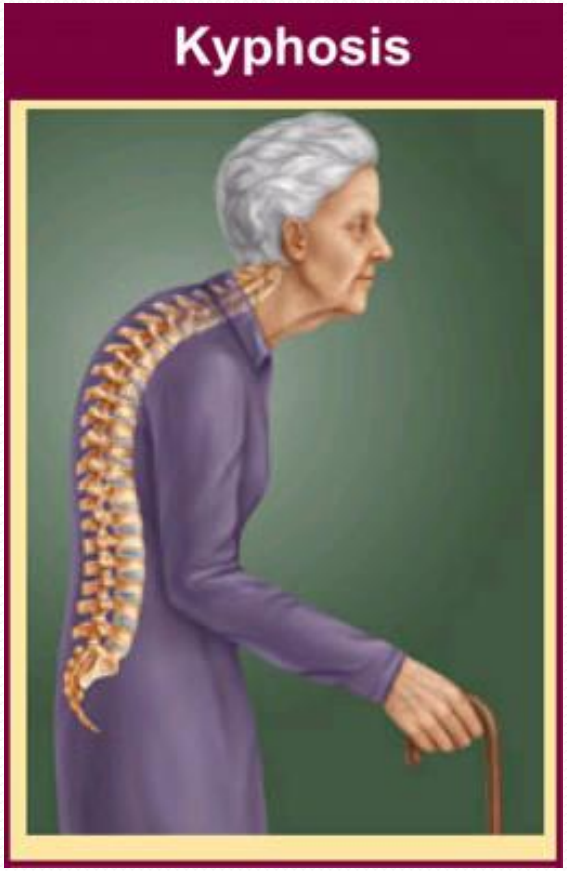

Kyphosis





Inspection

- Lordosis
  - Sway-back
  - Abnormal curvature of the lumbar spine

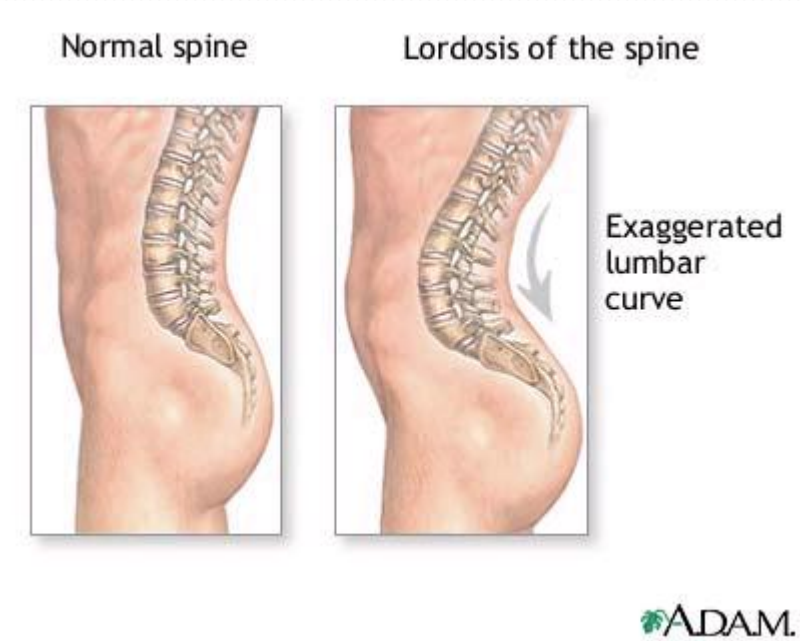

Lordosis

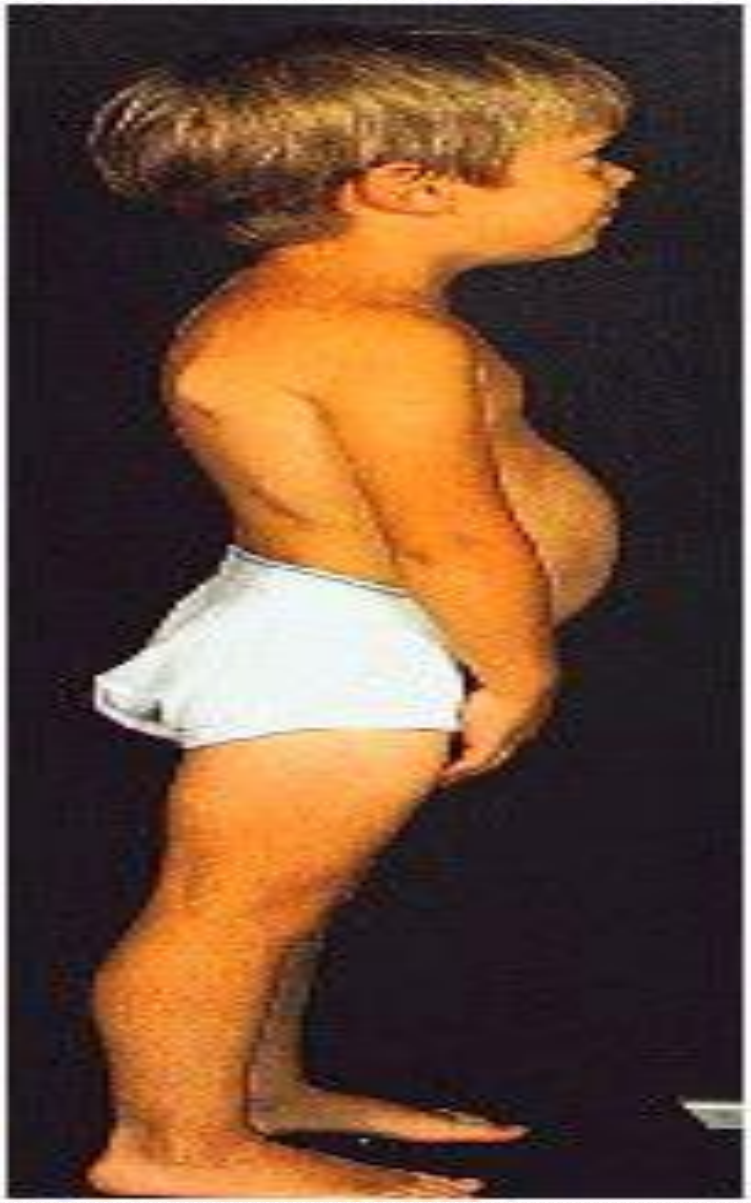

Inspection

- Uniform expansion of the chest
- Pneumonia
- Pleural effusion
- Pneumothorax
- Bulging intercostal spaces
- Obstruction
- Emphysema

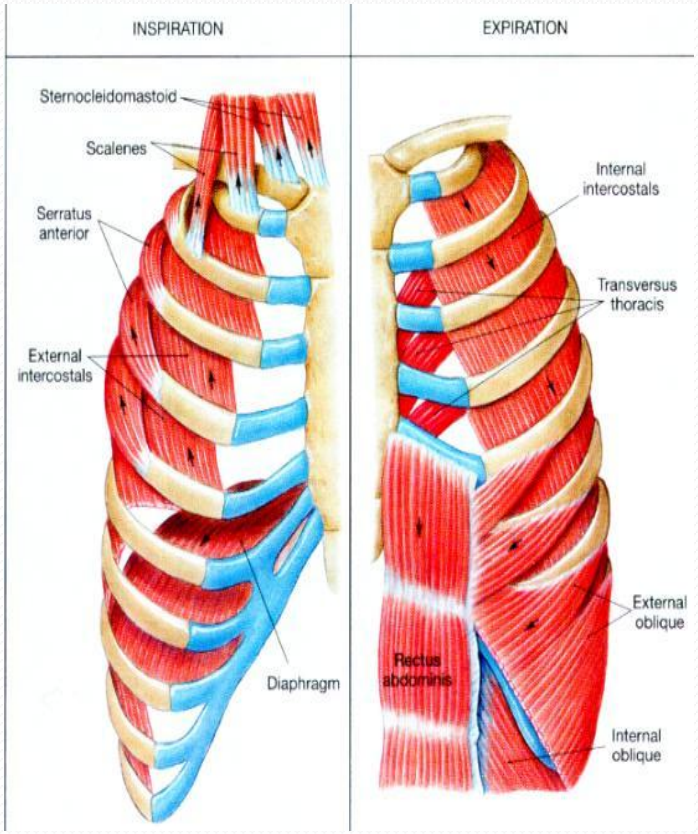

Palpate thorax at three levels for the following:

Sensation : no pain or tenderness

Vocal fremitus (tactius) as client says ***99Use either the palm base (the ball)*** of fingers, or the ulnar edge of one hand.

- Touch the client's chest- Ask the client to repeat a resonant phrases that generate strong vibration

Like ***99.***

Start over the lung apices & palpate from side to another.- Avoid palpating over the scapulae.

Vibration decreased over periphery of lungs & increased over major airways .

- Palpate chest expansion :

Posterior : placing your warmed hand on the poster lateral chest wall

- The thumbs should be at level of **T9** or **T10.**

- Slide your hands medially to pinch up a small fold between your thumbs.

- Ask the client to take deep breath.

- Your thumb should move with respiration.

Anterior: placing your warmed hand on the anterolateral wall.

- Thumbs should be along the costal margins & pointing toward the xiphoid process. - Ask the client to take deep breath.

- Watch your thumbs move with respiration.

2 to 3-inch symmetrical thoracic expansion.
Symmetrical expansion (thumbs move apart equal distance in both directions).





Percussion (Diaphragmatic Excursion)

Posteriorely :

ask the client to exhale & hold it.

- Percuss down the scapular line until the sound changes from resonant to dull each side.

- Mark the level where the sound changed to dull.

- Ask the client to take deep breath & hold it. - Continue percussion from the mark down ward.

Mark the level the sound changed to dull on deep - inspiration.

Normal Finding : -

It should be equal bilaterally, & measure about 3-5cm in adult, although it may be up to 7-8cm.

.

Auscultation

Purpose

Asses normal and abnormal air flow through bronchial tree by using

Diaphragm of stethoscope

Compare R to L





Auscultation: normal lung sound

Bronchial : Trachea , high , inspiration shorter than expiration

Bronchovesicular :

Moderate , Between scapulae

Side of sternum intercostals space , inspiration equal with expiration

Vesicular : Lung field , inspiration longer than expiration is it soft and low



Adventitious breath sound

Crackles (fine): high, short, popping sound heard during inspiration not clear with cough

Caused by: inhaled air sudden open of the small deflated air passage with sticky with exudates , can be associated with pneumonia , congestive heart failure or bronchitis and asthma

Coarse crackles :low pitch bubbling , moist sound that may persist from early inspiration to early expiration air comes into contact with secretions in the large bronchi and trachea may indicated pneumonia , pulmonary edema client with COPD

Wheeze(sibilant): high in pitch ,musical sound heard in expiration or may be inspiration ,air pass through constricted passage as secretion or tumor heard asthma or emphysema

Wheeze (sonorous): low pitch snoring or moaning sound heard during expiration clear with cough , heard in bronchitis , sleeping apnea .

Stridor: harsh honking wheeze heard with broncholaryngospasm as in croup

Pleural friction rub: low pitch grating sound superficial occur during I&E result of rubbing of two inflamed pleural surface as pleuritis

Best heard anterior, Lower, lateral area

